



ESE
2017
BRUSSELS
14 TO 16 SEPTEMBER



ROOTED IN
THE HEART
OF EUROPE

Oral Presentation
on freely chosen subject Abstracts

18th ESE Biennial Congress
Brussels, Belgium
14th-16th September 2017

Contents

Thursday 14 th Hall 5 Meeting Studio 211 & 212	3
14:30 to 16:00	3
16:30 to 18:00	9
Friday 15 th Hall 5 Meeting Studio 211 & 212	16
14:30 to 16:00	16
16:30 to 18:00	23
Saturday 16 th Hall 5 Meeting Studio 211 & 212	29
09:00 to 10:30	29
11:00 to 12:30	35
14:30 to 16:00	40
Thursday 14 th Hall 6 Meeting Studio 214 & 216	46
09:00 to 10:30	46
11:00 to 12:30	52
14:30 to 16:00	58
16:30 to 18:00	64
Friday 15 th Hall 6 Meeting Studio 214 & 216	70
09:00 to 10:30	70
11:00 to 12:30	76
14:30 to 16:00	82
16:30 to 18:00	88
Saturday 16 th Hall 6 Meeting Studio 214 & 216	94
09:00 to 10:30	94
11:00 to 12:30	100

Thursday 14th Hall 5 Meeting Studio 211 & 212

14:30 to 16:00

14:30

Successful emergency treatment of irreversible pulpitis with local anesthesia and single-day high dose oral corticosteroid, without a pulpotomy or pulpectomy: preliminary observations

*Yared G

Private Practice, Toronto, Canada

Aim The objective of this presentation is to introduce a time-saving and simple approach to the emergency treatment of irreversible pulpitis.

Summary In the presence of irreversible pulpitis, the main objective of an emergency treatment is to relieve the patient's pain. This requires making proper diagnosis and providing effective treatment. Determining the causative tooth can be challenging and time-consuming due to the patient's anxiety, the nature of the disease and the limitations of the diagnostic tests. Moreover, satisfactory pulpal anesthesia may not be obtained easily rendering the unscheduled appointment even longer, and disrupting treatment for patients with booked appointments. Finally, in this context of frustration and lack of time, a simple endodontic procedure may become a burden to the patient, the staff and the dentist. Effective pain relief can be achieved for an extended period of time following the administration of a local anesthetic and a single-day high dose oral dexamethasone (a corticosteroid), without a pulpotomy or pulpectomy. An appointment can then be made for a complete endodontic treatment in a more relaxed environment.

Key Learning Points

- Describe the mechanism of action of corticosteroids.
- List the contraindications to the use of corticosteroids.
- Describe the use of local anesthesia and a large single-day dose of dexamethasone, without a pulpotomy or pulpectomy, for an effective and lasting pain relief, and its limitations.

14:48

Minimizing postoperative pain by preventive administration of analgesic drugs

*Panopoulos P

Department of Endodontics, Dental School, National and Kapodistrian University of Athens, Athens, Greece

Aim To present the clinical evidence regarding the efficacy of the preventive use of analgesic drugs in reducing the postoperative endodontic pain. In addition, the indications of prophylactic use of anti-inflammatory drugs and their dosage will be discussed.

Summary Postoperative pain is a frequent complication during endodontic therapy. In many cases it is relatively easy to diagnose and treat; however, some times its alleviation is cumbersome and necessitates an emergency appointment. The etiology of pain is periapical inflammation which is caused, most probably, by the extrusion of debris through the apex during instrumentation.

When pain occurs it can be alleviated either by administration of analgesic drugs, or by emergency dental procedures, or by a combination of the above. Since prevention is preferable to treatment, the clinician should employ techniques that minimize the amount of extruded debris during canal instrumentation and, further, to use anti-inflammatory drugs with proven efficiency. During the last years convincing evidence is accumulated regarding the efficacy of the preventive use of analgesic drugs. It is possible that administration of a nonsteroidal anti-inflammatory drug before the endodontic treatment may interfere with the inflammatory process before it begins; therefore, presumably decreasing postoperative pain. Most studies tested the preventive use of analgesic drugs during extraction of third molars, and they reported a reduction of expected pain by 35-60%. Few studies have examined the efficacy of the preventive use of analgesic drugs in reducing the postoperative endodontic pain. Some of them did not find any significant difference in alleviating post-treatment pain. However, others have shown that administration of one tablet of a non steroid anti-inflammatory drug either before or immediately after the canal debridement resulted in significantly less pain compared to placebo.

Key Learning Points

- Understand the mechanism of post treatment endodontic pain
- Understand the effect of prophylactic administration of an anti-inflammatory drug on the inflammatory process
- Understand the indications and methods of the preventive use of analgesic medicaments during endodontic therapy

15:06

Post-operative quality of life following single-visit root canal treatment performed with WaveOne

Gold technique: a randomized clinical trial

*Multari S, Alovisi M, Pasqualini D, Carpegna G, Berutti E

Department of Surgical Sciences, Dental School, Endodontics, Turin, Italy, University of Turin, Turin, Italy

Aim The aim of the study was to evaluate the impact of reciprocating instrumentation performed with WaveOne Gold (WOG) on postoperative quality of life (POQoL) after single-visit primary root canal treatment, compared to WaveOne Classic (WOC).

Summary A randomized controlled clinical trial was carried out at the University of Turin – Dental School. Fifty-eight healthy subjects with asymptomatic or symptomatic irreversible pulpitis and pulp necrosis, with or without apical periodontitis, were enrolled and a single-visit primary root canal treatment was carried out. Glide path was performed with ProGlider and canal shaping respectively with WaveOne Gold Primary or WaveOne Classic Primary up to working length in the two different groups. Irrigation was conducted with 5% NaOCl and 10% EDTA and root canal filling with thermafil technique and ZOE sealer. POQoL indicators were evaluated for 7 days post-treatment with an ad hoc questionnaire. The questionnaire evaluated difficulty in chewing, speaking, sleeping, carrying out daily functions, social relations, medium and maximum pain and quality of life with a Likert-like scale ranging from 0 (none) to 10 (very much). As secondary outcomes, days to complete pain

resolution after treatment and mean analgesic intake were evaluated. The variation of each indicator over time was analysed with ANOVA ($p < 0.05$) and the impact of each variable on POQoL was analysed with a multivariate logistic regression model ($p < 0.05$). Post-operative pain curves demonstrated a more favourable time-trend in the WOG group. Difficulty in eating, performing daily activities, sleeping, in social relations were less evident in WOG group, although the differences were not statistically significant. Patients' perception of the impact of treatment on POQoL was more favourable in WOG group.

Key Learning Points

- Reciprocating instrumentation may be associated with postoperative pain
- Instrumentation with WaveOne Gold showed lower impact on POQoL compared to WO classic
- Patient oriented outcomes seem to benefit from the WOG design
- Importance of patients' point of view

15:24

Postoperative pain intensity using different Ni-Ti instrumentation systems in single visit non-surgical Endodontic retreatment: A randomized clinical trial

*Eyuboglu T^{F1}, Ozcan M²

¹Department of Endodontics, Istanbul Medipol University, Istanbul Turkey, ²Clinic for Fixed and Removable Prosthodontics and Dental Materials Science, University of Zurich, Zurich, Switzerland

Aim One of the most frequent complications associated with non-surgical endodontic retreatment is pain that could be a result of instrumentation technique. The aim of this study was to compare the effect of different Ni-Ti instrumentation systems on postoperative pain after single visit non-surgical endodontic retreatment.

Summary A total of 99 patients with asymptomatic root canal treated teeth in need of non-surgical endodontic retreatment were randomly treated using three systems (n=33 per group). Previous root canal fillings were removed with hand files and GG #1 and #2 burs in each group. One Shape, Revo-S

and WaveOne were used in Groups 1, 2 and 3 respectively for instrumentation. All retreatments were carried out in single visit prior to permanent coronal restorations. The presence of postoperative pain was assessed at 6, 12, 18, 24, 48 and 72 hours, 7 days and 1 month after the treatment. Data were analyzed using 1-way ANOVA, Mann-Whitney U and Kruskal Wallis Test ($\alpha=0.01$).

Up to 72 h follow-up, postoperative pain was significantly less in Group 1 than those of Groups 2 and 3 ($p<0.01$). From 72 h to 7 day follow up, Group 1 and 2 presented significantly less postoperative pain than that of Group 3 ($p<0.01$), whilst there was no significant difference between Group 1 and 2 ($p>0.05$). At 1-month follow-up, there was no significant difference between all groups ($p>0.05$).

Key Learning Points

- One Shape and Revo-S systems have similar apical shaping features and are based on rotational instrumentation approach whereas WaveOne is based on reciprocal approach. Although One Shape and WaveOne are both single file instrumentation systems, the incidence of postoperative pain values was the highest in the latter.

15:42

Evaluation of Postoperative Pain in Single Visit Root Canal Treatment Using Three Different Instrumentation Techniques: a Randomised Clinical Trial

Karsli S, Oztan MD, *Yilmaz F

Department of Endodontics, Ankara University Faculty of Dentistry, Ankara, Turkey

Aim The aim of this study was to evaluate post operative pain after single visit root canal treatment by using three different instrumentation techniques.

Summary Postoperative pain associated with root canal procedure can be defined as pain of any degree that occurs after the initiation or completion of root canal treatment. Prevention and management of postoperative pain is an important part of endodontic treatment. Sixty permanent maxillary premolar teeth with vital pulps requiring endodontic treatment were included in this

study. The teeth in group 1(n:20) were instrumented with Protaper Universal by continuous rotation. The teeth in group 2(n:20) were instrumented with OneShape by continuous rotation. The teeth in group 3(n:20) were instrumented with WaveOne Primary by reciprocation movement. After chemomechanical preparation, the root canals were obturated at the same visit. The patients were given Postoperative pain evaluation forms and were instructed to mark the pain level experienced for seven days after obturation. Kruskal Wallis test was used for statistical analysis. The differences in pain levels were considered statistically significant at $p < 0.05$. Statistical analysis revealed significant differences among the groups. These differences were observed in postoperative pain levels experienced between the Protaper Universal and WaveOne groups immediately after the wearing off of the local anesthesia and at 12 hours. WaveOne group exhibited significantly more postoperative pain than the Protaper Universal group. On day 1, 2 and 3, WaveOne group had significantly more postoperative pain than the other two groups. No significant differences were observed among all the groups on day 4, 5, 6, and 7. Continuous rotation technique resulted in significantly less postoperative pain than the reciprocation technique. It can be suggested that, early preflaring during root canal instrumentation may play a role in reduced postoperative pain. Continuous rotation technique resulted in significantly less postoperative pain than the reciprocation technique. It can be suggested that, early preflaring during root canal instrumentation may play a role in reduced postoperative pain.

Key Learning Points

- Postoperative pain levels differs by root canal preparation technique used.
- Reciprocation motion causes more postoperative pain than rotational motion.

16:30 to 18:00

16:30

A rare case of mucormycosis mimicking periapical pathology.

*Dechouniotis G, Georgopoulou M

Department of Endodontology, Dental School of Athens, Athens, Greece

Aim To present a case where the initial clinical and radiographic findings resembled an acute apical periodontitis but was a premature development of a rare and life-threatening systemic mycosis.

Summary The most common acute pathological conditions that face dentists in daily clinical practice concern inflammation of the pulp, the periapical and periodontal tissues. Pulp vitality tests, clinical and radiographic examination enable the dentist to differentiate between inflammation of endodontic or periodontal origin and give appropriate treatment. Occasionally there are acute pathological conditions which are not of dental aetiology for example, infections of the sinus, temporomandibular joint disorder, osteomyelitis. Pathological conditions, in bone, adjacent to teeth, can cause symptoms such as pain and swelling. Additionally bone lesions imitate the radiographic picture of periapical lesions presented as radiolucent areas associated with root apices, though, without endodontic or dental aetiology. Some common cases are cysts and tumors of the jaw, and metastatic tumors. A very rare case of this is mucormycosis - an opportunistic life-threatening infection that is caused by Mucorales fungi of the Zycomycetes class. Its frequency is 10 to 50 times less than that of aspergillosis or candidiasis. Mucormycosis can be classified on the basis of six clinical forms - the rhino-orbital-cerebral form being of interest to dentists in the early diagnosis. The majority of patients suffering from mucormycosis have predisposing conditions which negatively affect the immune system e.g. diabetes mellitus or hematological malignancies and mortality rate is high. Dentists must be aware of the clinical and radiographic features of these diseases, in order to differentiate them from periapical lesions of endodontic origin and treat appropriately.

Key Learning Points • be aware that periapical lesions are not always of endodontic origin despite similar clinical symptoms and radiographic signs

- mucormycosis is associated with clinical and radiographic signs mimicking periapical lesions of endodontic origin

16:48

Invasive Cervical Root Resorption (ICRR): a multidisciplinary treatment approach to an obstacle in Orthodontic procedure or a late complication of the orthodontic treatment

*Steinbock N¹, Aizenbud D²

Department of ¹Endodontics and Dental Trauma, ²Orthodontic and Craniofacial Anomalies, School of Graduate Dentistry, Rambam Health Care Campus, Haifa, Israel

Aim The aim of this study is to present multidisciplinary treatment approach in the diagnosis and management of teeth with ICRR, involving endodontic, surgical and orthodontic treatment.

The Interactions between ICRR lesions and the orthodontic treatment will be described in two different aspects: 1. In many cases of failure in impacted tooth movement, ICRR diagnosis must be taken under consideration. An "ankyrotic teeth " that interfere with the orthodontic treatment course. 2. Appearance of ICRR years after orthodontic treatment.

Summary ICRR is a clinical term used to describe a relatively uncommon, insidious and often aggressive form of external tooth resorption. Characterized by its cervical location and invasive nature, this resorptive process can lead to a significant loss of tooth structure and to interfere with the orthodontic treatment course. A treatment strategy that might improve the healing outcome for patients with ICRR class 4 (Heithersay) will be presented. The multidisciplinary approach included endodontic treatment under surgical microscope using MTA (mineral Trioxide Aggregate), surgical application of TCA (trichloro-acetic acid), tissue regeneration using growth factors, bone substitute and guided tissue regeneration (GTR) in an attempt to reconstruct cervical periodontal attachment and continuation of orthodontic treatment course. A CBCT is essential diagnosis tool for the assessment of replacement resorption leading to ICRR. All cases were diagnosed and analyzed using CBCT. A follow-up demonstrated no pathologic changes upon clinical and radiographic examination.

Key Learning Points

- Treatment of ICRR presents a challenge to the clinician and the prognosis depends mainly on the extent of the resorptive process.
- Early diagnosis of the ICRR is critical for proper treatment and a favorable prognosis.
- The extent of resorption serves as a guide for the clinician in selecting the correct treatment.
- The presented multidisciplinary treatment approach is offered to the prudent clinician as a solution in ICRR cases of a severe destructive nature
- CBCT can accurately demonstrate the size and the stage of the invasive lesion
- Proper clinical and radiographic examination, correct diagnosis and treatment multidisciplinary planning, are key features for successful treatment.

17:06

Guided tissue regeneration in Endo-Perio lesions – Management of molar furcation defect

*Ali S, Zoya A, Gautam G

Department of Conservative Dentistry & Endodontics, Aligarh Muslim University, Aligarh, india

Aim The aim of this clinical case is to report the repair of longstanding perforation defect with MTA and surgical approach for the management of endo-perio lesion using bone graft and guided tissue regeneration (GTR).

Summary A perforation is the communication between the root canal system and the external root surface and may be the consequence of iatrogenic error or a pathologic process such as caries and root resorption. Perforation size, location, and time delay before its repair are the main factors which affect the prognosis. Mineral trioxide aggregate (MTA) is extensively used to seal perforations because of its excellent biocompatibility, sealability and cementogenic ability. Hydroxyapatite bone graft aids in bone and periodontal regeneration in longstanding furcation defects along with guided tissue regeneration (GTR) membrane. This case report describes the repair of large furcal perforation in the mesial root of mandibular first molar with MTA and surgical management of grade II furcation

bone loss by means of hydroxyapatite bone graft and GTR membrane. The 24-month recall showed favourable results with significant bone regeneration at the furcation and the probing depth was reduced to 3 mm. The absence of pain and swelling with functional tooth stability adds to the clinical success of this case.

Key Learning Points

- Longstanding furcal perforations with periodontal inflammation can be successfully treated with MTA and guided bone and periodontal regeneration procedures.
- Infection control within the root canal and at the perforation site is required for satisfactory perforation repair and healing.
- GTR membrane is imperative for the successful management of such endo perio lesions.

17:24

Is there a relationship between endodontics and early dental implant failure? A retrospective study

*Sisli SN

Department of Endodontics, Baskent University Faculty of Dentistry, Ankara, Turkey

Aim The aim of this study was to investigate the potential endodontic risk factors in the etiology of early implant failure. These risk factors were mainly classified as pre-existing infection originating from the implant site and adjacent teeth.

Summary Patients who underwent BEGO (BEGO Implant Systems GmbH & Co. KG, Bremen, Germany) implantation in 2014 and 2015, and followed up for at least 1 year in Dental Polyclinic of Adana Baskent University Healthcare Center were included in this retrospective study. Subjects with history of diabetes mellitus, smoking habit, total edentulous jaws, autogenous bone augmentation procedures and lack of follow-up information were excluded. As a result, 447 implants of 178 patients were included. Subjects were scored according to the presence (1) or absence (0) of following predictors: Implants with failure, implants with adjacent endodontically treated teeth,

implants with adjacent non-endodontically treated teeth, implants with no adjacent teeth, implants with adjacent teeth with periapical lesion, extraction of teeth with periapical lesion before implantation, extraction of endodontically treated teeth before implantation. The history of the healing time of the extraction and/or root canal treatment were also recorded. The duration from endodontic treatment of adjacent teeth to implant placement was categorized as; no more than 4 weeks before implantation, 4-12 weeks before implantation, at least 12 weeks before implantation, no more than 4 weeks after implantation and at least 4 weeks after implantation. The categorical variables between the groups was analyzed by using the Chi-square test or Fisher Exc. Test at $P < .05$. Except for the duration between implant and endodontic treatment of adjacent teeth ($P < .001$), no significant difference was found between early implant failure and endodontic predictors ($P > .05$).

Key Learning Points

- The incidence of early implant failure was not influenced by prior or existing endodontically treated teeth.
- Under the limitation of this retrospective study, endodontic treatment of adjacent teeth within the first 4 weeks after the placement of implant was found to be a high potential cause of early implant failure.
- Duration between implant and endodontic treatment of adjacent teeth should be planned carefully to avoid early implant failure.

17:42

Anti-Inflammatory and Antiresorptive Functions of Melatonin on Experimentally Induced Periapical Lesions

Sarıtekin E¹, *Ureyen Kaya B¹, Asci H², Özmen O³, Kececi AD¹

¹Department of Endodontics, Süleyman Demirel University, Faculty of Dentistry, Isparta, ²Department of Pharmacology, Süleyman Demirel University, Faculty of Medicine, Isparta, ³Department of Pathology, Mehmet Akif Ersoy University, Faculty of Veterinary Medicine, Burdur, Turkey

Aim To investigate the effects of systemically administered melatonin on inflammation and alveolar bone resorption in rats subjected to experimental periapical lesions.

Summary Methodology Thirty adult Sprague-Dawley rats were divided equally into negative, positive control and melatonin groups. The pulp chambers of their mandibular first molars were exposed to the oral environment to induce experimental periapical lesions in positive control and melatonin groups. The melatonin group received daily intraperitoneal injections of melatonin at a dose of 10 mg/kg, whereas the control groups received only the 10% ethanol vehicle. After 21 days, the animals were euthanized, and the mandibles were subjected to histotechnical processing. Hematoxylin-eosin-stained sections were examined under conventional light microscopy for the description of periapical inflammation and under fluorescence microscopy for the determination of the periapical lesion size. The subsequent sections were evaluated by Brown and Brenn staining (bacteria), and immunohistochemistry (IL-1 β , RANK, RANKL, OPG and tartrate resistant acid phosphatase). Data were analysed by Kruskal–Wallis (for nonparametric data) and one way ANOVA tests (for parametric data) ($P < .05$). Results The histopathological scores of melatonin group were significantly lower than those of positive control group ($p < 0.01$). Histomorphometrically, the periapical bone loss area in melatonin group was significantly smaller than positive control group ($p < 0.01$). A score of bacteria localization by Brown&Brenn staining in positive control group was higher than the other groups ($p < 0.01$). The synthesis of IL1- β , RANK, RANKL was higher in the positive control group, whereas OPG was higher in melatonin group ($p < 0.01$). Number of osteoclasts were found significantly higher in positive control group by TRAP staining analyses ($p < 0.01$). Conclusions Melatonin demonstrated anti-inflammatory and antiresorptive functions on experimentally induced periapical lesions in rats. Further studies are necessary to evaluate its possible effects on the healing of periapical lesions.

Key Learning Points

- Systemically administered melatonin down-regulates the inflammation and alveolar bone resorption markers in rats subjected to experimental periapical lesions.

- This study support the anti-inflammatory and antiresorptive functions of melatonin, suggesting its potential usefulness as a novel agent for periapical lesions

Friday 15th Hall 5 Meeting Studio 211 & 212

14:30 to 16:00

14:30

A Simple Method for Isolation and Proliferation of Dental Pulp Stem Cells derived from Human Molar Teeth

*Turk T¹, Ozisik B¹, Nalbantsoy A³

¹Department of Endodontology, Faculty of Dentistry, ²Department of Biotechnology, Ege University, Izmir, Turkey

Aim The aim of this study was to describe the simple in vitro isolation of dental pulp stem cells from human molar teeth and observe their proliferation in vitro

Summary Non-cariou human third molars were collected from adults. After extraction, teeth surfaces were cleaned and the crown was separated from the cervical region with sterilized diamond burs under water-cooling under sterile conditions. The pulp tissue was gently separated by forceps and digested in a solution of 3 mg/ml collagenase type I (Sigma, St. Louis, MO) for 60 min at 37°C. Cell suspensions were obtained by passing the digested tissues through a 70-µm cell strainer. Single cell suspensions were seeded in 100 mm culture dishes with control medium (CM) containing; α-Minimum Essential Medium (α-MEM; Life Technologies/GIBCO BRL, Gaithersburg, MD) supplemented with 15% fetal bovine serum (FBS), 2 mM L-glutamine, 100 units/ml penicillin-G, 100 mg/ml streptomycin, and 0.25 mg/ml fungizone (Gemini Bio-Products, Inc., Woodland, CA) and maintained in 5% CO₂ at 37 °C. Cells were cultivated in twenty four-well plates (Greiner Bioone, The Netherlands) and the medium was changed every other day. Cells were microscopically observed under inverted microscope (Olympus, Tokyo, Japan) with a phase-contrast attachment. Cells showed good proliferation and attachment to culture flasks. Majority of the cells displayed fibroblast-like morphology at 7th day of culture. Cells showed good proliferation rate, and particularly after 14 days of culture period. After 21 days, these primary cells reached 95% confluence and showed epithelioid and polygonal shape and formed colonies.

Key Learning Points

- Stem cells derived from human dental pulp tissue demonstrated high vitality and capability to quickly restart proliferation.
- Stem cells were capable of retaining their differentiation potential after long- term storage.

14:28

Formation of odontoblast-like cells from cultured human dental pulp stem cells on dentine in vitro

*Ozisk B, Turk T, Nalbantsoy A

Department of Bioengineering, Faculty of Bioengineering, Izmir, Turkey

Aim To evaluation of human dental pulp stem cells on scanning electron microscope.

Summary Dental pulps were obtained from sound human third molars extracted for therapeutic reasons. All donors were healthy without any known disease, were not taking any medications. The tooth surfaces were cleaned and cut around the cemento-enamel junction using sterilized diamond stones. Carefully extracted pulp tissue was minced into small pieces. The tissue blocks were cultured in alpha modification of Eagle medium (Gibco-BRL, Grand Island, NY) supplemented with 20% fetal bovine serum and a complex of 100 U/mL penicillin G and 100 mg/mL streptomycin. Cell cultures on the third passages were used. DPSCs characterized by flow cytometric analysis of CD90, CD105, CD73, CD44, CD19, CD45 and CD34. The cultured cells differentiated into osteocytes, adipocytes, and chondrocytes (R&D Systems, Human Mesenchymal Stem Cell Functional Identification Kit Catalog Number SC006). To induce odontogenic differentiation, DPSCs were seeded into 6-well plates at a density of 1×10^5 /well. Odontogenic differentiation was performed for 14 days by using odontogenic induction medium (OM) containing α -modified Eagle medium, 15% FBS, 10 mmol/L β -glycerophosphate (Sigma-Aldrich), 0.2 mmol/L ascorbate- 2-phosphated (Sigma-Aldrich) and 100 nmol/L dexamethasone (Sigma-Aldrich). Controls ("uninduced") were grown in α -MEM with 15% FBS. The media were changed every 3 days. For dentin discs non-carious human third molars were collected from healthy patients. After separation of the crowns at cemento-enamel junction with

slow speed diamond saw (Isomet, Buhler, IL, USA) enamel was completely removed until dentin was exposed. Then, dentin discs (5mm in diameter and 2 mm in thickness) were obtained from the mid-coronal portion of dentin blocks. After packing of discs, they were sterilized by ethylene dioxide. Each dentin disc was seeded with DPSC and suspended in their own medium. Finally, samples were coated with a thin layer of gold by ion sputtering. Samples were then examined using a scanning electron microscope (JEOL JSM-5200, Tokyo, Japan) at various magnifications.

Key Learning Points

- The nature of dentin surface itself presented good adhesive characteristics for stem cells. Because root canal dentin is a target tissue of regenerative endodontic therapy, developing approaches to increase the adhesion and proliferation capacity of stem cells into the dentin lead to better clinical interventions.

15:06

Mineralization capacity of human dental pulp stem cells is impaired via the TLR signaling pathway after long-term exposure to biofilm extracellular products

*Petridis X1, Harmsen MC2, Brinker MGM², Dijkstra RJB¹, van der Mei HC³, van der Sluis LWM¹

Departments of ¹Dentistry and Oral Hygiene, ²Pathology and Medical Biology, ³Biomedical Engineering, University Medical Center Groningen, Groningen, Netherlands

Aim The aim of this study was to assess the effect of biofilm-derived conditioned media on the mineralization potential of human dental pulp stem cells (hDPSCs). The working hypothesis was that the biofilm extracellular products adversely affect the in vitro induced mineralization of hDPSCs via Toll-like receptor (TLR) signalling pathways.

Summary Continued deposition of mineralized tissue is one of the main goals in regenerative endodontic procedures. This can be achieved by exploiting the differentiation potential of the DPSCs, whereby new mineralized structures can be laid down. However, DPSCs are introduced within a frequently non-ideally disinfected environment harboring residual bacterial aggregates.

Thus, the chance of encounter between bacterial biofilms and DPSCs is highly likely and whether biofilms affect their ability to mineralize is currently unknown. Primary hDPSCs cultures were developed from pulp tissue obtained from extracted immature impacted third molars. Standardized dual-species biofilms (*Streptococcus oralis* J22 and *Actinomyces naeslundii* T14V-J1) were grown on hydroxyapatite disks in the constant depth film fermenter. Biofilm conditioned media were prepared after overnight growth of the biofilms in culture media and used for challenging the hDPSCs for 7 and 14 days. Planktonic conditioned media from the same bacterial species served as control groups. Cell viability and proliferation of hDPSCs was assessed after 7 days with an MTT assay and Ki-67 immunocytochemical staining respectively. Mineralization potential was qualitatively screened Alizarin Red S staining (AR-S) after 14 days, quantified after staining extraction and confirmed by determining the expression of mineralizing genes was through reverse-transcription quantitative polymerase chain reaction. TLR-pathway blockade assays were performed with TLR 2/4 and TAK-1 inhibitors for 14 days and mineralization evaluated through AR-S. Viability, proliferation capacity, mineralization and associated gene expression of the hDPSCs were significantly reduced after their long-term exposure to biofilm extracellular products. Their mineralization potential was almost completely restored after blocking the TLR signaling pathway.

Key Learning Points

- Exposure of hDPSCs to biofilm extracellular products results in deterioration of their in vitro induced mineralization capacity.
- Upstream (TLR 2/4 inhibitor) or downstream (TAK-1 inhibitor) blocking of the TLR signaling cascades restores mineralization.
- Development of appropriate stem cell pre-treatment protocols and/ or biofilm eradication strategies are needed.

15:24

Development of spheroids by dental pulp-derived cells under the influence of hypoxia and prolyl hydroxylase inhibitors

Janjić K, Lilaj B, Moritz A, *Agis H

Department of Conservative Dentistry and Periodontology, School of Dentistry, Medical University of Vienna, Vienna, Austria

Aim To reveal the effect of hypoxia and pharmacological simulated hypoxia via prolyl hydroxylase (PHD) inhibitors on the development and activity of spheroids by dental pulp-derived cells (DPC).

Summary Methodology: DPC were treated with hypoxia and the PHD inhibitors dimethyloxallyl glycine (DMOG), desferrioxamine (DFO) and L-mimosine (L-MIM) on agarose. Spheroid development was observed and images were taken directly, 6h and 24h after seeding. Size of the spheroids was measured by image processing. Cell viability was evaluated by Live-Dead staining, MTT staining and via a resazurin-based toxicity assay. Furthermore VEGF, IL-8, and SDF-1 production was measured by the respective enzyme-linked immunosorbent assays (ELISA). Results: Spheroids developed also when DPC were treated hypoxia, PHD inhibitors, and their combination. We observed no prominent change in the size of DPC spheroids by hypoxia, DMOG, DFO, L-MIM and the combination compared to the normoxic controls ($p > 0.05$). Cells remained vital in Live-Dead and MTT staining and the resazurin-based toxicity assay. At the protein level increases in VEGF and IL-8, but no SDF-1 were observed. The combination of hypoxia and PHD inhibitors did not further boost VEGF and IL-8 production significantly. Conclusions: Overall our results show that hypoxia and PHD inhibitor pre-conditioning can enhance the pro-angiogenic capacity of DPC spheroids while not inhibiting their development.

Key Learning Points

- DPC form spheroids under hypoxic conditions and in the presence of PHD inhibitors
- Hypoxia and PHD inhibitor pre-conditioning can enhance the pro-angiogenic capacity of DPC
- The combination of hypoxia and PHD inhibitors does not further boost their pro-angiogenic effects

- PHD inhibitors and hypoxia pre-conditioning represent a promising novel set of tools for regenerative endodontics

15:42

Does the apical papilla survive and develop after regenerative procedures in immature teeth with pulp necrosis?

Palma PJ¹, Martins JB¹, Ramos JC¹, Sequeira D¹, Diogo P¹, Diogenes C², *Santos JM¹

¹*Dentistry Department, Faculty of Medicine, Coimbra University, Coimbra, Portugal*, ²*Department of Endodontics, University of Texas Health Science Center at San Antonio, San Antonio, Texas, United States*

Aim Evaluate the survival and possible development of apical papilla after induced pulp necrosis and apical periodontitis in teeth treated by regenerative endodontic procedures and apexification - an histological and clinical overview.

Summary Apical papilla which survived the endodontic infection interacts with the HERS allowing differentiation to take place once the infection is solved. Importantly, complete detachment of this tissue can be seen after REPs. This suggests that mechanical forces applied to evoke bleeding are capable of dislodging the apical papilla from its continuum with the canal space. Their partially or totally separation may be due to the fact that apical papilla and HERS are loosely attached to the apex so they can be easily detached by infection, mechanical trauma, iatrogenic factors or also as a result of the treatment protocol. Interestingly, there is clinical evidence of root tip formation separately from the main root. This occurs after homing strategies and represent an important future clinical approach. It is expected that mechanical disruption of the apical tissues or even the pressure of the periapical infection is the main reason for their detachment. We would like to highlight the fact that even in the presence of large periapical lesions, in a in vivo study in beagle dogs, histological and radiographic evaluation revealed that this tissue is resilient and survives adverse conditions following REPs. Moreover, clinical and radiographic assessments of immature

teeth with apical periodontitis treated with apexification or REPs in humans, reveal further development and generation of a root-tip like structure, which supports the data from our animal study.

Key Learning Points

- SCAP and HERS cells may remain vital and in continuity or close to the main root following infection.
- The apical papilla can survive after pulp necrosis and apical periodontitis.
- A conservative approach should always be considered as a first choice of treatment for immature teeth with pulp necrosis.

16:30 to 18:00

16:30

Modified chlorophyll versus Fotosan-agent antimicrobial assessment in root dentin blocks infected with endodontic mix biofilms

*Diogo P¹, Mota M², Fernandes C², Sequeira D³, Uliana M⁴, Oliveira K⁴, Palma P¹, Caramelo F⁵, Miranda I⁶, Faustino A⁷, Neves G⁷, Gonçalves T², Santos JM¹

¹Área de Medicina Dentária, ²Centre for Neuroscience and Cell Biology, ³Department of Dentistry - Faculty of Medicine, University of Coimbra, Coimbra, Portugal, ⁴Department of Chemistry, Federal University of São Carlos, São Carlos, Brazil, ⁵Laboratory for Biostatistics and Medical Informatics, Faculty of Medicine of University of Coimbra, Coimbra, Portugal, ⁶Department of Microbiology, Faculty of Medicine, Porto, Portugal, ⁷Department of Chemistry & QOPNA, University of Aveiro, Aveiro, Portugal

Aim Assess the antimicrobial efficacy and cytotoxic effects of 90s and 300s of 0.1 mg/mL Zn(II)e6Me versus 90s of Fotosan agent and 3% NaOCl at human root dentin blocks infected with 48h mixed biofilms of *Enterococcus faecalis* with *Candida albicans* (1:1).

Summary Four experimental groups: I) Zn(II)e6Me 90s; II) Zn(II)e6Me 300 s; III) Fotosan agent 90 s; IV) 3% NaOCl 90s were tested. All groups had 7 root blocks infected with mixed biofilms and two control groups, positive (mixed biofilms) and negative (RPMI-medium). After a pre-incubation period of 15 min in total absence of light for all PSs, samples were exposed to a continuous orange light emitting GaAsP/GaP diode laser (627 nm, 75 mW, 3150 J/cm²). Biofilms removal percentage was quantified with SR assay, cells viability with XTT assay and cytotoxic effects with Alamar blue assay. Mixed biofilms and antimicrobial PDT dentin asepsis pattern were analysed with scanning electronic microscopy (SEM). Statistical differences between groups were assessed with the independent samples t-student test or Mann-Whitney test and significant level of 0.05. Zn(II)e6Me presented the best antimicrobial approach after an irradiation period of 90 (79.7%) and 300 s (81.7%), followed by

3% NaOCl (75.5%); this antiseptics pattern was consistent at inner and outer samples. No dark or photoinduced cytotoxic outcomes were detected for Zn(II)e6Me over human cells at 24 and 48 h.

Key Learning Points

- The best aPDT outcomes were obtained with modified chlorophyll Zn(II)e6Me.
- Zn(II)e6Me performs better in mixed biofilm removal than reference Fotosan agent photosensitizer.
- Zn(II)e6Me has better antiseptics pattern than 3% NaOCl.
- No cytotoxic effects over human apical papilla cells were identified for Zn(II)e6Me.

16:48

Evidence-based Laser-Assisted Endodontics for bacterial reduction: Where are we now?

*Farmakis ETR

Department of Endodontics, Faculty of Dentistry, National and Kapodistrian University of Athens, Athens, Greece

Aim To present available scientific data on Laser-Assisted Endodontics for bacterial reduction, so one can understand the potentials and limitations of this adjunct treatment.

Summary Since the first application of Laser irradiation in Endodontics almost 45 years ago, many attempts have been made for the utilization of this powerful form of energy in the everyday clinical practice of Endodontic Treatment. Through trial and error, failure and success, some protocols have been established and evolved, others have been abandoned. Nowadays, we have come to a point that we understand how the parameters of laser irradiation (wavelength, pulse length, power, fluence) interact with the target (through absorption, penetration depth, diffusion etc) and all of the above influence the outcome. As for lasers' bactericidal action, it is either direct (e.g. Diode, Nd:YAG - most likely in the form of heating) or indirect in combination with photosensitizers i.e. Photo Activated Disinfection (e.g. LED, Diode). Additionally, the Erbium lasers, due to the absorption of the laser light in water, induce cavitation in the irrigation solution (Laser Activated Irrigation – LAI)

resulting in a unique and vigorous irrigant agitation. The bactericidal capacity of laser irradiation in all forms of action (direct, indirect, LAI) has been abundantly investigated, but the vast majority is basic in-vitro research. Additionally, all systematic reviews and meta-analyses conclude that lasers are not a substitute of current disinfection procedures, but a very useful adjunct. LAI, in this respect, appears to perform better than ultrasound. For both, high-level evidence on the basis of clinical research is still missing. For direct irradiation of root canal walls the temperature rise on the external root surface is often overseen, despite over-the-safety-threshold recordings.

Key Learning Points

- Lasers in Endodontics are a useful adjunct in the field of disinfection.
- More research (especially RCTs) is needed to verify and eventually optimize the present day favoured laser irradiation protocols.
- Protocols that respect the safety of surrounding tissues, are needed, when a direct bactericidal approach is chosen.

17:06

Does photon-induced photoacoustic streaming (PIPS) activation of irrigation solutions alter the dentine microhardness?

*Akbulut MB, Terlemez A

Department of Endodontics, Faculty of Dentistry, University of Necmettin Erbakan, Konya, Turkey

Aim The aim of this in vitro study was to evaluate the efficacy of photon-induced photoacoustic streaming (PIPS) activation of sodium hypochlorite (NaOCl), chlorhexidine (CHX) or Ethylene-Diamine-Tetra-Acetic acid (EDTA) on the dentine microhardness and to assess the compositional changes of root dentine treated with irrigation solutions with and without the addition of PIPS activation.

Summary Root canals of 72 extracted single-rooted teeth were prepared with ProTaper Next files up to size #X3. Teeth were fixed in microcentrifuge tubes with silicone impression material. After

setting of the silicone, teeth were removed and split longitudinally in buccolingual direction. One half was used as control (pretreatment) while the other was placed into the tube (posttreatment). Then specimens were divided into 6 test groups (n = 12) (three with and three without PIPS activation). The irrigants tested were 2.5% NaOCl, 17% EDTA and 2% CHX. Experimental tooth specimens were irrigated with 6 mL of the test solution, with additional PIPS activation for the PIPS groups. After treatment, tooth halves of experimental and control groups were sectioned horizontally at the level of midroot. Apical parts were embedded in acrylic resin and were grounded flat. Then each apical part was subjected to Vicker's microhardness testing. Three indentations were made on each specimen at depth of 100 μ m from the edge of canal lumen using 300-gr load and 20-second dwell time. Representative hardness values were obtained and percentage reduction of hardness was calculated. Randomly selected three coronal parts of each group were used for energy dispersive X-ray spectroscopy (SEM-EDX) to measure element content. Among the irrigant alone groups, NaOCl and CHX did not alter the dentin microhardness whereas statistically lower microhardness values were obtained in EDTA group. PIPS activation did not lead to additional alteration in dentine microhardness. Chemical composition of dentine was affected by all irrigants used.

Key Learning Points

- Irrigation solutions may cause alteration in chemical and physical properties of dentine.
- Dentine microhardness was significantly affected by the irrigation solution, not by the PIPS activation.
- PIPS activation seems to be safe since it did not lead to extra reduction in dentine microhardness and did not influence chemical content of dentine.

17:24

The role of recent technology in the management of biofilm and the decrease in bacteria inside the root canal system

*Alsofi L

Department of Endodontics, Faculty Of Dentistry, King Abdulaziz University, Jeddah, Saudi Arabia

Aim The aim of root canal treatment is to eradicate bacteria and microbes from inside the root canal system. Several challenges are presented by the complex canal geometry and the presence of microbial biofilm. Anatomical difficulties such as C-shaped canal, isthmuses, lateral canals, and apical delta are hardly touched by mechanical instrumentation. According to the literature, 30-50% of the root canal wall is left untreated. Cleaning such areas rely mainly on the chemical action of root canal disinfectants.

Summary Microbial biofilms are dynamic communities of interacting sessile cells. They are irreversibly attached to a solid substratum, as well as to each other and embedded in a matrix of extracellular polymeric substances. Pathogenicity of the biofilm is expressed through congregation, quorum sensing, metabolic communication, genetic interchange, and competition. The presence of biofilm inside the root canal (intraradicular) presents further challenges to clean the root canals. These challenges are presented by difficulty of removal, resistance to antimicrobial action, and survival in tough environmental conditions. This intra radicular biofilm could extend into extra radicular biofilm (6% of the cases). Extra radicular biofilms are associated with post-treatment apical periodontitis and are usually associated with symptoms. The therapeutic options for canal disinfection consist of two parts, mechanical instrumentation and the use of antimicrobial agents. In this lecture we will present an update on biofilm and irrigation. We will present different approaches used to disinfect the root canal biofilm. We will talk about methods of biofilm assessment and the advanced anti-biofilm options. We will also present methods used to improve the irrigation dynamics inside the root canal.

Key Learning Points

- New technology that could disrupt biofilm and decrease bacteria
- The application of pressure to irrigants could improve fluid dynamics
- The use of sonic/ultrasonic agitation

- The endoactivator system has been reported to be able to clean debris from lateral canals and remove the smear layer
- The use of negative pressure agitation
- APDT (Antimicrobial Photodynamic Therapy)
- Laser assisted root canal disinfection

Saturday 16th Hall 5 Meeting Studio 211 & 212

09:00 to 10:30

09:00

Diagnostic validity of periapical radiography and CBCT for assessing persisting periapical lesions after apicectomy

*Kruse C¹, Spin-Neto R¹, Reibel J², Wenzel A¹ Kirkevang LL¹

¹Section of Oral Radiology, Department of Dentistry, Department of Dentistry, Aarhus University, Aarhus, ²Oral Pathology and Medicine, Department of Odontology, University of Copenhagen, Copenhagen, Denmark

Aim To assess the diagnostic validity of periapical images (PR) and Cone Beam-CT (CBCT) for determining inflammation in surgical endodontic retreatment (SER) cases that were re-operated (SER-R) due to unsuccessful healing, using histology as reference for presence of periapical inflammation.

Summary Healing after SER is traditionally assessed in PRs, but during recent years the use of CBCT has increased within endodontics. In general more apical lesions are detected when CBCT is used. However, basic research on the true nature of these lesions is missing. Records from patients receiving SER in 2004-10 were screened (149 patients/165 teeth). In total 108 patients (119 teeth) were recalled for clinical follow-up examination, PR and CBCT, of which 74 patients (83 teeth) participated. Three observers assessed the periapical radiographic area in PR and CBCT using the criteria by Rud and Molven, which were dichotomised into "healed" or "non-healed". In 23 patients the tooth was assessed as non-healed, and expected to have a favourable prognosis for subsequent functional retention. These patients were offered R-SER; 20 accepted. During SER-R, biopsy of the periapical lesion was performed and histopathology verified whether or not inflammation was present. One biopsy was lost in processing and in total biopsies from 19 periapical lesions were examined. Histopathologic examination revealed 42% (lesions=8) without periapical inflammation, 16% (lesions=3) with light inflammation, and 42% (lesions=8) with moderate to intense

inflammation. All re-operated cases were assessed non-healed in CBCT while in PR 11 of these were assessed healed. A correct diagnosis was thus obtained in 58% with CBCT (true positives) and 63% with PR (true positives+true negatives).

Key Learning Points

- Not all radiographic lesions observed in CBCT after follow-up of initial SER reflect periapical inflammation.
- The over-diagnosis of periapical inflammatory lesions in CBCT may subsequently lead to over-treatment, from which the patient has no benefit.

09:18

Comperative assesement of odontogenic maxillary sinus pathology using CBCT and intraoral radiographs

*Tsompanides G¹, Angelopoulos C², Iambrianidis TH³

¹Dental Department, 424 General Medical Army Hospital, ²Department of Dentoalveolar Surgery, Surgical Endodontics and Radiology, School of Dentistry, Aristotle University of Thessaloniki,

³Department of Endodontics, School of Dentistry, Aristotle University of Thessaloniki, Thessaloniki, Greece

Aim The aim of this oral presentation is to describe the radiographic characteristics of odontogenic pathological alterations in the maxillary sinus as seen on cone-beam computed tomography (CBCT) scans and intraoral radiographs.

Summary The progression of periapical pathology in teeth whose root apices are in close proximity to or extend into the maxillary sinus can elicit inflammatory changes in the mucosal physiology and, subsequently, the development of odontogenic sinusitis. Dental records, intraoral (panoramic and/or periapical) radiographs and CBCT scans of 182 patients showing sinus disease in unilateral or bilateral maxillary sinuses were evaluated. Sinus alterations were considered as following: generalized or localized mucosal thickening, maxillary sinusitis, polyps and retention cysts. The

odontogenic conditions evaluated were periapical lesions, inadequate endodontic treatment and periodontal bone loss. Descriptive analyses were performed. The most prevalent condition was localized mucosal thickening (52,8%), followed by generalized mucosal thickening (30,5%), maxillary sinusitis (9.2%), retention cysts (4.6%) and polyps (2,9%). Localized mucosal thickening was statistically associated with periapical lesions whereas a close anatomic relationship between teeth and the sinus floor was noted. CBCT scans were more sensitive in detecting sinus pathology compared to intraoral radiographs. The additional clinically relevant information obtained with the CBCT images compared to intraoral radiographs facilitated diagnosis and improved the decision making process.

Key Learning Points

- Changes in the maxillary sinuses associated with periapical pathology are a common condition. Maxillary first and second molars are most often involved, individual or multiple roots may be implicated in the sinus pathology.
- The clinician must know the radiographic characteristics and be able to identify these conditions.
- CBCT imaging is the imaging modality of choice for evaluating the maxillary sinus pathology and the associated odontogenic conditions compared to intraoral radiographs.

09:36

3D Imaging of External Cervical Resorption patterns: possibilities and challenges

*Mavridou AM¹, Hauben E², Wevers M³, Bergmans L⁴, Lambrechts P¹

¹Department of Oral Health Sciences. BIOMAT Research Cluster, KU Leuven & University Hospital Leuven, ²Department of Imaging & Pathology, KU Leuven & University Hospital Leuven, ³Department of Materials Engineering (MTM) KU Leuven, ⁴Department of Oral Health Sciences, KU Leuven, Leuven, Belgium

Aim To highlight the need of using 3D imaging to assess the pattern of external cervical resorption (ECR) of different clinical cases. The advantages and drawbacks of this approach are also discussed.

Summary In this study indicative cases (n=10) of ECR were investigated. The 3D patterns of these different clinical cases were assessed with CBCT (Morita, FOV 40x40, 60x60) before extraction, and with a high performance NanoTom scanner (GE Measurement and Control Solutions, Wunstorf, Germany) after extraction. To verify the types of cell tissues involved, additional histological analysis was performed. From the experimental results it was shown that 3D imaging provided an accurate observation of the resorption tissues. This allows for an accurate evaluation of the morphological characteristics and pattern of resorption. In particular, the initiation point of the resorption (portal of entry), the resorption extent, the resorption Heithersay channels inside the tooth structure, the pulp reaction through calcifications, the Pericanalar Resorption Resistant Sheet (PRRS) which surrounds the root canal, the extent of reparative bonelike tissue formation and the interconnections (portals of exits) with the external root surface can be visualized. Furthermore, a follow-up of clinical cases is possible, in a rapid and minimally invasive way. Thus, it is strongly believed that 3D imaging could help dental researchers and clinicians to understand and correctly evaluate ECR pattern. However, despite its unquestionable added value, some aspects still need to be addressed carefully. The main drawback concerns the in vivo evaluation (by CBCT) of the extent of the reparative stage, which is frequently underestimated. Also, the bone turnover in the reparative bonelike tissue needs to be considered. In addition, a lack of know-how can lead to a wrong interpretation of the obtained image. Indicative clinical examples are presented, in order to illustrate these issues and propose how to correctly deal with.

Key Learning Points

- 3D imaging is a useful diagnostic tool in dentistry, as it is a rapid and minimally invasive technique for both in vitro and in vivo analysis
- The pattern and structural features of external cervical resorption are more complex than generally accepted.
- The main challenge of 3D imaging derives from the underestimation of the reparative

09:54

Assessment of endodontic complications by using intraoral radiography and a CBCT System with the application of three different artifact reduction modes: an ex vivo study

*Cemre K¹, Gül S², Funda Y¹, Kivanc K²

Department of ¹Endodontics, ²Dentomaxillofacial Radiology, Ankara University, Ankara, Turkey

Aim To assess observer ability to detect simulated endodontic complications in root filled teeth from periapical images and CBCT images using different artifact reduction modes.

Summary Our study comprised of 39 human mandibular molar teeth. Simulated endodontic complications were performed as follows: G1) Instrument separation, G2) Strip perforation, G3) Underfilling of root canals, G4) Overfilling of root canals. Teeth were placed in dry human mandibles. All teeth were imaged using Planmeca ProMax 3D Max CBCT without artifact reduction and with artifact reduction low, medium and high modes. Also, digital periapical radiographs were exposed with a Gendex x-ray generating machine (Gendex Digital Systems, Hatfield, USA) operated at 65 kVp and 7mA by using a PSP detector (Digora Optime). Images were evaluated twice by four observers for the presence/absence of listed endodontic complications using a 5-point scale. Weighted kappa coefficients were calculated to assess observer agreement. The areas under the AUC (Area Under Curve) values were calculated and the AUC values for each image mode, observer, treatment group and reading were compared using chi-square tests, with a significance level of $\alpha=0.05$. In general, poor and average intra- and inter-observer agreement values were obtained. We found no statistically significant differences ($p>0.05$) between different artifact reduction modes in terms of diagnosing ex vivo endodontic complications.

Key Learning Points

- All CBCT image modes performed similarly in detecting simulated endodontic complications.
- CBCT can be considered as a supplementary technique for the detection of endodontic complications in certain cases.

10:12

Guided Endodontic Treatment Using a New Software Approach

*Lang T¹, Engel K², Zollorsch A², Gaengler P¹

¹*ORMED Institute for Oral Medicine at the University of Witten/Herdecke, Witten,* ²*SICAT GmbH und Co. KG, Bonn, Germany*

Aim Presenting a future clinical workflow for planning guided endodontic access based on CBCT and optical impression data.

Summary Methodology A pre - clinical study was carried out using a DXTTR III – Natural phantom head (Dentsply Rinn) with realistic teeth. IO images (Xios Supreme, Dentsply Sirona (DS)), CBCT (Orthophos SL, 5 x 5, DS) as well as CEREC (DS) optical impressions were taken. For further root canal diagnostics IO images and optical impressions were matched with CBCT data in a prototype of the SICAT ENDO (SICAT GmbH, Bonn) software. The planning of the drill path for the root canal access was also done in dedicated workspaces in SICAT ENDO. In order to carry out the guided endodontic treatment a SICAT ENDOGUIDE template was produced and used for guided access to the root canals. Results The root canal access was timesaving, highly effective and resulted in a smaller cavity compared to tapered funnel preparation and furthermore in optimized root canal instrumentation. Conclusions The presented novel clinical approach using the SICAT ENDO software for planning and the SICAT ENDOGUIDES during the endodontic access preparation seems to be an efficient and safe alternative to traditional methodologies. Future clinically controlled trials should investigate the reproducibility of this technique, the potential of accelerating the total treatment and, finally and most importantly, the ability to conserve more crown and root dentin compared to the traditional approach. In this sense, guided endodontics could contribute to minimal invasive dentistry in the future, keeping more teeth longer in function.

Key Learning Points

- novel clinical approach in treating obliterated root canals

11:00 to 12:30

11:00

Radiographic and clinical study of dens invaginatus prevalence in Israeli dental patients.

*Flaisher Salem N, Elbahary S, Kfir A, Natour L

Department of Endodontics, Tel Aviv University, Tel Aviv, Israel

Aim To assess the prevalence and characteristics of dens invaginatus in anterior teeth and to report the association between clinical and radiographic features of dens invaginatus in a sample of Israeli population.

Summary Methodology A cross-sectional study was performed using periapical radiographs and clinical images of 616 patients who presented to the Department of Orthodontics, School of Dental Medicine, Tel Aviv University between the years 2006- 2015. Maxillary anterior teeth were evaluated for the presence and characteristics of dens invaginatus. The invaginations categorized by Oehlers (1957) classification. Frequency distribution of teeth with dens invaginatus was calculated and statistical analysis was performed with chi-square test. Results Dens invaginatus was detected in 422 out of 1624 maxillary anterior teeth of 547 patients, with a tooth prevalence of 26.1%; Bilateral dens invaginatus was seen in 138 patients, whereas unilateral dens invaginatus was demonstrated in 92 patients. Maxillary lateral incisors were more affected teeth than central. The majority of the teeth had clinical characteristics (96%). The most commonly seen type of dens invaginatus was type I (90.4%). A significant associations with some clinical feature and dens invaginatus were detected. Conclusions Dens invaginatus was relatively common in the studied population and may exhibit foreseen clinical appearance. A careful oral examination, radiographs, a suitable treatment plan and follow-up programme are crucial for early diagnosis and treatment for teeth with DI.

11:18

New classification of endodontic access cavities

*Isufi A¹, Pepla E², Gambarini G¹

¹Department of Endodontics, Sapienza University of Rome, Rome, Italy, ²Department of Conservative and Endodontics, Bristol University, Bristol, United Kingdom

Aim There are many studies about cavities but very few information about volumetric differences, thus generating confusion among researchers and practitioners. The aim of this presentation is to determine and compare the difference of dentine volume removed when preparing traditional and two different minimally invasive (conservative and ultra-conservative) access cavities, and propose a new classification.

Summary 30 maxillary and 30 mandibular molars were selected based on similar dimensions, initially scanned with CBCT (I cat) and then divided in two groups each one (n=20) containing 10 upper and 10 lower molars. In Group A, a conservative minimally invasive endodontic access cavity preparation (CMI) was performed as described by Clark and Khademi. In Group B, an ultra-conservative minimally invasive (UCMI) endodontic access cavity was performed, preserving most part of the pulp chamber roof. In Group C, a traditional access cavity (TAC) was performed, eliminating all dentinal and enamel interferences. After cavities were prepared for each group, specimens were scanned again with CBCT. The sliced image data were exported as DICOM-file and imported into the MeVisLab framework system for segmentation and volume measurement. After segmentation, volumes of coronal dentine and enamel were measured and the difference in percentage of the volume removed when preparing endodontic access cavities was calculated. The data were subjected to statistical analyses of variance. Based on this classification, we compared in vitro fracture strength of root-filled and restored teeth with the different endodontic access cavities.

Key Learning Points

- A new classification for endodontic cavities is proposed, dividing them into three categories.
- This classification was helpful to complete a study aiming at evaluating the clinical impact of different endodontic cavities on the fracture resistance of endodontically treated teeth.

11:36

Investigation of the physiological foramen of maxillary and mandibular molars using micro-computed tomography

*Wolf TG¹, Paqué F², Willershausen B¹, Briseño Marroquín B¹

¹Department of Operative Dentistry, University Medical Center Mainz, Mainz, Germany, ²Division of Endodontology, University of Zurich Dental School, Zurich, Switzerland

Aim The aim of this ex-vivo study was to examine the diameter and shape of the physiological foramen as well as the distance between the physiological and anatomical apex of maxillary and mandibular first and second molars using micro-computed tomography.

Summary **Materials / Methods** The morphological dimensions of 305 maxillary and 211 mandibular molars with a total of 1,727 physiological foramina were examined and analyzed by micro-CT. **Results** Mean narrow and wide diameters of the physiological foramina were 0.24, 0.22 and 0.33 mm and 0.33, 0.31 and 0.42 mm in the mesiobuccal (MB), distobuccal (DB) and palatal (P) root in maxillary first molars; 0.24, 0.22 and 0.33 mm and 0.41, 0.33 and 0.44 in the MB, DB and P roots in maxillary second molars. Mandibular first molars showed mean narrow and wide diameters of 0.24 and 0.30 mm (M) and 0.39 and 0.46 mm (D); mandibular second molars 0.25 and 0.31 mm (M) and 0.47 mm (D). The mean distance between the physiological foramen and the anatomical apex was 0.82, 0.81 and 1.02 mm, and 0.54, 0.43 and 0.63 mm in the MB, DB and P roots of the maxillary first and second molars. A mean distance of 0.95 (M) and 1.05 mm (D) and 0.78 (M) and 0.81 mm (D) in mandibular second molars were observed. The most frequently observed form of the physiological foramen was oval followed by round and irregular. **Conclusion** Based on the results obtained, assumable recommendations for final preparation size of the physiological foramina were calculated. However, when taking into consideration resulting standard deviations, margin errors must be cautiously considered when making a final decision in clinical endodontic treatment.

Key Learning Points

- diameter and shape of the physiological foramen and distance between the physiological and anatomical apex of maxillary and mandibular first and second molars by micro-CT
- assumable calculated recommendations for final preparation size for maxillary and mandibular first and second molars

11:54

Endodontic treatment of patients with taurodont : Case series

*Alam S, Ali S, Sharma R

Department of Conservative Dentistry and Endodontics, A.M.U, Aligarh, India

Aim Endodontic treatment of a taurodont tooth requires careful handling and meticulousness to detail in identifying the number of root canal orifices. This case series explores the endodontic challenges and its management associated with taurodont teeth.

Summary Taurodontism is characterized by vertically elongated pulp chamber with apical displacement of root bifurcation and short roots. It is due to Hertwig's epithelial root sheath diaphragm invaginating at a more apical level. Endodontic treatment of a taurodont tooth may be exacting as it requires special care in identifying and treatment of the complex root canal system. This case series discusses the challenges and its management associated with the endodontic treatment of taurodont.

12:12

Using Pebble pad (eportfolios) in undergraduate dentistry for reflective learning

*Sadr A

Department of Endodontics, Charles Sturt University Dental School, Orange, Australia

Aim Background: it is expected that following graduation dental students can regulate their own practice, especially for dentists whose work is hidden by their very location by providing evidence and reflecting on their clinical experience. It needs changing pedagogy to more interactive approach

with better way of communication. This can be achieved by Pebble pad software. Objective: This presentation reports the implementation of Pebble Pad for gathering the practical tasks in an Endodontic program in a dentistry course for undergraduate 5th year dental students based upon independent, reflective learning and some advantages and issues following that.

Summary METHODS: Students were asked to report about their patient journey through all the investigations and treatment they have undertaken during different rotations of various dental clinics. It is encouraged to write with as much detail as possible. Also students were asked about criteria for each stage of Endodontic practical task through a formative exam. After modifying and revising ideas students were asked to submit their self-assessment for each of their practical tasks through Pebble Pad. A questionnaire also was distributed to investigate the effectiveness of Pebble Pad. Discussion: Eportfolios' use aim was to reduce the time spent travelling to supervise students at different clinics, to improve students' learning experiences as well as expose them to this worldwide software, which is student centered and is the best method of self-reflection. Some advantages and issues of portfolios with students' perception will be discussed in the presentation.

Key Learning Points

- Self-assessment and reflective learning is an essential character for life-long learning graduates.
- Pebble pad and e-portfolios is a great software helping the practitioners for their DX and treatment planning of the patients specially in a placement.
- Graduate can use pebble pad for follow up of their cases as a learning tool.

14:30 to 16:00

14:30

'Digital Dentist', an evidence based tool to appreciate and communicate the status and prognosis of teeth.

*Daneels L

Private Practice, Beerse, Belgium

Aim to present a new application to assess and communicate the status and prognosis of teeth.

Summary Before starting the endodontic treatment dentist and patient need to be aware of the global oral situation and the specific local factors influencing the prognosis of that tooth. The Flemish Society for Endodontology, supported by the Dutch and Belgian Society of Endodontology and the Dutch Flemish Society for Restorative Dentistry, worked out an iPad application which integrates the golden standards of every subarea in dentistry in order both to systematically scan mouth and teeth and to communicate these findings to the patients. Eight factors are considered. On patient level: medical status, decay susceptibility, motivation/financial resources, position/occlusion. On tooth level: tooth structure, bone/gums, root canal, occlusal overload. This app includes many illustrations, making the information understandable for patients. For every patient a file is made. After completion, a pdf with the conclusion can be stored on the iPad and easily shared with the patient. The conclusion can be exported by mail, Google drive, Dropbox or other options to be enclosed in the dental file. The first tests show it is easy and fast to use and enthusiasm grows when using it.

Key Learning Points

- Stress the importance of an overall view of mouth and teeth before treatment
- Communicating comprehensibly with patients will result in motivated, satisfied patients
- The 'Digital Dentist' App will help evaluating the problems pre-operatively and communicating those to the patients.

14:48

Minimally invasive endodontics - A new diagnostic system for assessing pulpitis and subsequent treatment needs

Duncan HF¹, Tomson PL², El Karim IA³, McKenna G⁴, Dorri M⁵, Stangvaltaite L⁶, Sluis LW⁷, *Wolters WJ⁷

¹Division of Restorative Dentistry & Periodontology, Dublin Dental University Hospital, Dublin, Ireland

²College of Medical & Dental Sciences, The University of Birmingham School of Dentistry,

Birmingham, United Kingdom, ³Centre for Dentistry, School of Medicine, Dentistry and Biomedical

Sciences, Belfast, Ireland, ⁴Centre for Public Health, Queen's University Belfast, Belfast, Ireland,

⁵School of Oral and Dental Sciences, Bristol Dental School, Bristol, United Kingdom, ⁶Department of

Clinical Dentistry, UiT The Arctic University of Norway, Tromsø, Norway, ⁷Center of Dentistry and Oral

Hygiene, University medical Center Groningen, Groningen, Netherlands

Aim To introduce a new way of thinking about the inflamed pulp and to highlight that there is reversibly inflamed tissue in pulps that are currently diagnosed as irreversibly inflamed. The currently employed terminology may not reflect the actual inflammatory status of pulps evaluated clinically. A new diagnostic system with new terminology will highlight the healing potential of the pulp. This implies that current treatment strategies are evaluated and revised to maintain pulp vitality with associated benefits.

Summary Developments in our understanding of pulp biology and the response of the pulp to the release of dentine-bound bioactive growth factors have highlighted that pulps in mature teeth have a greater regenerative capacity than previously thought. Preserving all or part of the pulp is beneficial and less invasive than conventional root canal treatment. It retains the biological immune response and could help prevent infection of the periapical tissues. Correlations between histological findings and corresponding clinical signs, symptoms and tests can be used to carefully differentiate between different stages of reversible and irreversible pulpitis. In addition, it has

become evident that if the correct vital pulp treatment is employed, pulp tissue previously diagnosed as irreversibly inflamed can at least be partially maintained. This highlights a problem with the existing diagnostic classification system in that the use of the term “irreversible” is misleading. Therefore, the aim of this presentation is to introduce a new way of diagnosing the various stages of pulpitis and also to relate the diagnosis to alternative minimal invasive treatment choices based on the degree of pulpal inflammation.

Key Learning Points

- The term ‘irreversible’ pulpitis is misleading.
- There is good correlation between clinical symptoms of pulpitis and the corresponding histological state of a diseased pulp.
- Caries progression in itself does not dictate treatment modalities but observed clinical symptoms are important in predicting pulpal conditions and therefore indicate the choice of treatment.
- Vital pulp tissue that has been managed properly is quite resilient and a diseased pulp can heal if most of the inflamed/necrotic tissue is removed..

15:06

Treatment planning in cases with severely obliterated root canals - CBCT imaging and microscope visualization

*Kiefner P

Private Practice limited to Endodontics, Stuttgart, Germany

Aim This presentation describes the treatment planning from the diagnostic 3D CBCT examination to the use of the operating microscope in order to identify extremely obliterated root canals. The main aim of this presentation is to give a clear view of the possibilities and limitations of the diagnostic CBCT examination and to show the advantages of optical magnification throughout the entire treatment in cases with extremely obliterated root canals.

Summary Achieving the goals of the endodontic treatment in teeth with severely obliterated root canals is a challenge for every endodontist. When dealing with root canal obliterations treatment planning needs accurate informations regarding the morphology of the root canal(s) and the position of the coronal orifice(s) in the pulp chamber floor in order to avoid iatrogenic damaging of the tooth. 19 teeth with severely obliterated root canals were treated over a period of 3 months using a strict treatment planning protocol: clinical inspection, diagnostic radiographic and CBCT examination and intra-operative inspection aided by a dental microscope. The orthoradial radiograph showed in 1 of 19 cases (5,26%) a very narrow root canal outline and no canal outline for the rest. The CBCT examination revealed the root canal outline in 11 from 19 cases (57,90%). Localizing of the coronal orifice of the root canal was successful in 18 from 19 cases (94,73%), even then when radiographic and CBCT examination failed to show any canal outline. In one case there was no possibility to localize the root canal using either CBCT examination or microscopic enhanced visualization. In our findings the overall success rate in finding, cleaning, shaping and filling obliterated root canals is similar with teeth with normal root canal dimensions. The use of the CBCT examination and microscope visualization can improve the overall success rate in localizing obliterated root canals.

Key Learning Points

- understanding the possibilities and limits of the CBCT in the imaging of severely obliterated root canals
- understanding the benefits in using the dental microscope for the localization of canal orifices in cases with extremely obliterated root canals
- learning how to avoid iatrogenic damage of the crown and root of teeth with severe calcifications

15:24

Radiopacity of silicate-based cements and a comparison of three contemporary repair materials revised

Karapınar-Kazandag M¹, Ovsay E¹, *Tanalp J¹, Dolekoglu S², Ersoy M³, Kaptan RF¹, Ersev H⁴

¹Department of Endodontics, ²Department of Dentomaxillofacial Radiology, ³Department of Restorative Dentistry, Yeditepe University, Faculty of Dentistry, ⁴Department of Endodontics, İstanbul University, Faculty of Dentistry, İstanbul, Turkey

Aim The aim this oral presentation is to make a general review of the studies pertaining to the radiopacity of some repair materials. The clinical significance of radiopacity is emphasized and following the provision of a general outline of studies performed so far, a study is presented in which 3 contemporary repair materials were compared in terms of radiopacity.

Summary The material used for vital pulp treatments as well as other sealing and repair procedures are expected to have favorable properties such as good biocompatibility, sealing ability, minimal leakage, low cytotoxicity and lack of dissolution in tissue fluids. Another important feature expected from an ideal repair material is adequate radiopacity in order to be easily discerned from anatomical structures This property is especially important when pulp capping procedures and retrograde fillings are concerned which are applied in relatively lower thicknesses. The radiograph taken following pulp capping or other repair procedures must ensure adequate apical sealing so that the practitioner can complete the procedure. This can be accomplished by using a material that is distinguished in radiographs. This presentation makes a general overview of the studies on radiopacity of contemporary repair materials performed so far and present an in vitro study where ProRoot MTA, Biodentine and Pulpine Mineral were compared in terms of their radiopacity. The results revealed that the highest radiopacity value was found with ProRoot MTA and the lowest with dentine. The ProRoot MTA had the highest radiopacity with a statistical significance compared to Biodentine and Pulpine MI.

Key Learning Points

- ProRoot MTA has the highest radiopacity compared to other repair materials which is above the universally accepted levels.

- Biodentine and Pulpine Mineral have radiopacities lower than the internationally 3 mm Al thickness. Consideration should be given on this property when using these materials in the clinic.
- Further research is warranted on other physical, chemical and biological properties of materials as radiopacity is only one aspect of repair materials.

Thursday 14th Hall 6 Meeting Studio 214 & 216

09:00 to 10:30

09:00

Shaping for cleaning: Reciprocation and Adaptive motion

*Gergi R

Department of Endodontics, Saint Joseph University, Beirut, Lebanon

Aim To compare and evaluate the shaping ability of several nickel titanium instrument systems with different motions: two reciprocating single-file systems (Reciproc and WaveOne) and one continuous rotation/reciprocation full-sequence system [Twisted File (TF) Adaptive] using micro-computed tomography.

Summary Root canal shaping remains one of the most important procedures in endodontic treatment. Recently, several new reciprocating NiTi systems such as Reciproc (VDW, Munich, Germany) and WaveOne (Dentsply Maillefer, Ballaigues, Switzerland) have been introduced. Single-use, reciprocating motion and M-wire alloy are the main characteristics of these instruments. The M-wire alloy increases flexibility and improves its resistance to cyclic fatigue. Furthermore, the reciprocating motion is similar to balanced force technique that has been shown to maintain root canal curvature. Twisted File Adaptive (TF Adaptive), a combined continuous rotation and reciprocating motion has been developed by SybronEndo (Orange, CA, USA) with three unique design features, namely R-phase heat treatment, twisting of the metal and special surface conditioning. The manufacturer claims that this adaptive technology and twisted file design using R-phase treatment increases flexibility and allows the file to adjust to intra-canal torsional forces depending on the amount of pressure placed on the file. The main parameters used to evaluate a technique or an instrument that has been developed for root canal preparation should be “shaping the root canal whilst protecting the curvature of the canal” and “adequately cleaning the root canal walls”. With these new NiTi systems, investigations of their shaping ability are important to understand how the design features and different kinematics affect their performance.

Key Learning Points

- List the anatomical factors that make it difficult to achieve a sterile root canal system.
- Explain how the speed of the shaping process promoted by the current NiTi-based techniques affects cleaning and disinfection.
- Recognize the shaping limits of different NiTi systems.

09:18

A review of methods for quantitative evaluation of root canal transportation

*Fidler A¹, Tenyi A², Plotino L³

¹Department of Restorative Dentistry and Endodontics, University Clinical Centre, Ljubljana, Slovenia,

²Department of Endodontics and Restorative Dentistry, University of Ljubljana, Faculty of Medicine, Ljubljana, Slovenia, ³Grande Plotino & Torsello - Studio di Odontoiatria, Rome, Italy

Aim The aim of this review was to critically evaluate canal transportation evaluation methods, identify and mathematically compare transportation parameters, and give recommendations.

Summary MEDLINE (PubMed) from 1966 to December 2016 was searched, using the following search expression: (transportat* OR aberrat* OR undesir* OR center* OR erro*) AND Root Canal Preparation. Only studies with quantitative transportation evaluation methods were included and categorized in longitudinal, cross-sectional or three dimensional evaluation group. After thorough reading of the selected papers, a classification of the measurements and parameters used for the evaluation of root canal transportation was proposed and papers were categorized accordingly. Transportation was measured with amount of removed dentine (RD) or canal centre (CC) transportation measurement and both parameters were used for subsequent calculations of difference and ratio parameters. Careful observation of reviewed studies revealed relationships between transportation parameters that can be expressed mathematically. These mathematical relationships were demonstrated and confirmed in simulated canal transportations. In conclusion, numerous methods and parameters were utilized for the evaluation of root canal transportation.

The transportation values, obtained from the amount of RD based methods, are double of the value obtained for the CC transportation based methods. The CC transportation evaluation was found to be a most appropriate parameter as it is mathematically based and it allows description of distance and direction with only one measurement. Although canal transportation values along the canal have a typical pattern of local maximums and minimums, that can be determined after instrumentation, the transportation was usually reported for various number (1 to 30) and positions along the root canal length, that were determined before instrumentation. In three dimensional evaluation transportation was most often expressed as average value for apical, middle and cervical third. Consequently local maximum transportation values, which determine transportation errors such as ledge, zip or strip will be underestimated or even missed. The post-instrumentation measurement position determination and reporting of local transportation maximums was found to be most appropriate for reporting the canal transportation.

Key Learning Points

- comparison of transportation studies is difficult due to wide variety of transportation evaluation methods
- this review reveals mathematical and relationship between parameters

09:36

Micro-computed tomography evaluation of WaveOne Gold Primary and WaveOne Primary Classic shaping outcomes in mandibular first molars

*Roggia A, Alovisi M, Pasqualini D, Bobbio E, Berutti E

Department of Surgical Sciences, Dental School, Endodontics, University of Turin, Turin, Italy

Aim The aim of this study was to compare the ability of WaveOne Gold versus WaveOne Classic single file shaping systems to maintain the original root canal anatomy through microCT analysis.

Summary Thirty human extracted mandibular first molars were selected with fully formed apexes and independent mesial canals. Samples were randomly assigned to the two shaping groups:

WaveOne Gold and WaveOne Classic. The glide path was created with Proglider (Dentsply Maillefer) at the fully working length (WL). In group A, canals were shaped with WaveOne Gold Primary (tip size 25, taper .07) and in group B with WaveOne Primary Classic (tip size 25, taper .08). Specimens were scanned before and after canal shaping in order to perform the matching volumes and the post-treatment analysis (Bruker-microCT, Kontich, Belgium, 100 kV, 100 μ A, 15 μ m resolution, Al+Cu filter and 360° rotation). Afterwards the images were reconstructed and analysed by NRecon and CTAn softwares (Bruker-microCT) to evaluate canal volumes and areas, canal geometry enlargement and the centroid shift. Each radicular canal was dynamically studied observing the high resolution 3D rendering and the orthogonal cross sections. Results were analysed by 4 one-way ANOVA and post-hoc Student-Newmann-Keuls test ($P < 0.05$). Both the systems didn't show significant canal aberration. Both shaping systems seemed to maintain the original canal anatomy without statistically significant geometrical differences ($P > 0.05$) at coronal, middle and apical levels.

Key Learning Points

- WaveOne Classic and Wave Gold reciprocating systems maintain the original canal anatomy.
- MicroCT is a valuable method of analysis of shaping geometrical outcomes.
- WaveOne Gold showed better geometrical outcomes without statistically significant differences, probably due to its lower taper and more performant NiTi alloy.

09:54

Centering Ability of Five Glidepath Systems on S-Shape Resin Simulators

*Georgelin-Gurgel M, Dalet L, Michetti J, Hamdan R, Blasco-Baque V, Diemer F

Department of Endodontic Department, Faculté de Chirurgie Dentaire, Toulouse, France

Aim Nickel titanium (NiTi) file improve shape and predictability of root canal treatment. NiTi glidepath systems also improve speed and safety in the initial stages of endodontic therapy. The objective of this study was to compare the centering ability of different glidepath systems.

Summary Methods: 60 S-shaped endodontic training blocks were divided in 5 groups, each corresponding to a glidepath system: One G[®], Pathfile[®], ProGlider[®], ScoutRace[®] and a prototype system. The canals were colored and photographed prior to and following instrumentation. Pre- and post-instrumentation images were then superimposed using Photoshop[®] CS3 software and ImageJ software was used to measure the quantity of resin removed during glidepath file passage at 7 points on the canal. The results were analyzed using the ANOVA and Fisher methods with a 5% alpha risk. Results: The OneG[®] system resulted in the most overall preparation whereas the ScoutRace[®] resulted in the least overall preparation. All single files (One G[®], ProGlider[®] and a prototype) prepared the internal part of the curvature more than the external walls (ANOVA $p < 0.0001$), regardless of the overall level of preparation and of the curvature being examined (coronal or apical). Single file prepared the coronal curvature more than the apical curvature ($p < 0,0001$). The multiple-instruments system (PathFile[®] and ScoutRace[®]) prepared the inner and outer walls equally.

Key Learning Points

- All of the rotary glidepath instruments were able to negotiate both curves of the canal without fracture or distortion.
- The single-file systems displayed a tendency to produce more preparation on the inner part of the curvature and on the coronal curvature.
- Multiple-instruments systems displayed a better negotiation of the curvatures.

10:12

MicroCT Evaluation of the original root canal anatomy preservation in middle and coronal third after shaping with WaveOne Gold: comparison between no brushing and accentuated brushing techniques

*Bobbio E, Alovisi M, Pasqualini D, Piras M, Berutti E

Department of Endodontology, Dental School of Turin, Turin, Italy

Aim The objective of this MicroCT study was to describe the shaping outcomes of WaveOne Gold files with no brushing motion (group A) and accentuated brushing motion (group B) in order to evaluate the ability to maintain the original root canal anatomy.

Summary Thirty human extracted mandibular first molars were selected. Samples were randomly assigned in two shaping groups: no brushing technique (n=15) and accentuated brushing technique (n=15). Canal scouting was performed with #10 k-file and glide path with ProGlider up to full working length (WL). Irrigation was made with EDTA 10% and NaOCl 5%. Shaping was executed with WaveOne Gold Primary without and with accentuated brushing motion through the outside of the curvature in groups A and B respectively. Specimens were scanned before and after the canal shaping in order to perform the matching volumes and the post-treatment analysis (Bruker-microCT, 100 kV, 100 μ A, 15 μ m resolution, Al+Cu filter). Canal volumes and areas, canal geometry enlargement, the centroid shift and the entity of removed dentin were assessed in the middle and coronal third of the canals. Results were analysed with 4 one-way ANOVA and Tukey's post-hoc test ($P < 0.05$). WaveOne Gold with no brushing motion showed a better preservation of the canal anatomy.

Key Learning Points

- Reciprocating motion allows a good geometrical preservation of the root canal anatomy
- Brushing motion can interfere with the original root canal anatomy preservation during shaping with a reciprocating system
- MicroCT is a powerful tool for ex vivo evaluation of root canal morphology

11:00 to 12:30

11:00

Kinematic analysis of new and used reciprocating endodontic motors in two different modes

Irmak O¹, *Orhan EO²

Department of ¹Restorative Dentistry, Eskisehir Osmangazi University, ²Endodontics, Eskisehir Osmangazi University, Faculty of Dentistry, Eskisehir, Turkey

Aim This study analyzed the effect of clinical usage on kinematics of reciprocating endodontic motors with two different reciprocal modes.

Summary Methodology One new, three used reciprocating endodontic motors (X-Smart Plus, Dentsply Maillefer, Ballaigues, Switzerland) with two different reciprocating modes, WaveOne mode (W-mode) or Reciproc mode (R-mode), were analyzed. An angle measurement disc was inserted into a contra- angle. Reciprocating motions were recorded with high-speed camera at 1200 fps. and analyzed on a computer. Following kinematic parameters were calculated: duration of each reciprocating motion, engaging and disengaging angles, cycle rotational speeds, engaging and disengaging rotational speeds, net cycle angle, total cycle angle, and number of cycles to complete full rotation. One-way ANOVA and Kruskal Wallis test followed by multiple comparison tests were used for statistical analysis ($p=0.05$). Results In W-mode, actual engaging angles of all used and new motors were different than manufacturer's set values ($p<0.0001$), whereas there was no difference between actual engaging angles among motors ($p>0.05$). In R- mode, actual engaging angles of all used and new motors were similar to manufacturer's set values ($p>0.05$). There was no difference between actual engaging angles among motors ($p>0.05$). Both W-mode and R-mode showed statistically different values of actual disengaging angles for all used and new motors when compared with manufacturer's set value ($p<0.0001$). Conclusions This study confirmed that actual kinematics of reciprocating endodontic motors differ from manufacturers' set values. Some kinematic parameters were influenced by the clinical usage of motors.

Key Learning Points

- Actual kinematics values differ from manufacturers' set values.
- Although some kinematic parameters were influenced by the age of the motor,
- reciprocating cycles change arbitrarily.

11:18

Shaping ability of various thermomechanically processed nickel-titanium rotary instruments

*Işık V, Ersev H

Department of Endodontics, İstanbul University, Faculty of Dentistry, İstanbul, Turkey

Aim To compare the shaping efficacy of four rotary instrumentation systems manufactured using different processing technologies of nickel-titanium (NiTi) wire

Summary Pre- and post-instrumentation images of simulated S-shaped canals (n=20) were superimposed. The width of resin removal was measured to calculate the amounts of transportation and centering ratio. Pre- and post-instrumentation digital radiographic images of severely curved root canals of extracted teeth (n=20) were used to determine the changes in degree, radius and length of canal curvatures and then superimposed to determine the amount of transportation. The data were analyzed using analysis of variance and Kruskal Wallis test and post-hoc Tukey and Dunn's multiple comparison tests, and paired samples t-test. Significance was set at $P < 0.05$. In simulated S-shaped canals, K3XF (SybronEndo) gave the best results with respect to amount of transportation and centering ratio at the coronal curvature ($P < 0.05$) followed by HyFlex CM (Coltène-Whaledent) and ProTaper NEXT (Dentsply Maillefer) with no significant differences between them. At the apical curvature, K3XF and HyFlex CM presented significantly better centering ratio results than ProTaper NEXT ($P < 0.05$). BT-RaCe (FKG) showed significantly higher transportation values than the other three systems in both curvatures ($P < 0.05$) and the highest number of canal aberrations. K3XF created a continuously tapered and conservative preparation. In severely curved root canals, the use of K3XF and HyFlex CM resulted in less transportation ($P < 0.05$) and K3XF preserved original canal curvature.

BT-RaCe produced the highest amount of transportation at the apical end point. ProTaper NEXT exhibited canal straightening.

Key Learning Points

- Under the conditions of this study, K3XF and HyFlex CM appear to be more suitable to shape multi-curved and severely curved canals
- Instrumentation protocol and case selection seem to gain importance when using ProTaper NEXT and BT-RaCe
- NiTi alloy types with increased flexibility allow better shaping outcomes in complex canals.

11:36

Impact of a modified kinematic on the fatigue life of reciprocating instruments

Pirani C, *Iacono F, Generali L, Gatto MR, Gandolfi MG, Prati C

School of Dentistry, Endodontic Clinical Section, Department of Biomedical and Neuromotor Sciences, University of Bologna, Bologna, Italy

Aim To evaluate the impact of a modified kinematic on the fatigue life of the existing reciprocating instruments.

Summary Cyclic fatigue of 80 nickel-titanium reciprocating instruments was tested by measuring the time to fracture in an artificial stainless steel canal with an angle of 90° and a 5-mm radius of curvature, using two different kinematics. Instruments were divided as follows: Group 1 (n=10) WaveOne Primary; Group 2 (n=10) WaveOne Gold Primary; Group 3 (n=10) Reciproc R25; Group 4 (n=10) Reciproc Blue R25. X-Smart Plus (Maillefer) endodontic motor was used respectively in “WaveOne All” or “Reciproc All” setting, according to manufacturer’s instruction. Other four groups of the same instruments (n=10) were tested using an innovative reciprocating kinematics (EVO) with different rotation angles and based on a sinusoidal acceleration, using a specific motor handpiece with a 4:1 contra-angle (CEFLA, Imola, Italy). The mean half-life, beta (failure rate) and eta (characteristic life i.e. the number of seconds at which 63.2% of the product has failed) were

calculated for each group and compared with Weibull analysis. At a number of seconds corresponding to the mean half-life, instruments tested with the kinematics EVO presented higher values of eta in all groups. Reciproc Blue showed the highest eta value (233.05) and Wave One Gold the lower failure probability (46.98%).

Key Learning Points

- The modified kinematic with different angles and based on sinusoidal reciprocating acceleration had a positive impact on fatigue lifetime of reciprocating instruments.
- Present findings suggest the possibility of future improvements in the clinical use of reciprocating files.

11:54

Metallurgical effect on the mechanical behavior of rotary endodontic files using Finite Element

Analysis

*Galal M

Department of Endodontics, National Research Centre, Cairo/ Misr International University, Cairo, Egypt

Aim The aim of this study was to evaluate the mechanical behavior of M-wire, controlled memory (CM), R-phase files under bending and torsion conditions and compare it to the mechanical response of NiTi file with the same geometry using finite element analysis.

Summary Methods: A geometric model of HyFlex file size 25 and taper 0.06 was generated by micro-computed tomographic and Stereomicroscope scanning. The file FE model was built using Matlab and SolidWorks software. Four FE files models were constructed with different material properties, the data for the M-wire, CM, R-phase and NiTi alloys were obtained from the literature. The mechanical behavior of the different models under bending and torsion was analysed mathematically in SolidWorks software package. Results: Under bending conditions the maximum Von Misses stress value was related to NiTi file model (330 MPa), followed by M-wire (311 MPa),

then CM file model (191 MPa), while the least amount of stress value was related to R-phase file model (169 MPa). When torsion test was performed the maximum stress value was also related to NiTi file model (270 MPa), followed by M-wire (261 MPa), then CM file model (191 MPa), while the least amount of stress value was related to R-phase file model (188 MPa). Conclusions: metallurgical improvement of rotary files resulted in increasing the flexibility and the torsional resistance of these files.

Key Learning Points

- The type of the alloy used in manufacturing of rotary files affects its mechanical properties.
- R-phase file model showed the highest flexibility and torsional resistance among the tested groups.
- CM file model was more flexible and torsional resistance than M-wire file model.
- The least flexibility and torsional resistance were related to NiTi file model.

12:12

The use of Cryotherapy in Endodontics

*Al-Nahlawi TF, Hatab TA, Alrazak MA, Al-Abdullah A

Department of Operative Dentistry and Endodontics, Syrian Private University SPU, Damascus, Syrian Arab Republic

Aim The aim of this presentation is to describe the therapeutic effect of cryotherapy and to focus on its use in endodontics and the correct clinical procedure to use it to control post-endodontic pain.

Summary Cryotherapy is a relatively new form of treatment in which the body is briefly exposed to very cold temperatures in order to promote healing and other therapeutic results. It has been used for pain relief, such as sports injuries, runner's knee, tendonitis, sprains, arthritis pain...etc. In dentistry, cryotherapy has been used after intraoral surgical procedures, such as periodontal surgery, extractions, and implant placement, and was found to be effective in reducing swelling and pain. Recently, cryotherapy was used in endodontics, and it was found that deep dry cryotherapy of NiTi endodontic files can improve its cyclic fatigue resistance, reducing the potential file separation.

Another finding proved that intra-canal delivery of cold saline solution (2.5°C) with negative pressure irrigation reduced the external root surface temperature more than 10°C and suggested a possible effect on post endodontic pain reduction which was emphasized clinically by other newly published data. The technique of cryotherapy use to reduce post-endodontic pain consists of delivering the cold (2-4°C) saline irrigation using Endo Vac negative pressure device for a minimum period of 5 minutes after root canal instrumentation and irrigation protocol.

Key Learning Points

- Highlights the cryotherapy use in dentistry.
- Focus on cryotherapy use in endodontics.
- The new clinical findings of cryotherapy use to reduce post-endodontic pain.
- The suggested clinical protocol to reduce post-endodontic pain using cryotherapy concept.

14:30 to 16:00

14:30

The Effects of Autoclave Sterilization on the Cyclic Fatigue Resistance of ProTaper Universal, ProTaper Next and ProTaper Gold Nickel Titanium Instruments: A Laboratory Study

Özyürek T¹, Yılmaz K², *Uslu G¹

Department of Endodontics, ¹Ondokuz Mayıs University, ²Samsun Oral and Health Care Hospital, Samsun, Turkey

Aim To compare the cyclic fatigue resistances of ProTaper Universal, ProTaper Next, and ProTaper Gold and to evaluate the effects of autoclave sterilization on the cyclic fatigue resistance of these instruments both before and after the files were cycled.

Summary 80 ProTaper Universal, 80 ProTaper Next, and 80 ProTaper Gold were included to the present study. Each type of the instruments was randomly divided into four experimental groups: group 1, unsterilized instruments; group 2, pre-sterilized instruments subjected to 10 cycles of autoclave sterilization; group 3, instruments tested were sterilized at 25%, 50% and 75% of the mean cycles to failure, then cycled to failure; group 4, instruments cycled in the same manner as group 3 but without sterilization. Files were tested in a simulated canal with a curvature of 60° and a radius of 5 mm. Time to fracture was recorded, and the number of cycles to failure (NCF) for each instrument was obtained. The data was statistically analyzed by using one-way ANOVA and post hoc Tukey tests. ProTaper Gold had significantly higher cyclic fatigue resistance than ProTaper Universal and ProTaper Next in group 1 ($P < 0.05$). Autoclave sterilization significantly increased the NCF of ProTaper Next and ProTaper Gold ($P < 0.05$) in group 2. Furthermore, a significantly higher NCF was observed for ProTaper Next group 3 than ProTaper Next group 4 ($P < 0.05$). Also, significantly higher NCF was observed for ProTaper Gold group 2 than ProTaper Gold group 3 and 4 ($P < 0.05$).

Key Learning Points

- Comparison of cyclic fatigue resistance of ProTaper Universal, ProTaper Next, and ProTaper Gold.

- Effect of autoclave sterilization on cyclic fatigue resistance of ProTaper Universal, ProTaper Next, and ProTaper Gold.

14:48

Preflaring: The golden Key to success in Endodontics

*Mallet JP

Department of Endodontics, Toulouse University, Paris, France

Aim The use of nickel-titanium (NiTi) in Endodontics have been a tipping point for our specialty. Shaping techniques became easier, faster with more predictable outcome and less operational errors. Over more than 25 years the design of the shaping files was changing in order to decrease constraints and to improve cleaning ability. This evolution comprised the manufacturing tools, the file designs and the crystalline structure of the NITI alloy through proprietary thermo dynamical treatment processes. Nevertheless these improvements were stalled to a certain extent by anatomical discrepancies such as sharp, multiple curvatures or dentinal spurs at the canal entrance.

Summary These overhanging dentinal bridges will imply an unnecessary bend to the shaping file at its largest part near the handle and risk a file separation. However, the elimination of the dentinal spur at the entry of the canal (shilder triangle), is imperatively necessary to achieve a straight access to the most complicated part of the canal at the apex. To remove this constraint on the files and optimize the initial treatment, specific instruments have been developed. Their design benefits from technological advances in terms of asymmetry, section and heat treatment. A new preflaring file, selectively eliminating primary interferences is part of a minimally invasive Endodontics approach . It is the answer of several requirements of the Endodontic preparation: - elimination of first millimeters of initial mineral constraints and of a dense fibro-calcic or necrotic pulp, - centering ability of the shaping files in order to obtain a real working length and a adequate cleaning/filling of the Endodontic space. A new preflaring file for a safer and better treatment also is the answer to improve the initial endodontic treatment.

Key Learning Points

- Preflaring to give safer endodontics:
- Preflaring to give easier elimination of necrotic or dense fibro calcic pulp
- Preflaring to allow to eliminate the primary interferences
- Preflaring to steady a quick determination of working length

15:06

Evaluation of the efficacy of Hyflex CM rotary instruments used by undergraduate students

*Tzima ZD, Economides N, Gogos C

Department of Endodontology, Aristotle University of Thessaloniki, Dental School, Thessaloniki, Greece

Aim The aim of this prospective clinical research is to investigate the incidence of procedural errors during nonsurgical root canal treatment performed by undergraduate dental students (Department of Endodontology, Dental School, Aristotle University of Thessaloniki) with the use of a novel nickel-titanium rotary system (Hyflex CM, Coltene/ Whaledent, Cuyahoga Falls, OH).

Summary The instrumentation sequence was demonstrated on resin blocks by the investigator and thus far, one hundred and eighteen undergraduate students in their first year of clinical practice performed a root canal treatment on a molar (maxillary/ mandibular) using the single-length instrumentation sequence according to the manufacturer's recommendations. None of the participants had previous experience in rotary instrumentation. After the root canal treatment was completed the participants answered a questionnaire concerning the degree of difficulty during rotary instrumentation and obturation, their personal evaluation of the shaped and obturated canals and their perception of procedural errors. The periapical radiographs were taken with the paralleling technique and evaluated independently by two examiners. The overall incidence of separated instruments, strip perforation, apical perforation, root perforation, straightening and ledges was

0.8%, 0%, 4.4%, 2.3%, 5.5% and 29% respectively. On the basis of the results of this study, the incidence of procedural errors by the undergraduate students is relatively low.

Key Learning Points

- Performance and efficacy of Hyflex CM rotary system under clinical conditions.
- Incidence of procedural errors by novice practitioners.
- Comparison of the results among related prospective or retrospective clinical studies.

15:24

Apical extrusion of debris during root canal preparation: Is it clinically relevant?

*Munoz HR¹, Caviedes-Bucheli J²

¹*Postgraduate Endodontics Department, Universidad de San Carlos de Guatemala, Guatemala,*

²*Centro de Investigaciones Odontologicas, Pontificia Universidad Javeriana, Bogota, Colombia*

Aim To determine the clinical relevance of apical extrusion of debris during root canal preparation in terms of inflammation of the periodontal ligament and its influence on post-treatment pain incidence.

Summary There are several in vitro studies published dealing with the quantification of apical extrusion of debris during root canal preparation. All of them demonstrate that all instrumentation techniques (manual, rotary or reciprocating) generate debris extrusion in varying degrees, leading to the assumption that greater extrusion of debris would cause a more intense inflammatory response and therefore, post-treatment pain. However, few in vivo studies have been addressed to quantify the liberation of inflammatory mediators in the periodontal ligament after root canal preparation, making it difficult to establish a direct correlation between apical extrusion of debris and post-treatment pain. This presentation will discuss and compare scientific evidence both in vitro and in vivo to determine a possible relationship between apical extrusion of debris and periodontal ligament inflammation.

Key Learning Points

- Analyze the results and limitations of laboratory studies on apical extrusion of debris during root canal preparation.
- Correlate the results of in vitro and in vivo studies that quantify inflammatory mediators in periodontal ligament after root canal preparation.
- Establish under the best available evidence the relationship between apical extrusion of debris and the incidence of post-treatment pain.

15:42

Canal transportation and centering ability of six single file systems in severely curved canals using CBCT

*Del Valle Aleixandre B, Vilariño Rodriguez R, Ibañez Vicente P

Alfonso X University, Madrid, Spain

Aim To compare canal transportation and centering ability in severely curved canals of extracted teeth of six single file systems using CBCT (Cone Beam Computed Tomography)

Summary Methods: A total of 270 canals with completely formed apices and angles of curvature between 25°-50° degrees and short radii < 10mm were selected. The samples were scanned by CBCT and randomly divided into six groups (45 canals each group). The working length was set at 18mm. Three sections from each canal were analyzed. The first one was 3mm from the apical foramen, the second one 3mm below the coronal level (15mm from the apex) and the third one 9mm from the apex. The samples were instrumented with six single file systems: OneShape (MicroMega, Besancon, France), Reciproc R25 (VDW, Munich, Germany), Reciproc Blue R25 (VDW, Munich, Germany), WaveOne Gold primary (Dentsply Maillefer, Ballaigues, Switzerland), WaveOne primary (Dentsply Maillefer, Ballaigues, Switzerland) and Neoniti A1 (Neolix, Chatres-la-Forêt, France). All the samples were scanned under the same conditions as the initial scans after instrumentation. All data were recorded to get the canal transportation and centering ability by applying the following formula: $(x_1 - x_2) - (y_1 - y_2)$ for transportation and $(x_1 - x_2) / (y_1 - y_2)$ for centering

ability. The significance level was set at $P = .05$. Results: Canal transportation: There were significant differences in coronal third between Neoniti and Reciproc Blue versus WaveOne. ($p < 0.05$) Centering ability: There were significant differences between Neoniti and Reciproc Blue versus WaveOne in coronal third. There were significant differences between Neoniti and Reciproc Blue versus WaveOne and OneShape in middle third. ($p < 0.05$). Conclusions: Canal Transportation occurs in all single file systems, but it's significant in coronal third. Neoniti and Reciproc Blue show less canal transportation than WaveOne. Neoniti and Reciproc Blue have better Centering Ability than WaveOne in coronal third. Neoniti and Reciproc Blue have better Centering Ability than WaveOne and OneShape in middle third.

Key Learning Points

- The recent addition of single file systems in endodontic instrumentation reduces working time and risk of file fracture.
- Curved canals are difficult to negotiate due to the risk of ledges, zips, perforations and canal transportation.
- Knowledge about the use of these systems in these canals can reduce iatrogenic mistakes.

16:30 to 18:00

16:30

Evaluation of the dentinal defects after various root canal preparation techniques using a novel study design

*Kaval ME¹, Kaşıkçı Bilgi I¹, Kandemir Demirci G¹, Güneri P², Çalışkan MK¹

Departments of ¹Endodontics, ²Oral and Maxillofacial Radiology, School of Dentistry, Ege University, Izmir, Turkey

Aim To evaluate dentinal defects after root canal preparation with hand files, NiTi rotary and reciprocating systems using a novel study design.

Summary Sixty extracted maxillary central incisors with similar dimensions, mature apices and straight root canals were selected. Twelve teeth were left unprepared and other teeth were instrumented using one of the following instrumentation techniques: Hedström files using step-back technique, ProTaper Universal (PTU), Reciproc, and Twisted File Adaptive (TFA) Systems. The roots were sectioned perpendicularly and the slices were viewed under a stereomicroscope at a magnification of 25X and photographed. Specimens with dentinal defects were determined by two examiners who were blinded to the experimental groups. Additionally the severity of the cracks were evaluated quantitatively by using Java-based image processing program and were analysed by chi-square test, Kruskal-Wallis test, and Bonferroni corrected Mann–Whitney U-test ($P = 0.05$). The formation and severity of the cracks in Resiproc group were significantly higher compared to control and TF Adaptive groups ($P < 0.05$). Other comparisons between the tested instruments were not significant ($P > 0.05$).

Key Learning Points

- The quantitative evaluation of the presence and severity of the cracks revealed that TFA instruments can be used safely in preparation of the straight and large root canals.

- Assessment of the severity of the dentinal defects after root canal preparation could provide beneficial information for development of innovative instrument designs and kinematics to perform root canal instrumentation with minimum stress distribution on the root canal walls.

16:48

Effect of Number of Usage on Dentinal Defect Incidence of WaveOne Gold and Reciproc Nickel-Titanium Instruments

*Özyürek T¹, Yılmaz K², Uslu G¹

Department of Endodontics, ¹Ondokuz Mayıs University, ²Samsun Oral and Health Care Hospital, Samsun, Turkey

Aim To compare the incidences of dentinal defects caused by Reciproc and WaveOne Gold NiTi files during preparation of mandibular incisor teeth's root canals and to exam the effect of number of file usage on the incidence of dentinal defect.

Summary Two hundred seventy mandibular incisor teeth were randomly divided into 3 different groups as follows: the control group (n: 30), no root canal preparation was performed; the Reciproc group (n: 120), root canals were prepared with Reciproc R25 (25/.08); the WaveOne Gold group (n:120), root canals were prepared with WaveOne Gold Primary (25/.07). The specimens were sliced at 3, 6, and 9 mm from the apex with a low-speed saw under water-cooling. Microscopic pictures of the specimens were taken with the aid of LED and 2 independent evaluators assessed the images for the assessment of dentinal defects. The number of dentinal defects was recorded, and the chi-square test was used for statistical analysis. Total number of defects in Reciproc and WaveOne Gold groups increased following 1st, 2nd, 3rd, and 4th use in proportion to control group but the difference was not statistically significant ($P > 0.05$). There was no statistically significant difference among the WaveOne Gold, Reciproc and control groups in terms of dentinal defect formation ($P > 0.05$).

Key Learning Points

- The NiTi rotary root canal preparation causes different level of dentinal defect.
- The LED makes dentinal defect more visible compare to conventional method.
- The number of usage of WaveOne Gold and Reciproc NiTi instruments affect the files performance on dentinal defect formation.

17:06

Evaluation of NiTi endodontic instruments pressures in resin blocks by finite element analysis (FEA)

*Gibello U, Alovisi M, Pasqualini D, Marchetti A, Berutti E

Department of Surgical Sciences, Dental School, Endodontics, University of Turin, Turin, Italy

Aim Dynamic Finite Elements Analysis (FEA) has been proposed to virtually analyze and predict the cyclic fatigue resistance and the distribution of stresses of NiTi rotary instruments during shaping. The objective of this study is to evaluate the pressures against canal walls and the potential root canal centering ability of two different NiTi instruments in resin blocks by FEA.

Summary ProTaper Next X2 (PTN) and BioRace 3 (BR) were compared. File geometries were computer-replicated with a computer aided design (CAD) software (SolidWorks 2013, Dassault Systems, Waltham, Massachusetts, USA). The resin block's root canal geometry was scanned with microCT and imported with CAD software. CAD geometrical models were numerically discretized with a finite elements software (Altair Hypermesh 12.0, Troy, MI, USA). NiTi rotary instruments were virtually reproduced during rotation inside the root canals and a dynamic analysis of the pressures generated was achieved. The apical root canal portion was divided in 3 parts of 2 mm each (apical, medium and coronal). Each part was further divided in outside curvature (Up) and inside curvature (Down). The difference of pressures up/down in all parts was much lower for PTN X2 than BR3. Therefore, we can conclude that PTN X2 seemed more centered during shaping. FEA was demonstrated as a reliable virtual method to predict NiTi rotary instruments centering ability

Key Learning Points

- Dynamic Finite Elements Analysis has been proposed to virtually analyze and predict the cyclic fatigue resistance and the distribution of stresses of NiTi rotary instruments during shaping
- FEA was demonstrated as a reliable virtual method to predict NiTi rotary instruments centering ability

17:24

Vertical Load Generated with New File Systems during Canal Preparation

Jamleh A, *Alfadley A

Department of Restorative and Prosthetic Dental Sciences, King Saud bin Abdulaziz University for Health Sciences, Riyadh, Saudi Arabia

Aim To evaluate the magnitude of vertical load induced with WaveOne Gold (WOG), Reciproc Blue (RB), Hyflex EDM (HFEDM) and ProTaper Next (PTN) during canal preparation of extracted teeth.

Summary A total of sixty root canals were divided into four groups; WOG, RB, HFEDM and PTN (n=15). In the first three systems, the canals were prepared with file instrument size 25, inserted 3 times till the working length was reached. In PTN, the canals were prepared by using X1 inserted once to the WL and X2 inserted twice till reaching the WL. The vertical loads induced in the apical and coronal directions were recorded. The apically- and coronally-directed peak loads were used for analysis by using Kruskal-Wallis and Mann-Whitney tests. The statistical analyses were performed using SPSS software version 22 (SPSS Inc., Chicago, IL) at a confidence level of 95%. The overall pattern of the peak loads appeared to increase as the instruments distance to WL is reduced. During canal shaping in all groups, the apically and coronally directed peak loads ranged from 2.20-8.04 N and 1.30-2.59 N, respectively. There were significant differences in both peak loads among the tested systems at each instrumentation stage. PTN had the lowest apically directed peak loads during all three insertions. In fact, PTN generated significantly less amount of load than all tested systems during the third stage of instruments insertion. In terms of coronally directed peak loads, HFEDM tended to produce a lower amount of loads than all tested systems. Based on this

investigation, the use of a multi-file system had a favourable influence on the amount of loads developed during apical canal preparation. PTN system generated the lowest values of peak loads during apical canal preparation compared to WOG, RB, and HFEDM.

Key Learning Points

- Using only one file for the entire canal preparation would develop greater vertical loads, compared with canal preparation performed by using a multi-file system.

17:42

Influence of contracted endodontic cavities on root canal geometry: an in vitro study.

*Giuliano C, Alovisi M, Pasqualini D, Musso E, Berutti E

University of Turin, Surgical Sciences, Dental School, Endodontics, Turin, Italy

Aim Contracted endodontic cavities are considered to be an alternative to the traditional endodontic cavities in preserving more sound structure and maintain the tooth mechanical stability. However no data are available about the possible influence of coronal interferences on geometrical outcomes with NiTi rotary instruments. The aim of this study is to evaluate the influence of contracted endodontic cavities on the preservation of the original root canal anatomy on human first extracted mandibular molars.

Summary Thirty human extracted mandibular molar were selected with fully formed apexes and independent mesial canals. Samples were randomly assigned to the two shaping groups: WaveOne Gold (Dentsply Maillefer Ballaigues, Switzerland) with traditional endodontic access and WaveOne Gold with contracted endodontic cavities. Glide Path was executed with Proglider. Irrigation was performed with EDTA 10% and NaOCl 5%. Specimens were scanned pre and after the canal shaping to match canal volumes (SkyScan ,Bruker-microCT, 100 kV, 100 μ A, 15 μ m resolution). Afterward the images were analysed with NRecon and CTAn softwares (Bruker-microCT) to evaluate canal volumes and areas and centroid shift on cross action. Results were analyzed with 4 one-way ANOVA and Tukey's post-ok test ($p < 0,05$). WaveONE Gold with traditional endodontic access showed a better

preservation of the original root canal anatomy with less apical transportation; probably due to the absence of coronal interferences with consequent less number of pecking motions required to complete instrumentation.

Key Learning Points

- Contracted Endodontic Cavities predispose to higher transportation in the apical portion
- MicroCT is a valuable support to analyze shaping outcomes
- WaveOne Gold technique requires more pecking motion to reach full working length in the presence of coronal interferences

Friday 15th Hall 6 Meeting Studio 214 & 216

09:00 to 10:30

09:00

Composition and microstructure of MTA and Aureoseal Plus: XRF, EDS, XRD and FESEM evaluation.

Cianconi L, *Palopoli P, Mancini M

Department of Restorative Dentistry, Tor Vergata University, Rome, Italy

Aim Thanks to its hydrophilic nature, biocompatibility, and antibacterial activity MTA is useful in several clinical situations. However, it has a few drawbacks. This raised the interest to improve its physicochemical properties. Consequently, new MTA-based cements have been developed, such as Aureoseal Plus. The aim of this study was to assess the chemical composition and the phases' microstructure of Aureoseal Plus (OGNA), due to the lack of studies on it, and ProRoot MTA (Dentsply Tulsa Dental) and to compare their characteristics.

Summary X-Ray fluorescence (XRF) was used to determine the elements composition. The crystalline structure was analyzed quantitatively using x-ray diffraction (XRD). Powders morphology was evaluated using microscopes (SEM and FESEM). Elemental analysis was performed by energy dispersive x-ray (EDS). It is important to know the precise composition of such materials because any toxic component could lead to irritation and tissues necrosis. In fact it is claimed that ProRoot MTA is produced under segregated conditions to prevent any ingredients' contamination. Despite that, in our study, the semi-quantitative XRF analysis revealed the presence of heavy metal oxides. Furthermore, particles' size and shape influence the biocompatibility properties of materials, because they affect surface characteristics, and, consequently, cells adhesion and spreading. SEM analysis demonstrated that particles forming Aureoseal Plus are quite coarse, with different morphology and dimension ranging from 5 to 100 μm . ProRoot MTA powder's microstructure was more homogeneous and less coarse than Aureoseal Plus. The XRD spectra of the two cements reported the presence of dicalcium and tricalcium silicate, tricalcium aluminate, tetracalcium aluminoferrite, bismuth oxide and gypsum. The EDS analysis showed an increased presence of Ca, Si

and Bi in ProRoot MTA particles. Fe, Al, S and Mg are present only in traces in both cements. To conclude, Aureoseal Plus and ProRoot MTA are made by similar elements but in different concentrations. Differences in term of chemical composition and phases' microstructure may not have significant effects on the characteristics of the two cements. Moreover, It was interesting to notice how XRF analysis showed the presence of heavy metal oxides in both cements.

Key Learning Points

- ProRoot MTA, Aureoseal Plus, XRF, XRD, SEM, FESEM, EDS

09:18

Novel MTA-based cements: advances in physical, chemical and biological properties

*Marciano MA¹, Camilleri J², Lucateli RL³, Guimarães BM⁴, Duarte MAH⁴

¹*Department of Dentistry, Endodontics and Dental Materials, Piracicaba Dental School, State University of Campinas (UNICAMP), Piracicaba, SP, Brazil,* ²*Department of Restorative Dentistry, Faculty of Dental Surgery, University of Malta, Msida, Malta,* ³*Department of Surgery and Periodontics, Ribeirão Preto Dental School, University of São Paulo (USP), Ribeirão Preto, SP, Brazil,* ⁴*Department of Dentistry, Endodontics and Dental Materials, Dental School of Bauru, University of São Paulo (USP), Bauru, SP, Brazil*

Aim The last researches about physical, chemical and biological properties of recently introduced MTA-based cements are discussed.

Summary Since its development, mineral trioxide aggregate (MTA) has been widely used for different procedures in Endodontics. The ability to induce tissue repair and stimulate mineralization are some of the pleasing biological properties that support the extensive use of this cement. Several researches tested modifications in the composition of MTA-based cements in order to enhance the clinical performance. Novel formulations were introduced in the market claiming increased flowability. Important properties such as adequate radiopacity and setting time, colour stability,

alkaline pH, release of calcium ions and biocompatibility have to be considered in these new formulations.

Key Learning Points

- Novel MTA cements.
- Literature evidences.
- Physical, chemical and biological properties.

09:36

Factors effecting a standardised MTA preparation

*Basturk F

Department of Endodontics, Marmara University, Istanbul, Turkey

Aim The effect of proportioning, mixing techniques and direct or indirect ultrasonic activation during placement on various physical properties of MTA and MTA-like materials will be discussed.

Summary The manipulation of dental cements frequently involves the mixing of powder and liquid components, with the relative proportions being assessed by eye in an uncontrolled situation. The physical characteristics of hardened MTA depend on several factors including the water-to-powder ratio, the mixing liquid, the mixing and placement technique, the condensation pressure, and the relative humidity. The problems identified in clinical practice are caused mainly by the operator's imprecise proportions and mixing techniques when compared with the manufacturer's recommendations. Mixing techniques, ultrasonic application during placement, blood contamination and their effects on some physical properties like compressive strength, flexural strength, porosity, radioopacity, surface microhardness, pH and chemical reactions of MTA and MTA-like materials will be compared and discussed in this presentation. Although mechanical tests are unable to reflect the clinical situation, they can help detect the possible problems on different cement types and their interference with clinical behavior. Clinical applications of MTA and MTA-like materials on endodontically challenging cases will also be discussed.

Key Learning Points

- The manipulation of mineral trioxide aggregate is an operator-dependent process.
- Variations in proportioning, mixing and placement of MTA may affect the properties of the material.
- How to avoid the operator-induced variability will be discussed briefly.

09:54

Evaluation of The Effect of Mixing White MTA With Resin On Setting Time and Cytotoxicity

*Körklü S, Sazak Öveçoğlu H

Endodontics, Marmara University, Dentistry Faculty, İstanbul, Turkey

Aim MTA is a highly biocompatible material used as a root-end filler, pulp capping, perforation and resorption repair material. Despite the fact that MTA is an ideal material, the long setting time is disadvantageous. In this study, it was aimed to investigate the effect of mixing the white MTA with the 4-META / MMA-TBB resin on setting time and cytotoxicity.

Summary Material and Method: In our study, 3 groups were formed; Group 1 (MTA): White MTA was mixed with distilled water as standard. Group 2 (MTA/RESIN): White MTA was experimentally mixed with 4-META/MMA-TBB resin (Super-Bond C&B). Group 3 (RESIN): 4-META/MMA-TBB resin was mixed according to manufacturer's instructions. The setting times of the samples were determined with a Vicat tester. Cytotoxicity of the samples was evaluated by MTS test on Saos-2 cell line at 24, 72, 168 hour periods. Findings and Results: MTA/RESIN setting time was 11 times shorter than MTA and 2.5-3 times longer than RESIN. Assessment of cytotoxicity by MTS test on Saos-2 cell line; 24 hours: Cell viability rates, Control (+) > MTA ≥ MTA/RESIN > RESIN. Statistically significant differences were found only between control (+) and RESIN. 72 hours: Cell viability rates, Control (+) > MTA > MTA/RESIN > RESIN. Control (+) showed statistically significant differences between all groups and statistically significant difference was found between MTA and RESIN. 168 hours: Cell viability rates, MTA/RESIN > Control (+) ≥ MTA > RESIN. There was no statistically significant

difference between the groups. The setting time of the cement obtained with the mixture of white MTA and 4-META/MMA-TBB resin was considerably shorter than the setting time of the MTA-water mixture and the cytotoxic effect was found to be similar.

Key Learning Points • One of the main drawbacks of MTA is its prolonged setting time.

- 4-META/MMA-TBB resin appears to be a valid material to mix MTA with instead of water in terms of setting time and cytotoxicity.

10:12

Antimicrobial testing of Mineral Trioxide Aggregate (MTA). Are we doing it right?

*Farrugia C, Camilleri J

Department of Restorative Dentistry, Faculty of Dental Surgery, University of Malta, Imsida, Malta

Aim The aim of the presentation is to give an overview of currently used methods to assess antimicrobial properties of MTA and shed light on how clinically relevant these methodologies are, what their advantages and disadvantages are and how trends in antimicrobial testing are evolving in the literature.

Summary MTA and MTA like materials have been extensively tested for their antibacterial properties and it is generally accepted by the scientific community that MTA possesses antimicrobial properties. Antibacterial properties are important as they prevent infection in the area that the material is used and such properties can determine treatment success. Dental infections are generally caused by a biofilm, most frequently multispecies biofilms, which vary according to the infection site/environment of material placement. Infections can be present at the time of material placement, but can also develop after aging of the material. Despite these well accepted facts antimicrobial testing of MTA has been traditionally done against single bacterial species, using methods which test only immediate exposure to the particular microorganism without a biofilm challenge and using freshly mixed unaged materials in “in vitro” environments which are not similar to the environment of the varied clinical uses of the material. The most common methodologies

used for antimicrobial property assessment of MTA include the agar diffusion test and the direct contact test. The agar diffusion test's advantage is that it is very simple to use, but it heavily relies on the diffusion ability of the tested material and provides a testing environment which is far off from the clinical scenario. The direct contact test on the other hand only provides information on immediate contact of the material to the tested microorganism or microorganisms. Newer methodologies are emerging in the literature that test aged materials, materials in more clinical environments (such as contact with blood or dentine) and more recently testing using polymicrobial biofilms. Such tests provide us with more information on what to truly expect from MTA inside our patient's mouths.

Key Learning Points

- Importance of MTA's antimicrobial activity
- Methodologies used in the literature and their advantages and disadvantages
- Relevance of clinical applicability of testing done

11:00 to 12:30

11:00

Management of furcal perforation of mandibular molars with Biodentine

*Villarroel G¹, Rodriguez G¹, Guinovart J², Duran-Sindreu F¹

¹Master Of Endodontics, ²Master Of More, UIC, Barcelona, Spain

Aim Root canal perforation can be described as a mechanical, iatrogenic or pathologic communication between the root canal system and the external tooth surface. They are often a result of complications during endodontic or prosthodontic treatment, especially when preparing the post space. Factors reported to affect the prognosis of repair include location, size and previous microbial contamination. However, modern literature has found that successful treatment depends on accurate diagnosis and visualization of perforations as well as the use of biocompatible materials effective in sealing the perforation and preventing bacterial penetration, regardless of the location of perforation. With an overall success rate for perforation repair of about 81%. The aim of the presentation is to show step by step the clinical management of a furcation level perforation sealed with tricalcium silicate cement.

Summary A clinical case is presented of a patient that comes to the Odontological Clinic of the Universitat Internacional de Catalunya (UIC), referred to the Endodontic Master with a chief complain of discomfort on biting, in the area corresponding to the 3.7. Diagnostic tests, X-rays and CBCT are performed. The tooth was sensitive to percussion and probing depth was within normal limits. The presence of a periapical image in the distal root and presence of a post is evidenced. The pulpal diagnosis of the tooth 3.7 was previously treated and the periapical diagnosis was symptomatic apical periodontitis. The crown and post were removed and with the use of a microscope it is evidenced the presence of a perforation at furca level. The perforation was managed with biodentine, because it has good sealing ability, high compressive strength, and short setting time. After sealing of the perforation, root canal retreatment was performed using Profile

System and the obturation method was warm vertical compactation, reconstruction with endocrown and case follow up at 3 and 6 months were performed.

Key Learning Points

- Factors reported to affect the prognosis of perforations include location, size and previous microbial contamination.
- Know how the prognosis have changed since the introduction of MTA.
- The overall success rate for perforation repair is reported to be about 81%.
- Biodentine placement on furcal perforation.

11:18

Open, randomized clinical trial evaluating the efficacy of a tricalcium silicate-based endodontic filling material (BioRootRCS).

*Riera B¹, Roze J¹, Zanini M¹, Glikpo M¹, Flouriot AC¹, Rilliard F², Valot Salengro AC³, Mallet A³, Simon SRJ¹

¹Endodontics and Restorative Department, Paris Diderot University, Paris, ²Endodontics and restorative department, Hôpital Pitié Salpêtrière, Paris, ³Scientific Affairs, Septodont SAS, Saint Maur des Fossés, France

Aim To evaluate the clinical and radiographic outcomes at 24 months after treatment of a “single cone technique” using a tricalcium silicate-based material, BioRootTMRCS® (Septodont, France) as a filling material.

Summary Methods: A randomized clinical trial (NCT01728532) was conducted at the Pitié Salpêtrière Hospital (Paris-France) including vital and non-vital teeth. 23 patients were randomly dispatched into Group BioRoot (Single cone + BioRootTM RCS) (n=16) or Group WVC (Warm Vertical compaction of gutta percha + Pulp Canal Sealer®) (n=7). Patients were followed-up at 24 months after treatment. The success rate was defined as no pain and absence or decreased size of apical lesions associated with the fulfilment of Strindberg’s criteria. Results: At a 24 months follow-up, the

success rate was of 83.3% in BioRoot™ RCS Group versus 66.7 % of the WVC Group, regardless of the presence of an initial lesion. Strindberg criteria were fulfilled at 91.6%. No adverse events related to the products were reported during the study.

Key Learning Points

- This study shows no significant differences between the two techniques for root canal filling at a 24-months follow-up.
- The use of silicate-based root canal filling material with a single cone of gutta percha may represent an appropriate and safe technique for filling disinfected root canals.

11:36

Indirect pulp treatment vs. Biodentine pulpotomy in deciduous molars with extensive proximal carious lesions

*Hrynyshyn OB

Department of Pediatric Dentistry, Lviv National Medical University named after Danylo Halytsky, Lviv, Ukraine

Aim To assess the outcome of two methods (indirect pulp capping and Biodentine pulpotomy) of extensive proximal carious lesions management.

Summary Ninety deciduous molars with extensive carious lesions approaching the pulp on proximal surfaces in 81 children from 5 to 7 years old were included; children were randomly allocated to the groups with preliminary informed consent from the parents. Forty-six molars were treated with partial removal of dentin and indirect pulp capping (IPC). Forty-four molars were treated with complete dentin excavation and procedure of Biodentine pulpotomy. After local anesthesia, each tooth was isolated with rubber dam and disinfected with 5% sodium hypochlorite before caries excavation. Subsequently, partial dentin removal and indirect pulp capping with calcium hydroxide in group A or complete excavation of dentin and Biodentine complete pulpotomy in group B was performed. Clinical and radiographic evaluation was completed at 6, 12 and 24 months. Eighty cases

in 77 children were available for recall, 41 teeth in group of indirect pulp capping and 39 teeth in pulpotomy group. Clinical and radiographic success rate in group A ranged from 90.24% and 85.37 % at 12 months to 80.48 % and 75.62 % at 24 months. Four teeth presented symptomatic irreversible pulpitis, one and five teeth were associated with symptomatic and asymptomatic apical periodontitis. Clinical and radiographic success rate in group B ranged from 100% and 97.44% at 12 months to 97.44% and 92.32% at 24 months ($p>0.05$). Three cases of internal root resorption occurred during two-year follow up in group B. Overall radiographic appearance of normal alveolar bone structure in 24 months was seen in 92.32% of the cases in Biodentine pulpotomy group and 75.62% in the indirect pulp capping group ($p<0.05$).

Key Learning Points

- Biodentine pulpotomy demonstrated higher successful rate in comparison with IPC for the management of extensive carious lesions located on proximal surface of deciduous teeth.

11:54

Prognostic factors in direct pulp capping of permanent mature teeth using mineral trioxide aggregate: A clinical study

Çalışkan MK, *Köseler İ

Department of Endodontology, Ege University Faculty of Dentistry, Bornova/Izmir, Turkey

Aim To evaluate the influence of various predictors on pulp healing after direct pulp capping using mineral trioxide aggregate

Summary Vital pulp therapy, namely stepwise excavation, indirect or direct pulp capping (DPC), and partial/full pulpotomy, is a procedure in which cariously or traumatically exposed dental pulp is covered with a protective dressing or cement. The specific aim of VPT is to preserve and maintain complete/partial coronal/radicular pulp vitality and stimulate the formation of a tertiary dentinal bridge. Direct pulp capping was undertaken in 169 vital mature asymptomatic permanent teeth with cariously exposed pulp tissue using mineral trioxide aggregate. The effects of clinical variables such

as patients' ages and genders, tooth location and type, number, size and site of pulp exposure, the degree of pulpal bleeding, type of restoration, and recall time on the treatment outcome of DPC was evaluated clinically and radiographically. A total of 140 capped teeth were available for follow-up, with an overall recall rate of 83%. Of these, 116 were classified as successes (83%) and 24 as failures (17%). None of the evaluated clinical variables significantly affected the outcome of direct pulp capping treatment ($p > 0.05$).

Key Learning Points

- DPC is a treatment option for teeth with carious-exposed pulp and it may be considered a realistic alternative therapy to root canal treatment.
- DPC using mineral trioxide aggregate after pulp exposure during excavation of deep caries could maintain pulp vitality in permanent teeth and might improve the prognosis of teeth after pulp exposure.

12:12

Effect of different gutta-percha solvents on push-out bond strength of tricalcium silicate based cements

Özçelik B, *Arıker İ

Department of Endodontics, Hacettepe University, Faculty of Dentistry, Ankara, Turkey

Aim The aim of this study was to evaluate the effect of three different gutta percha solvents and their different application times on the push-out bond strengths of ProRoot MTA and Biodentine.

Summary 80 single rooted mandibular premolar teeth with no cracks, fractures and resorption on the root surfaces were used. After removal of crowns, root canals were prepared by using ProTaper rotary nickel titanium system and then a standard diameter was obtained with peeso-reamers. Following preparation of root canals, two hundred and forty 1-mm-thick midroot sections were obtained. These dentin slices were divided into two groups according to the filling material. Group 1: ProRoot MTA, Group 2: Biodentine. These groups were randomly assigned into 3 different subgroups

according to gutta-percha solvents. In these three subgroups, randomly assigned dentin slices were treated with the following solvents: Chloroform, eucalyptol and orange oil. Within each subgroup, the specimens were further divided into two and solvents were applied for either 5 or 10 minutes (min). Thereafter, solvents were removed by irrigating with distilled water and the slices were dried with air spray. The root canal spaces of each slice were filled either with ProRoot MTA or Biodentine according to their groups. The push-out bond strength values were measured after 21 days. Data were analyzed using three way ANOVA with Bonferroni correction $p = 0.05$. The solvents and their application times didn't statistically affect the bond strength of ProRoot MTA and Biodentine but for the subgroup treated with orange oil for 10 min, the push out bond strength of Biodentine was reduced significantly ($p < 0.05$).

Key Learning Points

- Different calcium carbonate ratios in ProRoot MTA and Biodentine may effect the interaction between the cement and solvent remnants. Although solvents were removed with distilled water and paper points in this study, there can be residual solvent in dentine tubules which may effect the adhesion.
- D-limonene, the basic content of Orange oil, can solve calcium carbonate and this has been shown in different medical studies which are about calcium carbonate gallstones and their therapy.

14:30 to 16:00

14:30

Evaluation of micro-hardness and flexural strength values of young and old crown dentine after different concentrated EDTA solutions

*Pedersen ND, Uzunoglu E, Doğan Buzoğlu H

Department of Endodontics, Hacettepe University, Faculty of Dentistry, Ankara, Turkey

Aim To investigate micro-hardness and flexural strength values changes after application of different concentrated ethylenediamine tetra-acetic acid (EDTA) solutions on young and old crown dentine.

Summary 48-young and 48-old plano-parallel dentine bars were obtained from the crowns of patients with average age of 16.7 and 65.4, respectively. 6 test groups (G) (n=8) were formed from old and young dentine bars as follows: G1: 5% EDTA for 1 min following 2.5% NaOCl for 20 min, G2: 15% EDTA for 1 min following 2.5% NaOCl for 20 min, G3: 2.5% NaOCl for 20 min, G4: 5% EDTA for 1 min, G5: 15% EDTA for 1 min and G6: saline for 20 min as control. Micro-hardness values (MV) of each sample was measured with Vickers testing machine pre- and post-treatment. Using a microhardness tester (HMV, Shimadzu, Japan), each dentine specimen was impressed with indentation load of 300 g for 10 seconds using a Vickers indenter. Specimens were also submitted to flexural strength (FS) analysis (a three-point bend test) via universal testing machine post-treatment. Results were statistically analysed with repeated measures of Anova and Bonferroni post-hoc tests ($p=0.05$). MV of young samples were significantly lower than old samples in both measurements ($p<0.05$ for both). Significant decrease was observed post-treatment MV in G1, G2 and G3; compared to pre-treatment MV of old samples ($p<0.05$ for all). Comparison of post-treated old samples revealed that G5 showed statistically higher MV than G1 and G3 ($p<0.05$). FS values of young samples were statistically higher than old samples in G3 and G6 ($p<0.05$). Intra-group comparison revealed that G6 showed statistically higher FS values compared to G1 and G2 in young samples ($p<0.05$ for both).

Key Learning Points

- Aging has a significant effect on micro-hardness and flexural strength values of crown dentine.
- No significant differences were found between MV/FS values of old and young samples; which were exposed to only 5% EDTA or 15% EDTA.
- NaOCl combined with either 5% EDTA or 15% EDTA solutions caused decrease in MV of old crown dentine and FS values of young crown dentine.

14:48

Effect of Calcium Hypochlorite Irrigation on the Fracture Resistance of Root Canal-treated Teeth.

*Askerbeyli Ors S, Kucukkaya Eren S, Aksel H, Serper A

Department of Endodontics, Hacettepe University, Ankara, Turkey

Aim To evaluate whether the use of calcium hypochlorite [Ca(OCl)₂] solution with or without surfactant ingredient influences the fracture resistance of root canal-treated teeth when compared with sodium hypochlorite (NaOCl) counterpart.

Summary Sixty-human single-rooted mandibular premolars were selected and the root lengths were standardised to 15 mm. Ten roots were assigned as negative controls and did not receive any treatment. The root canals were prepared using rotary nickel-titanium files up to apical size of #40. The specimens were randomly divided into five groups according to the irrigation solutions used (n=10): saline (positive control), 5 % NaOCl, 5 % NaOCl + 0.1 % cetrimide, 5 % Ca(OCl)₂, 5 % Ca(OCl)₂ + 0.1 % cetrimide. In the experimental groups, final irrigation was performed with 3 ml of 17% EDTA . Following obturation of the root canals, the specimens were stored at 37°C and 100% humidity for a week. Each specimen was then subjected to fracture testing using a universal testing machine at a crosshead speed of 1 mm/min until the root fractured. The data were statistically analysed using one-way ANOVA test and Tukey post-hoc test ($\alpha=0.05$). There was no significant difference among all experimental groups ($p>0.05$). Ca(OCl)₂ did not alter the vertical fracture resistance of root canal-treated teeth compared with NaOCl. The use of surfactant in combination with Ca(OCl)₂ or NaOCl also did not affect the vertical root fracture resistance ($p>0.05$).

Key Learning Points

- Ca(OCl)₂ irrigation with or without surfactant ingredient could be a viable alternative to NaOCl without any harmful effect on the vertical fracture resistance of root canal-treated teeth.

15:06

Chlorhexidine in Endodontics: When the safety ends and the risky begins?

*Palacios SE, Acevedo NP, Ramirez OM, Munoz HR

Postgraduate Endodontics Department, Universidad de San Carlos de Guatemala, Guatemala

Aim To review the available evidence regarding the safety of chlorhexidine as irrigant agent in endodontic procedures.

Summary Chlorhexidine (CHX) is a widely used substance in oral care therapies and endodontics. During recent years, attention has been set on para-chloroaniline (PCA), a degradation product of CHX that has been related to methemoglobin and carcinogenic effects in humans and animals. Some evidence suggests the use of alcohol between sodium hypochlorite (NaOCl) and CHX to prevent the formation of PCA, but on the other hand, other authors suggest that PCA could be formed even without mixing CHX and NaOCl, and therefore its use should be avoided. This lecture will review the current available evidence regarding the safety of CHX use in endodontics and dentistry in order to determine the risks of its current clinical applications.

Key Learning Points

- Discuss the benefits of the current applications of chlorhexidine in endodontics.
- Analyze the mechanisms of chlorhexidine degradation when used as endodontic irrigant and in other oral care therapies.
- Evaluate the risks for patient health due to chlorhexidine use during endodontic treatments.

15:24

The XP-Endo Finisher: survey of the literature and evaluation of the experimental removal of calcium hydroxide paste out of the apical third.

*Hamdan R, Pinchon D, Georgelin-Gurgel M, Diemer F

Department of Endodontics, Paul Sabatier University, Toulouse, France

Aim To summarize the study-outcomes on the PubMed search-engine with the keywords (XP-Endo Finisher).

Summary The XP-Endo-Finisher (FKG-Dentaire-SA, La-Chaux-de-Fonds, Switzerland) is a cleaning-instrument with an atypical shape. Due to its curved-tip, the instrument has an improved contact with the canal-walls for an optimal cleaning while preserving the dentin. Several studies have focused on assessing the cleaning efficacy of this instrument. A search with the keyword "XP-Endo Finisher" on the PubMed search-engine resulted in 10 published studies. The main findings of these studies were: (1)The XP-Endo-Finisher removed significantly more biofilm than the Passive-Ultrasonic-Irrigation (PUI) and may help removing the biofilm from hard-to-reach areas in the root-canal system. (2)It has an equivalent efficacy to the Endo-Activator for cleaning the debris and the smear-layer from curved canals. (3)In isthmus-area, XP-Endo-Finisher was as efficient as PUI in prohibiting the bacterial effectiveness. (4)Furthermore, adding XP-Endo-Finisher to rotary-retreatment-files improved significantly the removal of filling-materials. (5)It displayed similar effectiveness comparing to PUI when used to remove antibiotic-pastes, but it was less efficient than Laser-activated-irrigation. (6)Moreover, its capacity for eradicating calcium-hydroxide dressing ($\text{Ca}[\text{OH}]_2$) from artificial-grooves and simulated-internal-resorptions was found to be comparable to PUI. However, the capacity of XP-Endo-Finisher to remove $\text{Ca}[\text{OH}]_2$ from the apical third was not yet evaluated. We decided to assess this capacity by comparing PUI and XP-Endo-Finisher. Sixty mandibular-incisors were chosen and divided into two groups: G1:XP(n=30), G2:PUI(n=30). Canals were shaped using the BT-Race-files (35,0.04). A dressing of $\text{Ca}[\text{OH}]_2$ (Produits-Dentaires-SA, Vevey, Switzerland) was placed. Specimens were conserved during one week in 37°C and 100%-humidity. $\text{Ca}[\text{OH}]_2$ removal consisted of three repeated one-minute-cycles of activation for each instrument

while using similar irrigation volumes. Samples were split longitudinally. Photos of the apical-thirds were taken using an optic-microscope at 16X-magnification and were given random-names. Two examiners scored the photos: (0,1,2,3,4) when Ca[OH]₂ was covering (0%,<10%,<50%,>50%,100%) respectively of the surface of the apical-third. The results were compared using the Fisher-test with p<0.05. XP-Endo-Finisher showed superiority over PUI for removing Ca[OH]₂ from the apical-third of the root-canal.

Key Learning Points

- All study-outcomes approve the efficacy of XP-Endo-Finisher in enhancing the root-canal cleaning.
- The XP-Endo-Finisher is more efficient than PUI in removing Ca[OH]₂ from the apical-third.

15:42

Determination of Effective Concentration of Etidronic Acid (HEBP) and Investigation of its

Antimicrobial Activity

*Erik CE¹, Maden M¹, Celik G¹, Tuncer Y²

Department of ¹Endodontics, ²Engineering, Suleyman Demirel University, Faculty of Food Engineering, Isparta, Turkey

Aim The aim of the study was to determine the antimicrobial effects of different concentrations of Etidronic Acid (HEBP) on biofilm composed of Enterococcus faecalis, Candida albicans or Pseudomonas aeruginosa.

Summary One-hundred eighty four extracted single-rooted teeth were collected. The roots were biomechanically prepared with rotary instruments that were up to F4 in apical size, with 2 mL of 2.5% NaOCl irrigation between each file. The outer surfaces of the root samples were sealed with cyanoacrylate as a closed-ended system to prevent bacterial leakage. Following the cyanoacrylate setting, the root samples were vertically mounted into impression material and sterilized using an autoclave at 121°C for 25 min. The teeth were incubated for 21 days with E. faecalis, C. albicans, and P. aeruginosa. Samples were divided into 3 main groups according to the type of microorganism.

Biofilm formations of *C.albicans*, *E. faecalis*, and *P. aeruginosa* were confirmed at the apical, middle, and coronal levels on the dentinal walls in the SEM images (three teeth per group). The remaining teeth were divided into five sub-groups (distilled water, %5, %7, %9, and %18) depending on the concentration of the final irrigation solution. The root canals were filled with sterile saline, and the samples were performed immediately using an F4-size sterile paper point and using an F4-size manual file. The counts of the bacterial or fungal survivors in the root canals were determined using the direct plating method. It was shown that 9% and 18% HEBP concentrations were statistically more effective than other concentrations of *E. faecalis* and *P. aeruginosa* ($P < 0.01$). Furthermore, it was also found that 18% HEBP concentration was statistically more effective than other concentrations on *C. albicans* ($P < 0,01$). The efficiency of 5%HEBP concentration was statistically significantly higher as compared to the control group of *P. aeruginosa* ($P < 0.01$).

Key Learning Points

- 9% and 18% HEBP concentrations were statistically more effective than other concentrations on *E. faecalis* and *P. aeruginosa*
- 18% HEBP concentration was statistically more effective than other concentrations on *C. albicans*
- We concluded that the antibacterial efficiency of HEBP is affected by its different concentrations against various biofilm

16:30 to 18:00

16:30

Evaluation of the Effects of Different Chelation Agents on Adhesion of Two Root Canal Sealers

*Kaki GD¹, Genç Şen Ö², Kaki B³

¹Department of Endodontics, Uşak University Dentistry Faculty, Uşak, ²Department of Endodontics, Yüzüncü Yıl University, Dentistry Faculty, Van, ³Department of Econometry, Uşak University, Faculty of Economics and Administrative Sciences, Uşak, Turkey

Aim The aim of this study was to evaluate the alterations on the root canal dentin after irrigation with EDTA, HEBP, Chitosan and to determine the push-out bond strengths of the different root canal sealers to altered dentin surfaces.

Summary This study protocol was approved by the Ethics Committee of the Yüzüncü Yıl University Faculty of Medicine, Van, Turkey (date: 18.04.2014/ Process no.1). Crowns of 70 maxillary single rooted teeth were removed to obtain a standardized length of 15 mm. The canals were instrumented with rotary files (Mtwo, WDW, Germany) using the step back technique. Master apical file determined as #40. 8 subgroups were determined based on the chelation agent and root canal sealer material used (%17 EDTA, %18 HEPB, %0.2 Chitosan, distilled water, AH Plus(Dentsply, Germany, Well Root ST(Innovative Bioceramics, Vancouver, Canada). After irrigation 3 ml of irrigant used in 1 minute, root canals were obturated with gutta percha(Diament, Chongchong Buk Do, Korea) using lateral compaction technical. Three slices in one mm thickness were cut from all the root thirds of each tooth and subjected to push-out test. Datas were taken in Newton and converted to MPa using the appropriate formula. Datas was analyzed using one way ANOVA and Duncan multiple comparison test at $\alpha=0.05$ level. Failure mode were examined under X40 magnification with light microscope (Mitutoyo, Japan). SEM photographs were taken from 3 part of each root dentin as coronal, middle and apical. Groups that used WRST exhibited significantly higher push-out bond strength values in all subgroups independent from the irrigant used (ANOVA, $p<0.05$). Group that applied % 17 EDTA showed higher pushout bond strength than other AHPlus subgroups.

Key Learning Points

- EDTA improves the pushout bond strength of AHPlus.
- WRST root canal sealer has the highest pushout bond strength and does not depend on the irrigant used.

16:48

Influence of gutta-percha backfilling on the fracture resistance of simulated immature teeth performed apical plug with Biodentine and ProRoot MTA

Barut G¹, Işık V², *Candaner Y³, Ovecoglu HS³, Ersev HS², Haznedaroglu F²

Department of Endodontics, ¹Yeditepe University, Faculty of Dentistry, ²Istanbul University, Faculty of Dentistry, ³Marmara University, Faculty of Dentistry, İstanbul, Turkey

Aim To evaluate the fracture resistance of simulated immature teeth that had been backfilled with gutta-percha after using Biodentine and ProRoot MTA as the apical plug materials.

Summary Methodology Sixty human maxillary incisors were divided into four groups (n=15). The root of each tooth was standardized to a length of 12 mm as measured from the apex to the cemento-enamel junction by cutting off the root end using a low speed diamond saw. Root canals were instrumented to ISO size 60 K file (Dentsply Maillefer). In all groups, an open apex was prepared until a size #6 Peeso could be passed 1 mm beyond the apex to simulate immature teeth. Groups received the followings: Group 1: 5 mm of ProRoot MTA (Dentsply Tulsa Dental, USA) plug as an apical barrier + backfilled with gutta-percha Group 2: filled with ProRoot MTA to cemento-enamel junction Group 3: 5 mm of Biodentine (Septodont, France) plug as an apical barrier + backfilled with gutta-percha Group 4: filled with Biodentine to cemento-enamel junction. A load was applied at an angle of 45 from the palatal surface using universal testing machine (Model 3345, Instron Corp., Norwood, MA, USA) until the fracture. Data analysis was conducted using the NCSS 2007 Statistical Software (Utah, USA). The analysis of variance and Tukey multiple comparison tests were used to evaluate the results. Significance level was set at P<0.05. Results There was statistically significant

difference between the fracture resistance values of all groups ($P=0.0001$). Group 1 and group 2 showed higher fracture resistance than group 3 and group 4 ($P=0.0001$). The difference between the other groups was not statistically significant ($P>0.05$).

Key Learning Points

- The backfilling with gutta-percha does not affect the fracture resistance.
- Using MTA both as an apical plug and full length filling increase the fracture resistance of immature teeth.

17:06

The effect of various back-filling techniques on the fracture resistance of simulated perforating internal resorption cavities repaired with MTA

*Aktemur Türker S¹, Tek V¹, Uzunoglu E², Deniz Sungur D²

¹Department of Endodontics, Bülent Ecevit University, Faculty of Dentistry, Zonguldak, ²Department of Endodontics, Hacettepe University, Faculty of Dentistry, Ankara, Turkey

Aim Reinforcement of teeth with perforated internal resorption may be essential to reduce the risk of root fracture. This study assessed the effect of various back-filling techniques on the fracture resistance of simulated perforated internal resorption cavities repaired with mineral trioxisilicate aggregate (MTA).

Summary Decoronated 48 single-rooted mandibular premolar teeth were standardized to 12 mm in length. Samples were divided into 2 control groups and 3 experimental groups according to the back-filling. 42 roots (36 for experimental group and 6 for negative control group (NC)) were prepared with ProTaper Next instruments up to file X3 and the standardized internal resorption cavities were prepared with burs. The apical 4 mm of the 36 root canals were obturated with single cone technique with gutta-percha and AH Plus sealer. Simulated internal cavities of the experimental groups were repaired with MTA. Back-fillings of experimental groups were performed as follows: Group MTA; Group FRC, [Fiber-reinforced composite (FRC) posts (EverStick) + self adhesive resin

cement]; Group GP, (AH Plus sealer + warm vertical compaction of gutta-percha). Control groups were designed as follows: Group NC, instrumented, but neither repaired nor obturated roots; Group PC (Positive Control), intact roots (n=6). The apical 4 mm of roots was embedded along the long axis in self-curing acrylic blocks, with 8 mm of each root exposed. The specimens were then mounted in a universal testing machine (Lloyd LRX; Lloyd Instruments, Fareham, UK). A custom stainless steel loading fixture with a round tip was centered over the canal opening, and a compressive force was applied at a crosshead speed of 1 mm/min until a fracture occurred. The forces when the fracture occurred were saved and statistically analysed with one-way analysis of variance and Bonferroni tests at $p=0.05$. The mean fracture values of PC were significantly higher than groups FRC, GP, and NC ($p < 0.05$) except group MTA ($p > 0.05$). Group MTA revealed insignificantly higher fracture resistance compared to FRC and GP groups.

Key Learning Points

- Internal resorption cavities weaken the tooth structure and reduce the fracture resistance. MTA may be a preferable material for the back-filling of the roots with perforated internal resorptions.

17:24

Bioceramics: new prospective and clinical uses

*Carpegna G, Alovisi M, Pasqualini D, Berutti E

Department of Endodontics, School of Dentistry, University of Turin, Turin, Italy

Aim This literature review aims to compare the current scientific evidence available on bioceramics compared with other sealers commonly used in endodontics; furthermore to give some indications about use, predicability, and future applications of this new material.

Summary The introduction of modern less invasive endodontic protocols leads to the invention of new more performant obturation techniques. Bioceramics have been used for many years in different medical fields; but their introduction in endodontics is relatively recent. Medline search using the following key words: "bioceramic" lead to 747 articles since 1972; "bioceramics AND

endodontics” to 25 articles starting from 2011, “bioceramic AND endodontic sealer” to 20 articles starting from 2011, “bioceramic sealer” to 40 articles starting from 2011. Bioceramics are new water-based sealer, composed of biocompatible ceramic nano-particles that are claimed to promote cementogenesis and to form a hermetic seal inside the root canal. Many studies compare Bioceramic’s sealing ability with MTA, proving similar ability in preventing leakage. Other studies tested chemical and biological properties such as Radiopacity, pH and Ca²⁺ release. The main issue with bioceramic is retreatment’s possibility: there aren’t many studies about this topic. The studies analyzed showed that bioceramic do not fulfill all the characteristic of an ideal sealer. Biocompatibility and biomineralization properties suggest to use it for other purposes such as direct pulp capping or retrograde obturation.

Key Learning Points

- Bioceramic’s advantages and disadvantages
- Current scientific evidence and future perspectives of bioceramics

17:42

Effect of Ultrasonic Activation on the Penetration of Calcium Silicate-Based Cements Using an Open Apex Model

*Ayhan E¹, Aksel H¹, Purali N², Nagas E¹

¹Department of Endodontics, Hacettepe University, Faculty of Dentistry, ²Department of Biophysics, Hacettepe University, Faculty of Medicine, Ankara, Turkey

Aim To evaluate the tubular penetration depth areas of MTA, NeoMTA and Biodentine placed by either manual condensation or manual condensation with indirect ultrasonic activation using an open apex model.

Summary Standardized divergent open apex models were created using palatal roots of sixty human maxillary molars and divided into 6 groups (n = 10) according to the used cements and activation methods: MTA-manual condensation, NeoMTA-manual condensation, Biodentine-manual

condensation, MTA-ultrasonic activation, NeoMTA-ultrasonic activation, Biodentine-ultrasonic activation. For the measurement of penetration, the cements were mixed with 0.1% Rhodamin B and 6- mm apical portions of each root canal were obturated in an orthograde direction. The roots were embedded into acrylic blocks, and 1-mm-thick sections were obtained at 3 mm from the apex. The root sections were mounted onto glass slides and scanned under a confocal laser scanning microscope (CLSM) for three-dimensional evaluation and the images of the sections were captured using a digital camera mounted on a stereomicroscope at 24x magnification for two-dimensional evaluation. The tubular penetration areas were calculated using LSM Image Examiner Software for CLSM or using ImageJ software for stereomicroscopic analysis. The percentage of sealer penetration area was calculated for each group. The data were analyzed using two-way analysis of variance (ANOVA) with Bonferroni correction ($\alpha=0.05$). CLSM analysis showed that there were no significant differences among the experimental groups while stereomicroscopic analysis showed significant differences between the ultrasonic activation of MTA or NeoMTA and Biodentine-ultrasonic activation group ($p<0.05$). Both analyses showed that ultrasonic activation did not increase the tubular penetration of MTA, NeoMTA or Biodentine as compared to manual condensation of each material ($p>0.05$). Within the limitations of this study, MTA, NeoMTA and Biodentine showed similar tubular penetration when manual condensation was used. Ultrasonic activation of these cements had no effect on tubular penetration of each material as compared to the manual condensation counterparts. Three-dimensional evaluation of the specimens using CLSM seems more favorable than two-dimensional evaluation using stereomicroscope.

Key Learning Points

- This study indicated the penetration of calcium silicate–based cements into the dentinal tubules by using different placement techniques.
- Ultrasonic activation did not improve the penetration of the calcium silicate–based cements.

Saturday 16th Hall 6 Meeting Studio 214 & 216

09:00 to 10:30

09:00

Cementation of a fibre post with a fast-setting calcium silicate-based cement

*Irmak Ö¹, Orhan EO², Mumcu E³

Departments of ¹Restorative Dentistry, ²Endodontics, ³Prosthetic Dentistry, Faculty of Dentistry, Eskişehir Osmangazi University, Eskişehir, Turkey

Aim This report suggests a technique for cementation of a fibre post (Exacto Fiber Post, Angelus, Brazil) with a fast-setting calcium silicate-based cement (RetroMTA, BioMTA, Korea), as an alternative to resin-based cementation, to restore root-filled teeth having insufficient coronal structure and overly prepared root canal.

Summary Fibre posts are widely used for restoration of root-filled teeth. During post-space preparation, root canal is enlarged with a drill of corresponding size of the post to be cemented. In the ideal case, there would be a minimum discrepancy between the prepared post-space and the fiber post. However, in teeth with elliptical shaped, overly prepared or over-flared root canals there could be a mismatch between the prepared post-space and the post. This discrepancy would have to be compensated during cementation by excessively thick layer of a resin cement. Main disadvantages of resin cements are polymerization shrinkage, and insufficient polymerization in the apical region of the root; which may lead to failures. Fast-setting calcium silicate-based cements are biocompatible and bioactive materials which are indicated for vital pulp therapy, retrograde filling and perforation repair and can be used as dentin replacement. A fast-setting calcium silicate-based cement (RetroMTA, BioMTA, Korea) was recently introduced into market. Viscosity of this material right after mixing, allows delivery of the cement into the prepared post-space easily. Its initial setting time is 150 s. After its final setting, which is 6 h, it has a volumetric expansion of 0.09%. This relatively higher volumetric stability compared to resin-based cements, and its self-setting characteristic might be advantageous for cementation of fiber posts into the root canal, especially in

circumstances where there is more mismatch between the post and the prepared root dentin. One advantage of calcium silicate-based cements is their ability to induce a chemical bond with dentin and formation of apatite-like structure, which may be of benefit for longevity of post-core restorations.

Key Learning Points

- Use of a fast-setting calcium-silicate based cement for cementation of fiber posts can overcome polymerization related problems associated with resin cements.
- Secondary monoblock obtained via calcium silicate-based cements could be more reliable than the monoblock obtained via resin cements.

09:18

Adhesive post-endodontic treatment using FRC posts in Front teeth: A 5-9 years retrospective study

*Cerny D, Cerna L

Institute of Dentistry and Oral Sciences, Faculty of Medicine and Dentistry, Palacky University Olomouc, Olomouc, Czech Republic

Aim Authors present the protocol and long term clinical results of post-endodontic treatment utilising fibre-reinforced composite (FRC) posts, dual-cure composite cement and the total etch technique

Summary Adhesive post-endodontic restoration using FRC posts is gaining clinical interest thanks to its optical and mechanical properties. There is still, however, some controversy over its clinical stability. Long term data is rare and hardly relevant. There are many aspects which make any comparison difficult: 1. The wide spectrum of FRC posts with different mechanical properties. 2. Different protocols for dentin-cement and cement-post adhesion. 3. Clinical process bias (selection of cases, magnifying devices used) 4. Crown preparation protocol variations. The authors present their own work protocol used for 11 years and 5,500 cases in total. Data for the current study were

collected from 300+ clinical cases of incisors and canines followed for a period between 5-9 years. The work protocol, however, has developed over the observed period (e.g. post insertion depth, total-etch adhesive system generation) following the same principles described in presentation. All posts were placed by one operator - an endodontist - in the environment of private practice. Core build-ups were usually placed during the same visit as endodontic treatment. Overall survival rate is close to 97%. The two main reasons for failures were identified as caries and trauma.

Key Learning Points

- To understand how reliable is adhesive FRC build-up in long time observation.
- To understand what are the pivotal strategies of successful adhesive post-endo restorations.
- To learn how to make risk-free reliable adhesive build-up

09:36

Push-out bond strength of adhesively bonded fibre posts on irradiated and nonirradiated root dentine

*Başer Can ED¹, Barut G¹, Işık V², Algül E³, Can E⁴

¹Department of Endodontics, Yeditepe University, Faculty of Dentistry, ²Department of Endodontics, Okan University, Faculty of Dentistry, ³Department of Radiation Oncology, Dr. Lütüfi Kırdar Kartal Eğitim ve Araştırma Hastanesi, ⁴Department of Operative Dentistry, Yeditepe University, Faculty of Dentistry, Istanbul, Turkey

Aim The aim of this study is to evaluate the effect of ionizing radiotherapy on resin-dentin interface in endodontically treated teeth with fiber posts in terms of push-out bond strength and to analyze the cement/dentine interface by scanning electron microscopy (SEM).

Summary Fifty-six single rooted premolar teeth were decoronated and the length of roots were standardized at 17 mm. The roots were divided into 2 experimental groups (n=28). Roots in group I were not irradiated while the roots in group II were irradiated at 2 Gy per fraction, 5 times per week, for a total dose of 60 Gy in 30 fractions during 6 weeks. All root canals were instrumented with

ProTaper Next rotary files (Dentsply Maillefer, Ballaigues, Switzerland) and filled with AH Plus (Dentsply De Trey, Konstanz, Germany) and gutta-percha. Canals were irrigated with 5,25% NaOCl between each preparation step. At the end of preparation the canals were flushed with 17% EDTA for 1 minute followed by 5,25 % NaOCl irrigation and final rinse with distilled water. After root canal treatment procedure the specimens of each group were randomly assigned to 2 subgroups (n=14). Post spaces were prepared with number 2 post drill (Dentsply, Maillefer) leaving a 5 mm of apical gutta-percha filling. Fiber posts were cemented with universal adhesive resin cement using self etch and total etch systems in subgroups respectively. A push-out bond strength test was done. Lower bond strength was observed in irradiated teeth compared to nonirradiated specimens. Bond strength results of total etch adhesive system showed higher values than self etch adhesive system in both irradiated and nonirradiated teeth. In the SEM examination, a large number of regions containing gaps were found at the cement/dentin interface in the irradiated compared with nonirradiated specimens. As a conclusion radiotherapy significantly reduced the push-out bond strength of fiber posts. If post restoration is required after the radiotherapy regimen, the patient should be informed of a less than ideal prognosis.

Key Learning Points

- Radiotherapy reduces the push-out bond strength of root dentine

09:54

A safe and gentle technique to remove ThermanfilCarrier or similar products in retreatment cases with a new device: A case and technique presentation

*Widera N

Zahnarztpraxis für Endodontie und Zahnerhaltung, Zahnarztpraxis, Leipzig, Germany

Aim In this presentation i'll briefly outline the advantages of using the wire loop technique to facilitate the removal of plastic Thermanfill carrier systems.

Summary As shown in several studies, removing Thermafill carriers in retreatment cases can present a major challenge. Complications include the pressing of plastic chippings and transportations of the root canal. During removal, breaking of plastic carriers can hardly be avoided using conventional methods. The wire loop technique using the FragRemover represents an effective and easy to handle new method. It allows for the removal of plastic carriers without mechanical fracturing in a single step procedure while preserving the original root canal. A pressure-related risk of root fracturing during removal can thus be completely ruled out.

Key Learning Points

- Retreatment during Thermafill root canal fillings
- Application of wire loop technique using the FragRemover
- Preparation of the access cavity prior to using the FragRemover

10:12

The Efficiency of XP-Endo Shaper and XP-Endo Finisher R in the Removal of Root Filling Material from Oval Root Canals

*İriboz E, Bora T, Pehlivanoglu E

Department of Endodontics, Faculty of Dentistry, Marmara University Istanbul, Turkey

Aim The aim of this study was to evaluate the effectiveness of hand files, ProTaper R, Reciproc, XP Endo Shaper and XP Endo Shaper in combination with XP Endo Finisher R in the removal of obturation material with and without the aid of solvent.

Summary A total of 110 extracted human mandibular premolars with one single straight oval root canal were selected for this study and prepared with a Reciproc #25.08 system to the working length. The teeth were obturated with Elements Free Obturation Unit with AH Plus Sealer and then divided randomly into ten groups (n=10) according to the retreatment techniques. Group 1; hand files, Group 2; Reciproc, Group 3; ProTaper R, Group 4; XP Endo Shaper, Group 5; XP Endo Shaper in combination with XP Endo Finisher R. In Groups 6, 7, 8, 9 and 10 the mechanical retreatment

procedures were the same as Groups 1, 2, 3, 4 and 5 respectively. In these groups Resosolv was added to the procedure. Retreatment time and procedural errors were also recorded and analysed. All roots were sectioned perpendicular to the long axis at 1 and 3 mm from the apex using a precision saw. Images were captured by a stereomicroscope. Leica QWin software was used to calculate the amount of debris remaining in the root canal space. Statistical analysis were evaluated by one-way ANOVA and Student's t tests. Reciproc instruments were significantly faster than all the other techniques at removing the filling material from the root canals ($p < 0.01$). XP Endo Shaper and XP Endo Finisher R groups with or without solvent were statistically more effective than the other techniques at removing the filling material ($p < 0.01$). All the solvent aided groups were faster than the other groups at root filling removal. Neither systems completely removed the filling material from the root canals.

Key Learning Points

- Comparison of retreatment efficiencies of the novel instruments with the conventional methods.
- Efficacy of XP Endo Finisher R at removing filling material when used in combination with XP Endo Shaper.
- Efficiency of solvent in root canal filling removal.

11:00 to 12:30

11:00

Healing Capacity of Bone Surrounding Biofilm-Infected and Non-Infected Gutta Percha: A Study of Rat Calvarium

*Lin S¹, Akrish S², Gutmacher Z³, Geffen Y⁴, Kaufman AY¹, Wigler R⁵

¹Department of Endodontics and Dental Trauma, School of Graduate Dentistry, Rambam Medical Center, ² Department of Pathology, Rambam Medical Center, ³Faculty of Medicine, Technion, ⁴Clinical Microbiology Laboratory, Rambam Medical Center, ⁵ Department of Endodontics and Dental Trauma, Rambam Medical Center, Haifa, Israel

Aim To evaluate the healing capacity of bony lesions around biofilm-infected and non-infected gutta-percha (GP) points.

Summary Wistar rats were divided into biofilm-infected and sterile non-infected GP groups. The points were implanted into bony defects created in the animals' calvaria. The animals were sacrificed 60 days postoperation, and histological assessments were performed. The GP particles in the non-infected group, minimal inflammatory cell reactions were observed in the adjacent tissue and newly woven bone matrix surrounded by osteoblasts was noted. In the biofilm-infected group, a mild foreign body reaction with a few inflammatory cells was noted adjacent to the capsule, and newly woven bone matrix surrounded by osteoblasts and mature bone was also noted. This research demonstrate that the presence of infected gutta percha with biofilm on it, has no capacity to enduce the periapical lesion without the presence of infected root canal in vicinity. Further research to evaluate this issue is warranted.

11:18

The staining effects of different antibiotics based root canal medicaments

Yilmaz F, Öztan Md, Akkor T, *Özşahin A

Department of Endodontic, Ankara Univercity, Faculty Of Dentistry, Ankara, Turkey

Aim The aim of the present in vitro study is to assess the color changes resulted with root canal medicaments (Ledermix, Triple Antibiotic Paste containing Cefuroxime, Triple Antibiotic Paste containing Minocycline, Odontopaste which containing clindamycine hydrochloride and triamcinolone acetonide

Summary Introduction: Tooth discolorations can be classified as intrinsic, extrinsic or a combination of both. Limited data are available on the staining ability of recent endodontic materials. Root canal medicaments may contain chemical components which has staining potential. The aim of the present in vitro study is to assess the color changes resulted with root canal medicaments (Ledermix, Triple Antibiotic Paste containing Cefuroxime, Triple Antibiotic Paste containing Minocycline, Odontopaste which containing clindamycine hydrochloride and triamcinolone acetonide) Methods: 60 human maxillary central incisors were used. The teeth were divided in to six groups. Two as positive and negative control. Study groups were filled with medicating pastes. After the incubation period, measurements were carried out with a spectrophotometer. The colour changes were calculated by subtracting the baseline L*, a* and b* values from the values at subsequent observations. Data in this study is determined by using SPSS 20.0 analytic software. While comparing multiple groups Kruskal Wallis test was used. The statistical difference of colour changes relating to each time interval, Friedman Sign test was used. P value < 0,05 was considered significant. Results: The negative controls showed the least tooth discolouration. Positive controls showed immediate severe discolouration, it was significantly different (p<0.05). Each of Triple Antibiotic Paste groups were showed more discolouration than other groups for each time intervals. In Odontopaste group there weren't statistical difference of colour changes relating to time interval Conclusions: All tested endodontic medicaments have staining ability on teeth which Triple Antibiotic Paste groups were caused most severe. Odontopaste, containing clindamycine instead of Ledermix can be preferred.

Key Words: Endodontic medicaments, triple antibiotic paste, Spectrofotometer

Key Learning Points

- The results of this study showed that there is a strong tendency for teeth to darken with time, which is greater in some materials than others.
- Two of Triple Antibiotic Paste groups were showed most severe and increasing discoloration over time than the other medicaments.

11:36

Prevention of biofilm formation by disinfecting macromolecules incorporating into sealer

*Solomonov MS, Becker T

Department of Endodontics, Sheba Hospital, Tel Hashomer, Israel

Aim To summarize data about disinfecting macromolecules incorporated in sealers and to present a new research about Epoxy sealer with macromolecule for prevention of biofilm formation.

Summary Coronal seal is a huge problem in clinical practice. Time Gap between Endodontic treatment and final restoration are Achilles' heel in many cases. Retreatment is world wide accepted recommendation in situation after 3 month without proper coronal seal. incorporation of disinfecting macromolecules into old and new sealers might change the situation. New research of Epoxy sealer with addition of disinfecting macromolecule gave a interesting results in-meaning of biofilm formation prevention. Future research and possible clinical implications will be discussed.

Key Learning Points

- Prevention of Biofilm formation possible by disinfecting macromolecules
- Disinfecting macromolecules incorporated into sealer is a novel approach to old problem of coronal seal

11:54

The fate of 10-year root canal treatments filled with Thermafil system

*Pirani C, Iacono F, Gatto MR, Chersoni S, Gandolfi MG, Prati C

School of Dentistry, Endodontic Clinical Section, Department of Biomedical and Neuromotor Sciences (DIBINEM), University of Bologna, Alma Mater Studiorum, Bologna, Italy

Aim The purpose of this clinical retrospective study was to investigate long-term results of root canal treatments filled with a carrier based system (Thermafil, TF).

Summary A total 59 patients treated in a Master of Endodontics between December 2005 and January 2007 by trained postgraduates, were involved in a Recall-program. Teeth were instrumented using a step-down technique, filled with TF and AH-Plus sealer and definitively restored with direct composite restorations or crowns. Treated teeth responding to all the inclusion criteria were clinically and radiographically reexamined to estimate 10-year survival and periapical status. Demographic and medical data were registered. Collected tooth variables included: tooth type/location, preoperative signs/symptoms, number of appointments, occlusal contacts, instrument type, curvature radius, root filling quality, final apical diameter, coronal restoration, post placement and intra-operative complications. Teeth were considered 'healthy' (PAI \leq 2, no signs/symptoms) or 'endodontically diseased' (PAI \geq 3, signs/symptoms present, retreated, extracted for endodontic reasons). For teeth lost during the 10-year follow up, data and reason for extraction were analyzed. Two PAI-calibrated examiners assessed outcomes blinded to preoperative status of teeth. Bivariate and multivariate analyses were performed ($\alpha = 5\%$). Of 142 included teeth, 129 (91%) survived and 13 were extracted: 9 for non-endodontic reasons (excluded from analysis) and 4 for endodontic reasons (considered 'endodontically diseased'). A positive percussion test ($p=0.033$), the presence of radiolucency ($p=0.028$) and pulpal/periapical diagnosis ($p=0.012$) significantly influenced survival. Positivity to percussion test, presence of periapical lesion and retreatment with lesion were hypothesized to be risk factors for extraction and consequently for a lower survival by multilevel analysis. Total of 124/133 teeth (93%) were assessed as 'healthy'; no significant bivariate association was evidenced with success. The limited sample size could explain the absence of significant associations between success and considered variables

Key Learning Points

- After 10 years, approximately 91% of teeth treated in a specialist Masters program survived and 93% of retained teeth resulted periapically healthy.

12:12

Root canal cleaning. SEM study of Revo-S® vs ProTaper Next® vs 2Shape®

*Diemer F¹, Georgelin-Gurgel M¹, Michetti J¹, Boesch J¹, Mallet JP¹, Nehme W²

¹Department of Endodontic, Faculté de Chirurgie Dentaire, Toulouse, France, ²Endodontic Department, Université Saint Joseph, Beyrouth, Lebanon

Aim Asymmetric profile files are sometimes presented as instruments with superior cleaning capability to symmetrical instruments. Our SEM study compared removal of debris and smear layer of three endodontic systems: Revo-S®, ProTaper Next® or 2Shape®.

Summary Thirty nine teeth with a single canal and a curvature of less than 25° are selected and randomly divided into three groups (n=13). Each tooth is prepared by the same operator in a conventional manner following the manufacturer's instructions at 300 rpm and a torque of 3N.cm with the X-Smart® engine (Dentsply). Irrigation is done between each instrument with 2ml of 2.5% NaOCl using a 27 gauge EndoNeedle® lateral deflection syringe. The last instrument was passed for sixty seconds with 5 parietal brushing motion at the thick walls and two at the thin walls. A final rinse (5 ml) with sodium hypochlorite (2.5%) is carried out. The root cut longitudinally. The samples are placed in a low vacuum scanning electron microscope (JEOL JSM 53-10LV) which did not require specimen preparation. The dentinal walls are analyzed on the cervical, middle and apical third to x100 and x1000 magnification to analyze respectively the presence of debris and smear layer. The evaluation of the results was done by three observers (in double blind). A score of 0 to 5 is given for each image. Results: Analysis of the variance shows a statistically significant difference ($p = 0.0092$) for debris between the two Revo-S® and ProTaper Next®. There is no significant difference between Revo-S® and 2Shape®. For smear layer, there was a statistically significant difference only between 2Shape® and ProTaper Next® ($p=0,0442$).

Key Learning Points

- This study showed that the 2Shape® is superior for removing debris in the apical and middle third and prepares more dentinal apical surface.

Our Sponsors

Diamond



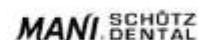
Gold



Silver



Bronze



Our Exhibitors

Acidental
American Association of Endodontists
B&L Biotech
Carl Zeiss Meditec
CJ-Optik
DHM-Dental
ExamVision Belgium
Flemish Society for Endodontology
FragRemover
Global Surgical Corporation
Henry Schein Dental Europe
IFEA
J Morita
Karl Kaps
KOHLER Medizintechnik
Kornerdental
Laschal Surgical Instruments
LegacyENDO
MARUCHI
Medcem
Medident Italia
Meta Biomed
Neolix
Nissin Dental Products
Produits Dentaires
Quality Endodontic Distributors
Quintessence Publishing
Schlumbohm
Seiler Instrument
Shenzhen Superline Technology
Tri Hawk
Vista Dental Products
Wam
Zumax Medical



Organizing Secretariat

AIM Group International - Sales Office

