ESE 2019

VIENNA

11 - 14 SEPTEMBER

Vienna calling

experience the sound of Endodontology

Clinical Posters

19th Biennial ESE Congress

11-14 September 2019

Austria Center Vienna

THURSDAY

C1

Intentional Second Replantation

Frick K, Divine J, Kendall C
University of Missouri-Kansas City, School of Dentistry
Advanced Education in Endodontics

Aim

To present a second Intentional Replantation (IR) of 2nd mandibular molar eight weeks after failed initial replantation

Introduction

IR is an insertion of a tooth into its alveolus after the tooth has been extracted for the purpose of performing treatment (AAE glossary of terms). IR is considered a reliable process (1) with a high success rate (2).

Initial preop (A); CBCT showing C-shaped anatomy (B); immediately post replantation (C); resection and retroprep (D) and retrofill (E).

Case Presentation

Following initial IR of the C-shaped 2nd mandibular molar diagnosed as previously treated with a chronic apical abscess, a 12 mm mid lingual periodontal pocket persisted two months post treatment (F), and the patient reported pain in the area. It was decided to repeat the replantation with the restoration of the C-shaped defect with Brasseler BC Putty®.

12mm lingual pocket (F); Two months Post initial IR (G)

The perio dressing was removed at 5 days and the splint was removed at 5 weeks. Healing was uneventful. At 9 months periodontal probings were 4 mm at 6 sites around tooth with resolution of mid lingual deep pocket. The tooth was restored with a crown.

Position of putty placement (H and I). Replantation with flexible splint and perio dressing (J and K).

Discussion

This is an unconventional treatment of a unique condition with the C-shaped furcal region of the 2nd mandibular molar that initially showed no healing after the first IR. This second IR following application of a bioceramic cement resulted in significant healing nearly one year post-treatment.

Nine months after 2nd IR

Conclusion & Clinical Relevance

Irregularities in root surfaces may be successfully repaired with bioceramic cements during replantation procedures.

References

1. Perr M. Intentional replantation-a last resort treatment or a conventional procedure? Nine case reports. Dent Traum 20.1 (2004): 48-55
2. Manikar A. A systematic review of the survival of teeth intentionally replanted with a modern technique. J Endod 2017;43: 1963-1968

Management of an Immature Premolar with Type II Dens Invaginatus

Pei Yuan, Chan

National Dental Centre Singapore, Restorative Department, Singapore

Introduction

Dens invaginatus is the malformation of a tooth caused by the invagination of the enamel organ into the dental papilla prior to calcification of the dental tissue[1]. The reported prevalence of adult teeth affected with dens invaginatus is between 0.3% and 10%, with maxillary lateral incisors being most frequently involved[1], and posterior teeth being less likely to be affected.

Pre-operative radiograph #44

Aim

This case report describes the successful management of an immature lower right first premolar with a Type II dens invaginatus.

Case Presentation

A 16-year-old Chinese female presented with pain and swelling of her lower right mandible. Her lower right first premolar was tender to percussion and palpation, and was not responsive to vitality tests. The cone-beam computed tomography scan revealed an Oehlers' Type II invagination extending from the crown to the mid-root. Tooth #44 was diagnosed as pulp necrosis with acute apical abscess and was planned for root canal treatment with root-end closure. The canal orifice was of a C-shaped configuration embracing the invagination. Satelec ET20 was used to refine the access, and cleaning and shaping was completed with rotary RaCe. Passive ultrasonic irrigation of 2% NaOCl aided by Satelec K-file #15 was used to facilitate chemomechanical instrumentation. Calcium hydroxide was placed and the tooth temporized with IRM®. On the next visit, an MTA apical plug was placed, backfilled with thermoplastized gutta-percha, and the tooth restored with a composite core. At the 2 years review, there was continuous periodontal ligament space.

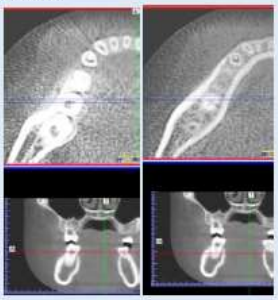

CBCT coronal third CBCT apical third

Post-operative radiograph #44

2 year review radiograph #44

Discussion

The enamel lining around the lumen of the invagination, the aberrant anatomy and the absence of a true apical constriction creates problems of adequate chemomechanical debridement, predictable working length control and root filling[2]. Judicious instrumentation and irrigation within the confines of the root canal system allowed for adequate disinfection of this immature premolar. Root filling with MTA to create a biocompatible apical seal has been recommended for the management of dens invaginatus with immature apices[2,3]. For this case, the use of MTA promoted healing of the periapical tissues.

Conclusion & Clinical Relevance

Meticulous disinfection procedures within the confines of the root canal system, the use of a biocompatible material for the apical seal, and the presence of a good coronal seal facilitated in the periapical healing of this immature premolar with a dens invaginatus.

References

1. Hülsmann M (1997) Dens invaginatus: aetiology, classification, prevalence, diagnosis, and treatment considerations. IEJ 30, 79–90
2. Bishop and Alani (2008) Dens invaginatus. Part 2: Clinical, radiographic features and management options IEJ 41, 1137-1154
3. Gallacher et al (2016) Dens invaginatus: diagnosis and management strategies. BDJ Vol 221 No.7, 383-387

C3

Multiple external cervical resorptions as a complication of systemic sclerosis? A case report.

Teerlinck I., Kellens A., de Hemptinne F.

Department of endodontics, Vrije Universiteit Brussel, Brussels, Belgium

Aim To present and describe a case report about the possible association between multiple external cervical resorptions and systemic sclerosis.

Introduction

External Cervical resorption (ECR) is the loss of cementum, enamel and dentine as a result of odontoclastic action.(1) Systemic sclerosis (SSc) is a chronic autoimmune disease that alters the connective tissue. The cause is still unknown. The disease is characterized by thickening of the skin and injuries to small arteries as a result of an accumulation of collagen. In the localized (non-systemic) form, only the skin of the face, hands and feet are involved. In the diffuse form, the visceral organs and muscles may also be affected. It is a very rare disease (50 to 300 cases per 1 million) with a 4 times higher prevalence in woman. The most common oral manifestations of SSc are microstomia, periodontal disease, widened periodontal ligament, xerostomia and osseous resorption. Root resorption and calcification of the pulp chamber and periodontal ligament have also been reported.(2) Only one well documented case describes the possible association between SSc and multiple ECR. (3)

Case Presentation

A 73 year old caucasian woman with ASA 2 score was referred for an endodontic treatment of tooth 36. The treatment had been initiated by the referring dentist. SSc was diagnosed in 2001 and accordingly, the patient uses immunosuppressive drugs and NSAID's. The clinical symptoms of SSc include thickening of the skin, microstomia and joint problems. After the radiographic discovery of multiple ECR, sensibility tests were performed on all teeth. The patient had no teeth related pain. All posterior teeth responded negatively to a cold thermal test. Only the frontal upper teeth reacted positively to the same test. No tooth tested positive on a percussion test. Because the patient doesn't have any symptoms of ECR, we advised routine dental check-ups.

The periapical radiographs show diffuse loss of bone structure in all posterior teeth. There is no obvious apical pathology present. The clinical images show no signs of ECR or pink spots.

Using dental microscope (Carl Zeiss AG, Oberkochen, Germany) , exploration of element 36 was done by using C-pilot file 10 (VDW, München, Germany). Canals were prepared by reciproc 25 and Mtwo 35.04 intruments (VDW). During instrumentation, copious irrigation was performed with NaOCL 3%. After completion of the preparation, sonic irrigation (Eddy, VDW) with EDTA 17% and NaOCL was executed. Warm vertical condensation of GP points with a taper of 4%, calibrated to a diameter of 35 was used in association with Ah-plus as a canal cement (Dentsply Sirona, Ballaigues, Switzerland).

Discussion

For this case, the most common causes of SSc can be discarded. According to the patient, there was no orthodontic or periodontal treatment in the past and no trauma. The patients periodontal condition is mainly age and hygiene related. There is a very likely association between the rare SSc and multiple ECR's.

Conclusion & Clinical Relevance

System sclerosis can most probably be a cause of the etiopathogenesis of external root resorption. Further investigation is necessary.

References

1. Consolaro A. External cervical resorption: diagnostic and treatment tips .Dental Press J Orthod. 2016 Sept-Oct;21(5):19-25.
2. Derbi HA, Borromeo GL. Scleroderma and the Oral Health Implications. Adv Dent & Oral Health. 2018; 7(4): 555716.
3. Arroyo-Bote S, Bucchi C, Manzanares MC. External Cervical Resorption: A New Oral Manifestation of Systemic Sclerosis. J Endod. 2017 Oct;43(10):1740-1743.

C4

Canalis Sinuosus mimicking a root resorption

Hadas Azizi, Avi Hadad, Joe Ben Itzhak, Michael Solomonov

Department of Endodontics, Israel Defense Forces (IDF)
Medical Corps, Tel Hashomer, Israel

Aim

To discuss the role of Cone-Beam Computed Tomography (CBCT) in the diagnosis of a case with un-correlated clinical and radiological findings.

Case presentation

A 43-year-old healthy male presented with a radiographic incidental finding of a radiolucent area in the middle-apical thirds of tooth 11.
No history of orthodontic treatment or dental trauma.
Tooth 11 presented a mesial composite restoration, without sensitivity to percussion and palpation. Probing depth was under 3 mm, cold and electric pulp sensibility tests were positive.
The radiolucent area in the root of tooth 11 was suspected to be a resorption.

CBCT scan was performed as additional diagnostic tool. The scan revealed a neural or vascular channel within the bone, approximately 1.5 mm in diameter, passing the palatal aspect of tooth 11. The root was intact. **Normal pulp with normal apical tissue and canalis sinuosus were diagnosed.**

Conclusion

Canalis Sinuosus in the anterior maxillary area may mimic dental pathological condition. CBCT scanning may aid achieving a proper diagnosis in such cases by revealing the 3D anatomic structure, prevent misdiagnosis and unnecessary treatments.

References

de Oliveira-Santos C, Rubira-Bullen IR, Monteiro SA, et al. Neurovascular anatomical variations in the anterior palate observed on CBCT images. Clin Oral Implants Res 2013;24:1044–8.

Leven AJ, Sood B. Pathosis or Additional Maxillary Neurovascular Channel? A Case Report. J Endod 2018;44:1048-51.

Wanzeler A. Anatomical study of the canalis sinuosus in 100 computer tomography examinations. Oral Maxillofac Surg 2015;19:49–53.

PA radiographic Image

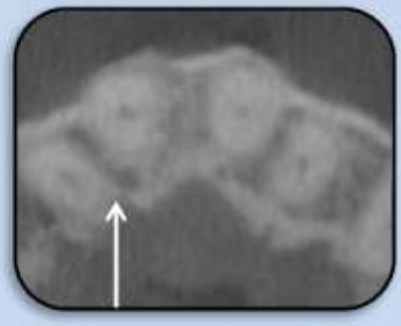

CBCT images revealed the canalis sinuosus palatal to tooth 11 (white arrows)

C5

Periapical bone healing after treatment with calcium hydroxide and MTA obturation: a clinical case of recurrent trauma

UFRJ

Tinoco JMM[1*], Santos AEC[2], Sassone LM[1], Tinoco EMB[1]
[1] Department of Endodontology, Faculty of Dentistry, State University of Rio de Janeiro, Rio de Janeiro, Brazil.
[2] Department of Endodontology, Faculty of Dentistry, Federal University of Rio de Janeiro, Rio de Janeiro, Brazil

Aim - To report a clinical case of recurrent trauma showing periapical bone healing after retreatment using intracanal calcium hydroxide, followed by root canal obturation with mineral trioxide aggregate (MTA).

Introduction - Recurrent traumatized teeth associated with refractory disease showing extensive periapical lesion pose a treatment challenge, as the amount of remaining bone is often insufficient for tooth replacement by implant.

Case Presentation: A 42-year-old male patient was referred after recurrent trauma on tooth 21 which had previously received endodontic treatment. Tooth showed pain on percussion, grade II mobility and fluctuant swelling with suppuration in the palatal area. Radiographic examination (Fig.1) revealed presence of periapical lesion, poor quality canal obturation and presence of discernible core material. Cone-beam tomography (CBCT) evidenced partial disruption of palatal bone ridge and extensive periapical bone loss (Fig.2a,b,c,d).



Patient received antibiotic therapy (amoxicillin + potassium clavulanate 875mg TID for 7 days). Chemomechanical instrumentation was completed by using size 60–80 stainless steel K-files, 2.5% NaOCl irrigation, and calcium hydroxide intracanal medication for 14 days, followed by MTA obturation.

8-month follow-up showed a clinically asymptomatic functional tooth, and images showed evidence of optimal periapical bone healing (Fig 3a,b,c).
Glass fiber post & core was luted, prepared and scanned to receive a 3D-milled Zirconia crown (Fig.4a,b).

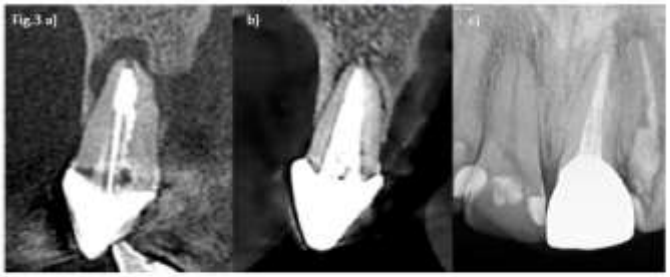

Discussion: Endodontic treatment and MTA obturation of the entire canal is a valuable treatment option in recurrent trauma cases associated with refractory disease. It stimulates bone healing without the need of grafting or surgical intervention in aesthetic area, reducing overall treatment time.

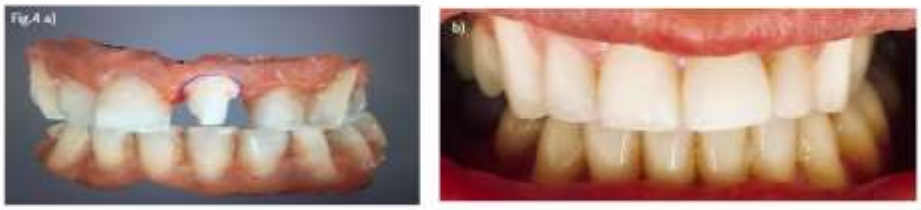

Conclusion & Clinical Relevance - Conservative treatment using calcium hydroxide as an intracanal medication for 14 days, followed by mineral trioxide aggregate (MTA) obturation is a fast, simple, and efficient treatment option for recurrent traumatized teeth associated with refractory disease.

References:

-Torabinejad M, Watson TF, Pitt Ford TR. Sealing ability of a mineral trioxide aggregate when used as a tooth end filling material. J Endod 1993;19:591-5.
-Bogen G, Kuttler S. Mineral trioxide aggregate obturation: A review and case series. J Endod 2009;35:777-90.
-Sarkar NK, Caicedo R, Ritwik P, Moiseyeva R, Kawashima I. Physiochemical basis of the biological properties of mineral trioxide aggregate. J Endod 2005;31:97-100.

C6

Periorbital emphysema during endodontic retreatment of an upper central incisor

A. Al-Qudah,*[1] F. Amin[2] and Y. Hassona[3] [1]Jordan University of Science and Technology, [2] Bristol Dental Hospital,[3] University of Jordan

Aim

To present a case of periorbital emphysema encountered during root canal treatment

Fig. 1 Preoperative radiograph, showing overextended root canal filling and open crown margins for UR central incisor

Fig. 2 A significant soft tissue swelling

Introduction

Periorbital emphysema is subcutaneous emphysema that arises when air is introduced into the periorbital tissues

Case Presentation

- A 54-year-old female patient was referred for the management of a chronic sinus tract related to her upper right central incisor. A diagnosis of chronic apical abscess was made and it was decided to perform non-surgical retreatment for the tooth.
- In the first appointment, the crown was sectioned and removed, the tooth was isolated with a rubber dam and the cast post and core retrieved using ultrasonic vibrations. Tooth was temporized with a temporary post-retained crown.
- In the second appointment, the tooth was isolated with a rubber dam and Hedstrom files were used to remove gutta percha from the apical third of the canal, which was then thoroughly irrigated with 0.2% chlorhexidine solution
- After that, air from the 'three-in-one syringe' was used to remove excess irrigant. Immediately following air blowing, the patient's upper and lower right eyelids appeared swollen and pale. The swelling was painless, non-erythematous, non-tender and showed crepitus on palpation, and she was unable to open her right eye, Fig 2.
- Treatment was stopped, patient reassured, tooth temporized. Patient was accompanied to a nearby eye hospital, and a consultant ophthalmologist confirmed the diagnosis.
- The patient was prescribed a course of prophylactic antibiotics (amoxicillin 500 mg TDS and metronidazole 200 mg TDS) for one week and sent home.
- The following day, patient was contacted by phone, and she reported that she started opening her right eye. On day three, the patient reported significant reduction in the size of the swelling, and one week later, her right eye was back to normal.

Discussion

The periorbital space offers low tissue resistance and therefore air accumulated readily in this space.

Fig. 3 Pa radiograph, after removal of post/ core and crown

Fig. 4 Complete resolution of the swelling two weeks later

Conclusion & Clinical Relevance

- Subcutaneous emphysema is a rare but potentially serious complication of root canal treatment. Majority of cases are managed conservatively
- It is characterized by sudden onset of soft tissue swelling, associated with crepitus, during or shortly after the procedure.
- Blowing compressed air into root canals should be avoided

References

Uyanık L O, Aydın M, Buhara O, Ayalı A, Kalender A. Periorbital emphysema during dental treatment: a case report. Oral Surg Oral Med Oral Pathol Oral Radiol Endod 2011; 112: e94–96

C7

Conservative management of large periapical lesion associated with mature and immature permanent teeth using conventional and regenerative endodontic procedures: a case report.

Mahmoud Ramadan Mohamed Abo ElSeoud

Faculty of Dentistry, Alexandria University, Egypt

Aim:To discuss the conservative management of large periapical lesion associated with mature and immature permanent teeth using decompression technique, conventional root canal treatment and regenerative endodontic procedure (REP).

Introduction:Surgical removal of large periapical lesions may damage adjacent vital structures while decompression is a more conservative approach. Immature permanent teeth with wide open apices and thin roots possess several treatment options where REP can be considered the best treatment option for such teeth.

Case Presentation :A 21 years old male patient was referred to the endodontic department , complaining from pain and swelling in the upper right anterior region. Panoramic view(fig 1) showed a large periapical lesion involving tooth 11 and tooth 12. Tooth 11 was immature with inadequate RCT.CBCT image analysis in all planes revealed expansion of buccal and palatal cortical plates and destruction of buccal plate(fig 2). Sensibility tests of involved teeth showed pulpal necrosis in #12.

Fig 1

Decompression of the lesion was done and a gauze drain packed into the lesion and changed every 3 days for 6 weeks. Calcium hydroxide was placed in both teeth for 6 months period. Conventional RCT was done for tooth 12 and REP for 11 with the use of platelet rich fibrin(PRF)as a scaffold(fig 4). One year follow up(fig 3) showed healing of the lesion and formation of calcified bridge in tooth 11 with thickening of the canal walls.

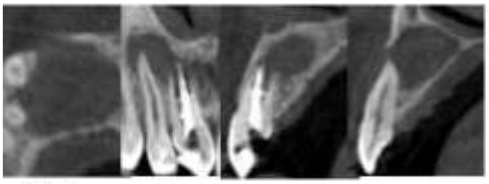

Fig 2

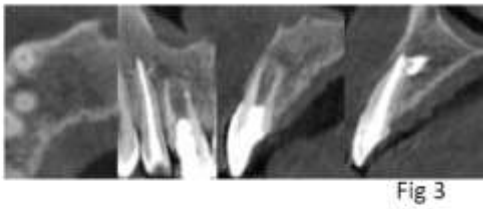

Fig 3

Discussion: Conservative management of large periapical lesion was possible by a simple decompression technique which allowed disrupting the integrity of the lesion wall and reducing internal osmotic pressure. Long term calcium hydroxide intracanal medication allowed disinfection of the canals and provided adequate microenvironment for the REP. PRF scaffold can help achieve the goals of the REP.

Fig 4

Conclusion & Clinical Relevance: The outcome of this case suggests that the size of a periapical lesion is not a major determining factor to perform surgical removal of the lesion and even large periapical lesions can heal following nonsurgical root canal treatment and REP.

References

1. Caliskan MK. Prognosis of large cyst-like periapical lesions following nonsurgical root canal treatment: a clinical review. Int Endod J 2004; 37:408-16.
2. Diogenes A et al An update on clinical regenerative endodontics. Endodontic Topics 2013;28:2-23.
3. Galler KM et al. Influence of root canal disinfectants on growth factor release from dentin. J Endod 2015;41:363-8.
4. Bakhtiar H et al. Second-generation Platelet Concentrate (Platelet-rich Fibrin) as a Scaffold in Regenerative Endodontics: A Case Series. J Endod 2017;43:401-8.

C8

Cutaneous odontogenic fistula to the chin – a case report

Agata Koprowicz, Krystyna Pietrzycka, Halina Pawlicka
Department of Endodontics
Medical University of Łódź, Poland

MEDICAL UNIVERSITY OF LODZ
ESE 2019 VIENNA
11 - 14 SEPTEMBER

Aim: The study presents a case of a patient with a dental cutaneous fistula in the area of the chin that was healed after the root canal treatment.

Case Presentation:

In September 2017, a 31-year-old female patient was reported to the Department of Endodontics at the Medical University of Lodz for the endodontic treatment of teeth 31, 32 with the diagnosis of *chronic purulent periodontitis* with a cutaneous fistula located on the chin. The patient had more than 6-months history of being unsuccessfully treated by dermatologist including antibiotic and steroid therapy.

In the clinical examination, teeth 31 and 32 did not react to vitality tests, on vertical and horizontal tapping there was no painful response, the crowns of teeth were slightly darker without any deep filling. An external fistula was visible on the skin of the chin (Fig. 1). The orthopantomography and digital periapical radiograph (Fig. 2) revealed a large lesion in periapical tissues in area of teeth from 33 to 41. The endodontic treatment with canal dressings between visits based on $Ca(OH)_2$ and metronidazole while using the step-back technique and activated irrigation with 2.5% hypochlorite sodium as well as EDTA solutions, was performed. During the treatment, vestibular and lingual canal of tooth 31 joint together that was confirmed with the microscope. The obturation was carried out with the lateral compaction of cold gutta-percha and epoxy resin-based sealer (Figs. 3, 4). During the long-term treatment lasting more than 2 months, disappearing of the sinus tract was observed (Fig. 5). The last control radiological examination performed in December 2018 showed significant intraosseous repair at periapical lesion (Figs. 6, 7)


Fig. 1


Fig. 2


Fig. 3


Fig. 4


Fig. 5


Fig. 6


Fig. 7

Discussion:

Cutaneous sinus tract may be difficult to be diagnosed because patients do not report any symptoms related with teeth, however the odontogenic cause is 80% [1]. It is usually misdiagnosed with a local skin lesion and maltreated by specialists with antibiotics [2] or surgical procedures [3]. Endodontic therapy may eliminate the infection and lead to periapical healing without using other unnecessary methods [4]. The healing occurs by granulation, sometimes leaving a small scar, that might be corrected by plastic surgeon. The success rate of treatment is 80% [5], provided that optimal canal disinfection and hermetic sealing is achievable. Missing additional canal/s increases the risk of failure of the therapy.

Conclusion & Clinical Relevance:

This case highlights the fact that dental etiology should be an inseparable part of a differential diagnosis for any collar and facial skin lesions. The ordain of antibiotic therapy should be considered with high caution. The prognosis of treatment is good unless the root canal preparation is fully accomplished. Complex canal anatomy may hinder the endodontic treatment and influences the prognosis of treatment.

References:

1. Kishore Kumar RV et al. J Maxillofac Oral Surg 2012; 11:411-415 2. Abuabara A et al. Anais Brasileiros de Dermatologia 2012; 87: 619-621 3. Gupta M et al. Oral Surg Oral Med Oral Pathol Oral Radiol Endodontol 2011; 112: 132-136 4. Janev E, Redzep E. Open Access Maced J Med Sci. 2016 Sep 15;4(3):489-492.
5. Chan CP et al. J Formos Med Assoc 1998; 97:633-637

SUCCESSFUL MANAGEMENT OF A MAXILLARY ANTERIOR TOOTH WITH PULP CANAL OBLITERATION – CASE REPORT

Ferreira S. , Gouveia MA.
Endodontic Department – MAG Clinic

AIM

To report a case of a conservative endodontic approach of a maxillary incisor with pulp canal obliteration.

INTRODUCTION

Pulp canal obliteration occurs commonly following traumatic injuries to teeth and it is characterized by the apparent loss of the pulp space radiographically and a yellow discoloration of the clinical crown.[1] This clinical situation usually provides and endodontic treatment challenge.

CASE PRESENTATION

Patient: Male, 30 years, came to the practise complaining of palpation pain on the maxillary anterior region. Dental trauma 2 years ago. Negative responses to sensitivity tests. Positive response to vertical percussion on both teeth 21 and 22.
Diagnosis: pulpal necrosis + symptomatic apical periodontitis.
Treatment planning: non-surgical endodontic treatment.

Periapical x-ray showing no lesion inside the canal

Intraoral image indicating the yellow discoloration of the tooth 21

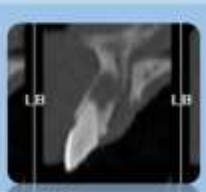

3D imaging showing obliterated pulp space of 21

CLINICAL PROCEDURE

Under magnification, an access preparation on tooth 21 was done with a high speed round diamond bur and ultrassonic tip Start-X #3 (Dentplsy). To improve the visualization of the root canal orifice, a little amount of sodium hypochlorite was placed inside, taking advantage of the "bubble-effect". The root canal scouting was made with C-Pilot (VDW) files #6, #8 and #10 and an x-ray was taken to verify the file position inside the canal. After measuring the working length with an electronic apex locator, the glidepath was prepared with ProGlider (Dentsply) and the complete shaping was done using Protaper Next (Dentsply) file system. The protocol of irrigation included 5,25% sodium hypochlorite, 10% citric acid and 96% alcohol. The tooth was obturated with Tagger's Hybrid Technique, with gutta-percha points and resin-based sealer (AH Plus, Dentsply) and restored with composite resin. In the following appointment the endodontic treatment of 22 was also done. After 2 years follow up the patient is assymptomatic and the lesion was healed.

Working length x-ray

Final x-ray

2-year follow up – complete lesion healing

DISCUSSION / CONCLUSION / CLINICAL RELEVANCE

The location and negotiation of the calcified canals are considered a great challenge during the endodontic approach. In order to locate them, procedural errors such as perforations, instrument fractures and deviations from the original channel path may occur[2]. Currently, various clinical features are used to help on these procedures, such as radiographs, magnification and ultrasonic devices. 3-D imaging play a very important role on the planning of the access opening. Other helpful procedures must be considered such as: dye with methylene blue and/or the "bubble effect" of the sodium hypochlorite[3] to identify the canal and multiple isolation to improve the visualization of the pulp chamber. Most of the literature does not support endodontic intervention unless apical pathology or symptomatology of the involved tooth is detected, which was verified in the case described[1].
The success of the treatment depends on the appropriate debridement and disinfection of the root canal system and requires the clinician's scientific knowledge and mastering of the technique to approach this type of situation.

REFERENCES
1. McCabe, P., Dummer, M. (2012). Pulp Canal obliteration: an endodontic diagnosis and treatment challenge. International Endodontic Journal, 45, pp. 177-197.
2. Cohen, S., Hargreaves, K. (2011). Cohen Caminhos da Polpa. 10ª edição. Rio de Janeiro. Elsevier. 3. Sardhara Y, Dhanak M, Parmar G. Management of maxillary central incisor with calcified canal: case report. Journal of Dental and Medical Sciences 15; 1(1):24-27.

C10

POS-GRADUAÇÃO ENDODONTIA IUCS

ESE 2019 VIENNA
11 - 14 SEPTEMBER

MANAGEMENT OF FOUR ROOTED MAXILARY SECOND MOLAR - CASE REPORT

Fernandes V. [1] | Cardoso L. [2] | Pereira V. [3] | Maia-Pereira A. [1,4] | Miller R. [1]

1 – Assistant of the department conservative Dentistry – IUCS-CESPU
2 – Student of the Doctoral Programme in Biological Sciences Applied to Health, at IUCS-CESPU
3 – Assistant Professor of the of the department conservative Dentistry – I.U.C.S-CESPU

Anatomical variations are a challenge to the clinician. Starting from diagnosis until treatment procedures.The aplication of conventional protocols of instrumentation, irrigation and obturation can not be sufficient to achieve the cleaning and shapping goals of modern endodontics

INTRODUCTION

The key objective of endodontic treatment is to remove pulp and disinfect the root canal systems. Therefore, a comprehensive understanding of the root and the root canal morphology is imperative to reduce endodontic failure caused by incomplete root canal preparation and obturation. Anatomic variations can compromise the effectiveness of the treatment. Most of the morphology studies identify as a normal configuration for a first and second maxilary molars, three roots and three or four canals[1]. The existence of four independent roots with it's quite rare and described in several studies with incidences below 1,5%.[2,3] This type of cases require a complex approach at any step of the endodontic treatment.

CASE PRESENTATION

Fig.1- Preoperative Radiograph

Fig.2- WL files radiograph

Fig.3- Cone Fit radiograph

Fig.4- Post-operative radiograph

Fig.5- 2 Years Follow-Up radiograph

Fig. 6- Acess cavity development lines

Fig.7-Obturation

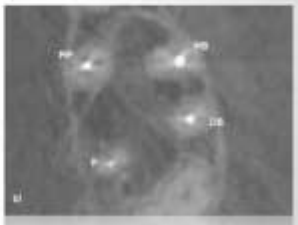

Fig.9 -Axial views

DISCUSSION/ CONCLUSION / CLINICAL RELEVANCE

A 38 year old female was referred to the endodontic department of a private clinic with major complain of pain on the upper left maxillary teeth.
The preliminary radiographic examination suggested a deep carious lesion on second maxillary molar with a rotation or anatomical variation on the roots. Radiographic and clinical examination was made. Periodontal status was stable and tooth had no mobility. The diagnostic confirmed a irreversible pulpitis with symptomatic apical periodontitis of tooth number twenty seven. The treatment proposed was non surgical endodontic treatment. Buccal infiltration anaesthesia was made (Articaine 4%- INBESA). Carious lesion was cleaned and a preendodontic restauration was made with flowble composite . The acess cavity was then refined and three canals were identified. After analysing the pulp chamber floor and position of the canals, a dark developmental groove suggested a presence of a fourth canal on the mesio-palatal wall of the cavity. All the canals were negociated with hand stainless steel files 06, 10 and patency was confirmed with rotary file Hyflex 10/05. (Coltene - Switzerland) Working length (WL) was determined by both apical radiographs and electronic apex locator (Propex PIXI - Dentsply-Sirona, Switzerland). Because of curvatures and height of the canals a instrumentation by cone technique was used, using PTN X1 and X2 (Dentsply Sirona, Switzerland) on the coronal thirds and Hyflex 20/04, 20/06 and 25/04 (Coltene - Germany) on the apical third. Continuous intra-canal irrigation was made with 5,25% sodium hypochlorite activated ultrasonically and final irrigation protocol included Citric Acid 10% and Alcool 90%. For obturation, 25/04 (VDW - Germany) gutta percha cones were used with sealer (AH Plus, Dentsply Sirona, Switzerland) using the continuous wave condensation technique. Canals were sealed with flowble resin and a temporary restauration was made.
The present case reports type I variation of a four rooted second molar, with a type II pulpar chamber floor, according to the literature[4]. This variation of morphology , has very low frequency reported , ranging from 0,4-1,4% in the morfology studies[1,4].
Radiographic diagnostic in this case was not a problem, but if the roots are superimposed , the use of CBCT or exploring the dark embryological grooves with the help of magnification would be useful to identify the canals.
On long and curved canals, to adopt instrumentation techniques by crown and instrument the apical portion with lower taper and diameter seems logical for two reasons: smaller diameter preparations involve less cutting of the canal walls, reduced file engagement and consequently a reduced likelihood for the expression of undesirable cutting effects, and small diameter files are more flexible and fatigue resistant and therefore less likely to cause transportation during enlargement[5]. Knowledge of possible variations in internal anatomy of human teeth are important for the successful outcome of endodontic treatment

Fig.9- 3D morphology reconstruction

REFERENCES

1- Pabbaff MG, Gerstein WH, Vogel HM. The maxillary second molar: variations in the number of roots and canals. Int Endod J 1999;29:305-312 - Aas IE, P JD. Root and Root Canal Morphology of Four-rooted Maxillary Second Molars. A Micro – Computed Tomography Study. 2012;38(7):971-82. 3- Marlise JMR. Root and root canal morphology of the permanent dentition in a Caucasian population: A CBCT study Root and root canal morphology of the permanent dentition in a Caucasian population: a cone-beam computed tomography study. 2016(November). 4- Carlos M, Anderson C. Four rooted maxillary second molar confirmed with cone beam computer tomography — A case report Segundo molare mascellare con quattro radici , rationale diagnostico. 2013(June). 5-+ Roane JB, Sabala CL, Duncanson MG Jr (1985) The "balanced force" concept for instrumentation of curved canals. Journal of Endodontics 11, 203-11.

The clinical use of digital radiography and CBCT in the diagnosis and follow-up of teeth with severe external root resorption

Alexandru Gliga, DDS*[1], Peter Kiefner, DDS, MSc[2]

[1]MSc Student Endodontics King's College London; [2]Practice for Endodontology and Dental Traumatology, Stuttgart

Aim

To present the possibilities of CBCT examination in identifying radiographic uncertain morphologic aspects of the tooth and the surrounding bone structure.

Introduction

Digital radiography and CBCT are commonly used to assess pre-, intra- and post-operative situations. The presented cases show clearly the advantages of the CBCT examination in order to perceive the extent and location of the resorptive processes. Treatment planning can be developed more specific, post-operative controls can be assessed more accurately and clinical maneuvers can be performed confidently, offering more prediction and a positive impact on the outcome.

Case Presentation

The cases were referred to the office in 2016 and 2018. Case 1 (27 years old male) was experiencing an acute episode with strapping pain for the last two days. Case 2 (24 years old male) was asymptomatic but presented a buccal sinus tract. For Case 2 the decision was to do a pre-op CBCT for a correct assessment and treatment planning.

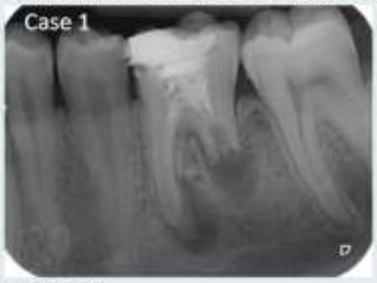

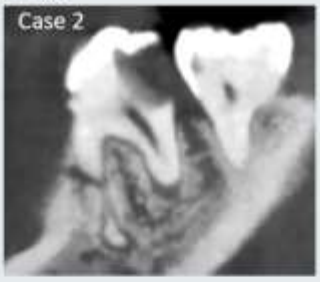

Methodology

The two cases were approached using the same protocol: the non resorbed canals were obturated in the first appointment (WVC) and the canals affected by resorption were dressed with intracanal medication for 1 week and obturated in the second appointment (MTA). The CBCT scanner used for Case 2 investigations: NewTom VGi evo, FOV [5x5] cm HiRes, 150 µm voxel size.

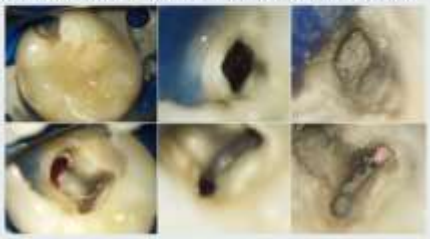

Discussion

For Case 1 the treatment planning was performed by digital radiography. Although a success, altered root canal morphology in these cases requires a detailed assessment. For Case 2, aspects like: the level of resorption, the localization, the number of roots affected, the number of canals, etc. were better visualized and controlled using a three-dimensional imaging procedure. The CBCT imaging disclose essential aspects in treatment preparation and execution.

Conclusion & Clinical Relevance

In difficult cases like teeth with root resorption, CBCT examination is crucial for assessment, treatment planning and engagement. Navigating through a three-dimensional imaging allows the clinician not only to predict, but also to develop the future management and procedures.

References

1.Abiangan, Z., Nasser, M., Mahdian, M., Fedorowicz, Z., & Marchesan, M. A. (2015). Interventions for the management of external root resorption. *Cochrane Database of Systematic Reviews*, (11) doi:10.1002/14651858.CD008805.pub3

2.Lava, M., Abbott, P. V., Pajarola, G., & Nair, P. N. R. (2000). Apical inflammatory root resorption: A correlative radiographic and histological assessment. *International Endodontic Journal*, *33*(6), 483-493. doi:10.1046/j.1365-2591.2000.00338.x

3.Patel, S., Durack, C., Abella, F., Shemesh, H., Roig, M., & Lemberg, K. (2015). Cone beam computed tomography in endodontics – a review. *International Endodontic Journal*, *48*(1), 3-15. doi:10.1111/iej.12270

FACULTY OF MEDICINE AND HEALTH SCIENCES

INTERNAL REPAIR OF EXTERNAL CERVICAL RESORPTION: A CASE REPORT

Drosos Liapis, Maarten Meire, Roeland De Moor, Mieke De Bruyne

DEPARTMENT OF ENDODONTOLOGY, DENTAL SCHOOL, GHENT UNIVERSITY, GHENT, BELGIUM

Aim

To describe the management of External Cervical Resorption of an upper central incisor and appraise the use of CBCT in the decision-making process.

Introduction

Several factors have been described in the aetiology of External Cervical Resorption (ECR)[1]. ECR management depends on the location, extent and accessibility of the lesion at the time of diagnosis.

Case Presentation

A 42-year-old female attended the dental department at Ghent University Hospital, Belgium, seeking treatment advice for the missing right lateral incisor, which she lost during a car accident 4 years ago. Radiographic examination (2D X-ray and CBCT) of the anterior region revealed a resorptive lesion in the right central incisor (Fig.1 & Fig.2). Upon further clinical and radiographic examination, tooth 11 appeared asymptomatic and vital, without signs of periradicular and periodontal pathosis. The resorptive lesion was classified as Class IV according to Heithersay[2] and Class 3Cd according to Patel[3]. Because of the small entry point and the confinement of the lesion within the root, an internal repair approach was selected[4]. Root canal treatment was performed under an operating microscope (Pico, Carl Zeiss, Germany) in two sessions. During the first session, root canal preparation was completed and a loose segment of the root canal wall was detected and removed with ultrasonic tips (EndoSuccess, Satelec, France) (Fig.3). Sodium hypochlorite 5% was used to arrest bleeding, dissolve granulomatous tissue and disinfect the root canal system. Calcium hydroxide was used to guide radiographically the progress of the canal preparation (Fig.4) and as an interappointment medication. After two weeks, the unaffected apical part of the canal was filled using gutta-percha and tricalcium silicate sealer (BioRoot RCS, Septodont, France) and the rest of the canal using Biodentine (Septodont). Composite (Clearfil AP-X, Kuraray, Japan) was used to seal the access cavity (Fig.5). Fig.6 shows the 6 months follow up.

Discussion

The patient suffered a car accident 4 years ago during which tooth 12 was lost. This might have been the predisposing factor for the ECR lesion. Thanks to CBCT it was possible to evaluate the extension of the lesion and to decide on the treatment approach.

Conclusion and Clinical Relevance

3-D images provide essential information during the decision-making process on whether an ECR-affected tooth can be preserved or should be extracted.

Fig.1: Pre-operative x-ray.

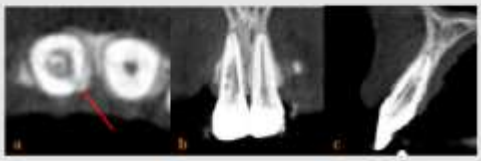

Fig.2 (a,b,c): CBCT view of the lesion. The entry point (2a) is located on the mesiopalatal surface (red arrow).

Fig.3 (a,b): Removed piece of the root canal wall.

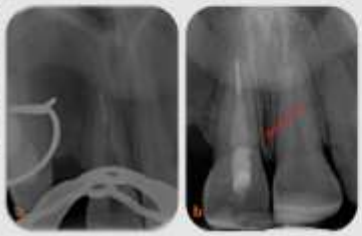

Fig.5 (a,b): Post-operative image. Note the filling of the entry point with Biodentine (red arrow).

Fig.4 (a,b): $Ca(OH)_2$ was used to assess the progress of the canal preparation.

Fig.6: 6 months follow-up

Contact

drosos.liapis@ugent.be
www.ugent.be

Universiteit Gent
@ugent
Ghent University

1)Heithersay GS. Invasive cervical resorption: an analysis of potential predisposing factors. Quintessence International 30, 83–95, 1999
2)Heithersay GS. Clinical, radiologic, and histopathologic features of invasive cervical resorption. Quintessence International 30, 27–37, 1999
3)Patel S, Foschi F, Mannocci F, Patel K. External cervical resorption: a three-dimensional classification. International Endodontic Journal 51, 206–14, 2018
4)Patel S, Foschi F, Condon R, Pimentel T, Bhuva B. External cervical resorption: part 2 – management. International Endodontic Journal, 51, 1224–1235, 2018

GHENT UNIVERSITY

Evaluation of intracoronal resorption of three impacted third molars using cone-beam computed tomography

Emel Olga Onay, Cemre Koc, Mete Ungor

Baskent University, Department of Endodontics, Ankara, Turkey

Aim: To present and discuss intracoronal resorption cases of bony impacted third molars with a view to guiding clinicians in diagnosis as well as describing the clinical and radiographic features of this condition.

Introduction: Pre-eruptive intracoronal resorption is rare and occurs in impacted teeth. A recent study utilizing cone-beam computed tomography (CBCT) revealed that this kind of resorption was prevalent in 15% of a Turkish population (1). The discovery is infrequent, and mainly due to routine radiographies (2).

Case Presentation

Case 1: A 77-year-old female patient was referred with the primary complaint of discomfort in the right side of her mandible. Radiographic examination revealed secondary caries in mandibular right second molar and second premolar teeth which restored with a fixed partial denture. The radiography results also showed radiolucency in the dental crown area of both maxillary right and left third molars which were impacted (Fig. 1). The affected teeth were symptomless and there was no sinus tract or communication between them and oral cavity. A CBCT was performed to better evaluate the impacted teeth.

The CBCT analyses showed that the defects extended through the full dentine thickness of the crowns (Figs. 2 and 3). A connection between the surrounding bone and the defect was noted in the distal and occlusal sides of maxillary right third molar (Fig. 2). The enamel was intact in maxillary left third molar (Fig. 3).

Case 2: An 82-year-old female patient was referred with the primary complaint of discomfort in the right posterior side of her maxilla. Radiographic examination indicated that the first molar had previously been treated endodontically. The radiography also showed radiolucency in the dental crown area of both maxillary and mandibular right third molars which were impacted and ectopically positioned (Fig. 4). The CBCT analysis showed a hypodense area related to the roots of the second molar and an intracoronal defect that located in the third molar of the same side extended to more than two-thirds of the thickness of the coronal dentin. Additionally, a small portion of the adjacent enamel was found to be affected by the resorption and a connection between the surrounding bone and the defect was noted in the distal and occlusal sides of maxillary right third molar (Fig. 5).

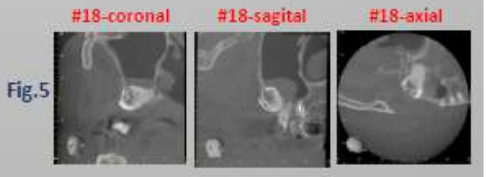

Discussion: The aetiology is unclear. The currently accepted hypothesis is that damage to the reduced epithelium of the enamel of the impacted teeth allows for the invasion of osteoclasts into the dentine, either through the rupture in the enamel or via communication near the enamel-cementum junction. The ectopic positioning of teeth or teeth with abnormal contact can cause local pressure, which may cause local damage to the protective layer of the tooth (3).

Conclusion & Clinical Relevance:

Intracoronal resorption may affect impacted third molars even in elderly patients. CBCT can be useful for diagnosing pre-eruptive intracoronal resorption defects because it provides an accurate representation of the internal anatomy. In both cases, considering the patient's age and the asymptomatic status, the choice of maintaining the tooth was considered the most appropriate.

References:

1. Demirtas et al. (2016) Scanning 38, 442-7.
2. Lenzi et al. (2017) Australian Dental Journal 62, 223-7.
3. Seow et al. (1999) Pediatric Dentistry 21, 332-9.

C14

Two-Year Follow-Up of a Delayed Reimplanted Avulsed Tooth: Case Report

Elif Akkol[1], Hüseyin Gündüz[1], Esin Özlek[1]
[1]University of Van Yüzüncü Yıl, Faculty of Dentistry, Departments of Endodontics

AIM: Avulsion is a type of traumatic dental injury which occurs frequently in the upper anterior teeth of children of 7-9 years old (1). The ideal treatment procedure is the early replantation of the avulsed tooth. This case report includes replantation of the avulsed maxillary left central of male patient after dental trauma.



CASE PRESENTATION: An 11-year-old male patient visited to our clinic complaining of an avulsed maxillary left central tooth four hours after the accident at school. Medical history revealed that the avulsed tooth had been kept in milk for those four hours. The intraoral and radiographic examination showed that the socket was filled with clot, there was mobility in the teeth 11 without any fracture in the alveolar bone. First, the clot was removed from the socket and the avulsed tooth was placed into the socket by finger pressure. Afterwards, the incisor teeth were fixed with ribbond splint (Ribbond Inc., Seattle, WA, USA) for 3 weeks. 7 day after splinting, the canal treatment of the left and right central teeth was begun and Calcium hydroxide paste was placed in the root canals. On day 14, the root canal filling was done and the splint was removed from the teeth. Clinical examination performed 6, 12 and 24 month later showed that the tooth was asymptomatic and radiographic examination showed no signs of root resorption.


After root canal treatment


12 months after treatment


24 months after treatment


6 months Follow up: intraoral photograpy


24 months Folllow up: intraoral photograpy

DISCUSSION: Resorption is an undesirable result of traumatic dental injuries. It is frequently seen in late replantation cases, similar to this case. Splinting of the tooth after the avulsion may affect the prognosis of the tooth in positive sense. Proper reimplantion of teeth has been shown to require splinting to prevent increased mobility. In this case, Ribbond splint type was preferred because of its elasticity, translucency, adaptability, adherence, and resistance to traction and impact(2).

CONCLUSION: The most important factor determining the prognosis in avulsion cases is the replantation of the tooth as soon as possible. While negative consequences like replantation of the tooth outside the surface, replacement and external inflammatory resorption may be seen, especially cases like this, which was avulsed and replaced late, clinical and radiographic examination in long-term showed that the tooth was asymptomatic and healthy healing was observed in the periapical tissues.

1. Sardana D, Goyal A, Gaube K. Delayed replantation of avulsed tooth with 15-hours extra- oral time: 3-year follow-up. Singapore Dent J 2014; 35: 71-76.
2. Andersson L, Andreesen JO, Day P, et al. International Association of Dental Traumatology guidelines for the management of traumatic dental injuries: 2. Avulsion of permanent teeth. Dent Traumatol. 2012; 28: 88-96.

C15

ENDODONTIC TREATMENT OF THE RADIX ENTOMOLARIS: A CASE REPORT WITH CBCT EVALUATION

Marijana Popović Bajić, Slobodan Jovanović, Slavoljub Živković, Nevenka Teodorović
Department of Restorative Dentistry and Endodontics,
School of Dental Medicine, University of Belgrade

AIM

The aim of this study is to present a case of permanent mandibular second molar with an additional third root (radix entomolaris) in a Caucasian patient.

INTRODUCTION

The removal of all vital and necrotic pulp tissue and microorganisms from the root canal system is essential for the success of endodontic treatment. Normally the permanent second molar has two roots, mesial and distal with two mesial and one distal canal. But, mandibular molars may have an additional root located either distobucally (radix paramolaris) or distolingually (radix entomolaris-RE).

CASE PRESENTATION

A 23 year old female reported to the Department of Restorative Dentistry and Endodontics of the School of Dentistry, Belgrade, complaining of pain in the right posterior tooth region of the lower jaw.

Clinical examination revealed a carious lesion of the right permanent second mandibular molar. The tooth 47 was more responsive than control tooth 37 after electric pulp testing. Ortopantomography showed carious lesion encroaching on the pulp space and the presence of an additional distal root. A diagnosis of symptomatic irreversible pulpitis was made.

The caries was removed, and access opening was performed. Only one canal orifice in the mesial root and one in the distal root were initially located. The access cavity was modified from triangular into a more trapezoidal shape and another orifice was located distolingually. Initial instrumentation was done with K file ISO number 10 and working lengths were determined radio-graphically and electronically with apex locator Root ZX, (J. Morita, Kyoto USA). The chemo-mechanical instrumentation was performed with rotary MTwo files (VDW, Germany) and massive irrigation of sodium hypochlorite (1%). Obturation of the root canals was performed using gutta percha points and AH plus sealer (Dentsply, Switzerland). A cone beam computed tomography (CBCT) was performed (because of the preoperative assessment in orthognathic and TMJ surgery) and it showed absence of second mesial canal and presence of extra distolingual root with a greater curvature. The tooth was restored with glass ionomer cement (Fuji IX) and composite filling (Gradia direct).

Fig. 1

Figure 1. *Control radiograph after obturation.*
Figure 2. CBCT
a- cross section
b- presence of distolingual root with curvature
c- correct obturation of root canals

Fig. 2a

Fig. 2b

Fig. 2c

DISCUSSION

Three rooted molar traits have a high degree of genetic predisposition in the Eskimo population and in Eskimo-Caucasians mixture (1). The presence of RE is high among Taiwanese (Chinese) population (21,1%-33,33%) and bilateral incidence is ranging from 53,65 to 68,57% in them (2). Low prevalence of RE is notice in African, Eurasian and Indian population (<5%). RE may also be present in the first, second and third molar, being less prevalent in second molar (3).

Radiographically, the third root is visible in most of cases, but occasionally it may be missed because of its slender dimension or overlapping with distal root.Visual aids such as a loupe, intraoral camera or dental microscope can also be helpful. CBCT is very useful in the diagnosis of teeth with complex anatomies (4).

CONCLUSION & CLINICAL RELEVANCE

A case of RE can be also diagnosed by a careful evaluation of preoperative radiographs (taken at different angulations) and careful examination of the floor of the pulp chamber. The conventional triangular access cavity opening must be modified to a trapezoidal form in order to properly locate canal orifice of the extra root and to avoid "missed" canals.

REFERENCES

1. Curzon ME (1974) Miscegenation and the prevalence of three-rooted mandibular first molars in the Baffin Eskimo. Community Dent Oral Epidemiol 2: 130-131.
2. Tu MG, Tsai CC, Jou MJ, Chen WL, Chang YF, Chen SY,et al. Prevalence of three-rooted mandibular first molars among Taiwanese individuals. J Endod. 2007;33:1163-6.
3. Visser JB.BeitragzurKenntnis der menschlichenZahnwurzelformen. Zürch: Rotrag, 1948.
4. Patel S, Durack C, Abella F, Roig M, Shemesh H, et al. (2014) European Society of Endodontology position statement: The use of CBCT in Endodontics. Int Endod J 47(6): 502-504.

Biodentine®, CBCT and operative microscope in apical surgery – a case report

Cardoso M.[1,2]; Paulo M.[1]; Noites R.[1,2]

1 Department of Endodontics of Health Sciences Institute – Universidade Católica Portuguesa, Viseu Portugal.

2 Center for Interdisciplinary Research in Health (CIIS), Institute of Health Sciences (ICS), Viseu, Portugal. Universidade Católica Portuguesa, Viseu Portugal.

Introduction

Periapical lesions are chronic inflammatory pathologies at the apical level. When it is not possible to perform a conventional endodontic retreatment, apical surgery is a good alternative for the maintenance of a tooth with apical lesion. Biodentine® is a bioactive material based on calcium silicate that can be used in dentin repair, applied in perforations or resorption, apexification and apical compactation.

Case Presentation

A 39-year-old female patient presented with an abscess and referred pain on the first left mandibular premolar. Radiographic examination (orthopantomography and periapical radiograph) showed a periapical lesion, a non-treated canal and a fiber post. A CBCT confirmed the presence and the localization of the second canal. A fenestration on the apical area of the tooth was also observed. After removing granulation tissue, the canals were identified. The buccal canal contained a plastic core of a gutta-percha transporter and the lingual had not been prepared. Afterwards, the apical 3mm were prepared with ultrasonic tips (ProUltra™ #3 – Dentsply Maillefer, Switzerland) and obturated with Biodentine ®. The flap was repositioned and sutured with Surgycril™ PGA 5/0.



Figure 1: Preoperative ortopantomography.

Figure 2: (A and B) periapical radiographs (A) preoperative, (B) two-years follow-up; (C and D) CBCT sagital views (C) preoperative (D) two-years follow-up.

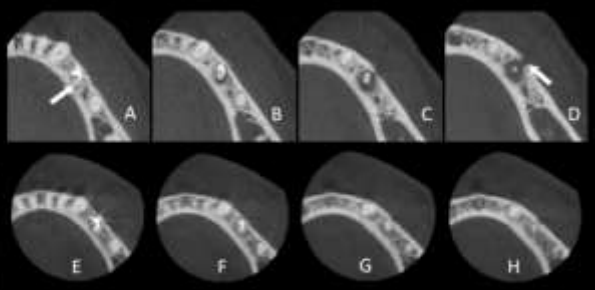

Figure 3: CBCT images. (A to D) preoperative axial images from coronal (A) to apical (D), with presence of a second canal (arrow) in a distolingual position and of an apical lesion in images B to D with buccal fenestration in D (arrow); (E to H) two-years follow-up axial images from coronal (E) to apical (H).

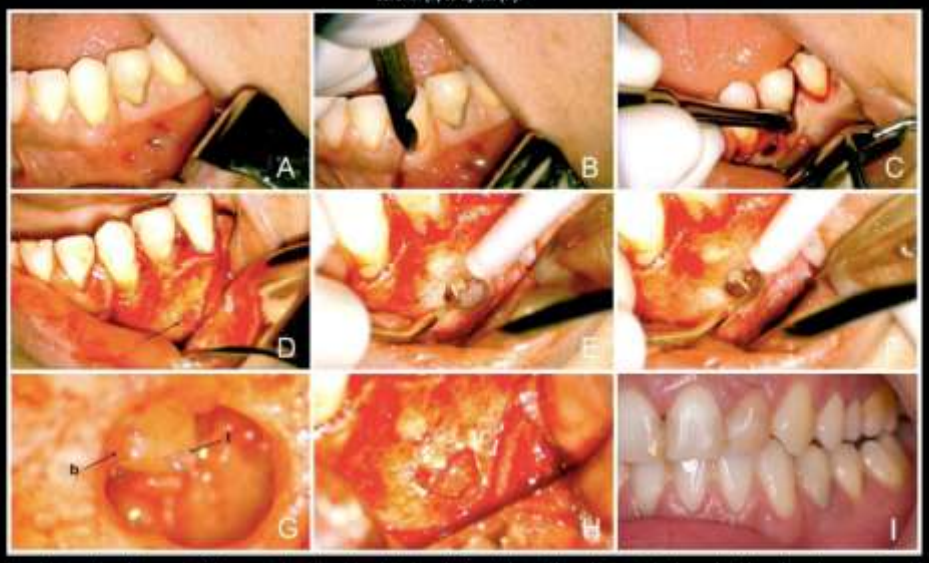

Figure 4: Operative photographs (A) Preoperative; (B) incision; (C) triangular flap; (D) apical buccal fenestration (arrow); (E) buccal canal preparation with ultrasonic tips; (F) lingual canal preparation with ultrasonic tips; (G) buccal (b) and lingual (l) after preparation; (H) retrograde filling with Biodentine ®; (I) two-year follow.

Discussion

After 2 years, there was no symptomatology and the lesion diminished comparing with preoperative radiographs and CBCT images predicting a good evolution. In this case the non surgical retreatment was attempted but due to the presence of a difficult to remove glass fiber post the second canal was not detected and apical surgery was planned.

Conclusion & Clinical Relevance

The use of CBCT allowed a more correct treatment planning. The use of microscope allowed a minimalist osteotomy, and the perfect visualization of the canals. We can conclude that the surgical microscope and CBCT were essential for the chosen treatment plan. Biodentine was an effective option in this case.

References

1. Thomas van Arx, Apical surgery: A review of current techniques and outcomes, The Saudi Dental Journal, Volume 23, Issue 1, 2011, Pages 9-15, ISSN 1013-9052;

2. Caires G, Jakiuk J, Tavares W-D, Machado F, Buscher Y. Use of a new retrograde filling material (Biodentine) for endodontic surgery: two case reports. International Journal of Oral Science. 2014;6(4):255-259;

3. Dylan Walkenda, Merij Varapinar Kazandag, and Evder Kazazoglu, "A Review on Biodentine, a Contemporary Dentine Replacement and Repair Material," BioMed Research International, vol. 2014, Article ID 160953, 10 pages, 2014.

C17

CASE SERIES

INTENTIONAL REPLANTATION

Beatriz Pereira, Cátia Manilha, António Ginjeira
Faculdade de Medicina Dentária, Universidade de Lisboa
Department of Endodontics

ESE 2019 VIENNA
11 - 14 SEPTEMBER

AIM

To present 3 cases of intentional replantation

INTRODUCTION

Intentional replantation has been defined as the deliberate extraction of a tooth and after evaluation of root surfaces, endodontic manipulation and repair, placement of the tooth back into its original socket. (1)
Indications for this procedure include treatment of vertical root fracture, crown-root fracture, external root resorption, proximity to delicate anatomic structures, presence of conditions for which nonsurgical retreatment is impracticable, or perforation that is not accessible via a conventional microsurgery. Also, in persistent chronic pain, accidental iatrogenic avulsion, involuntary orthodontic extrusion, and previous failure of nonsurgical retreatment and apical surgery. (1, 2, 3)
The contraindications to intentional replantation are periodontal involvement, an extensively carious tooth, furcation involvement, or loss of septal bone and long/curved roots. (2, 4)
This procedure has been reported to have a survival rate of f 89.1%. (3)

CASE #1

37 years old male patient, referred after a distal – palatal root perforation that had been previously repaired during retreatment of the tooth 25. Although patient was asymptomatic at the time and due to the presence of large persistent radiolucency, was decided to perform endodontic microsurgery. In May 2013, the intentional replantation was performed to repair the perforation using grey MTA. After a 9 months follow-up, the tooth was functional, asymptomatic and showing signs of decreasing radiolucency.

CASE #2

35 years old female patient with a diagnosis of Pulp Necrosis and Chronic Apical periodontitis on tooth 26, referred for endodontic treatment in September 2012. Patient returned in January 2018, with a new crown and post, complaining of swelling. After CBCT it was detected a perforation on the distal palatal aspect of the palatal root, inaccessible by conventional endodontic microsurgery due to being blocked by distal buccal root. Replantation performed in February 2018, closing the perforation and retro-obturation with White MTA. 4 months later, patient returned for control and presented asymptomatic and the tooth was functional.

CASE #3

44 years old male patient, presented in July 2017 with symptomatic apical periodontitis on tooth 21. The tooth had a porcelain crown and a cast post. It was proposed orthograde retreatment, but as it was not possible to remove the cast post, retrograde approach was done through apical surgery. In October 2017 was diagnosed a Distal Palatal resorption, and Intentional replantation was performed in November. Tetracycline and 90% was applied as per guidelines, and the sealing was done with White MTA. The tooth was then splinted with Flowable composite. Patient returned after 8 months for control and presented asymptomatic and the tooth was functional.

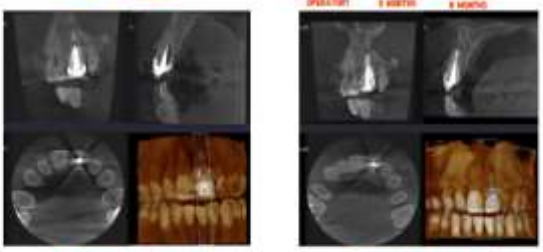

DISCUSSION

Both the handling and the extraoral time are critical to ensuring maximum vitality and survival of PDL cells which is a critical factor influencing the successful healing (1). The risk of complications was 1.7 times higher for teeth replanted in more than 15 minutes and when inferior to 15 minutes, has been associated with higher survival and fewer complications. (3, 5) The risk of ankylosis (0 – 7%) or external root resorption (3 – 5%) are low, especially when extraoral time is kept to a minimum. (3)
Healing outcomes comprises no periapical radiolucency present, no external root resorption or ankylosis, no signs/symptoms, and normal probing depths. With a success ranging from 72.4% to 94.4% , this procedure has predictable results.(3)

CONCLUSION & CLINICAL RELEVANCE

Intentional replantation is a procedure with good outcomes and should be considered as an alternative to extraction in hopeless cases.

REFERENCES

1 Barker B.D. Intentional Replantation Techniques: A Critical Review. J Endod 2010;44:14-2
2 Bender I.B., Rossman L.E. Intentional replantation of endodontically treated teeth. Oral Surg Oral Med Oral Pathol 1991;70:625-30
3 Plotzker A. A Systematic Review of the Survival of Teeth Intentionally Replanted with a Modern Technique and Cost-effectiveness Compared with Single-tooth Implants. J Endod 2017; 43(12):1963-1968
4 Grossman L.I. Intentional replantation of teeth. JADA 1986;112:1111-1118
5 Chu S.Y. et al. Retention and Healing Outcomes after Intentional Replantation. J Endod 2016; 42(8):909-15

ESE 2012 VIENNA 12-14 SEPTEMBER

Periapical healing after laser-assisted irrigation activation with PIPS™ technique: A report of three cases

Ozbay Y[1], Akbal Dincer G[2], Turkyilmaz A[2], Erdemir A[2]
[1]University of Kyrenia, Faculty of Dentistry, Department of Endodontics
[2]Kirikkale University, Faculty of Dentistry, Department of Endodontics

Aim

To present treatment and periapical healing period of three cases with periapical lesions which PIPS™ technique was applied to assist irrigation activation.

Introduction

The development of instruments in endodontics and current technologies have made it possible to protect the tooth in many cases where tooth extraction was previously preferred. Laser technology and PIPS™ technique, as one of the most modern applications of this technology,can contribute to canal disinfection, which is very critical in the treatment of the teeth associated with periapical lesions. Because of the streaming effect of PIPS™ and its ability to move irrigation solutions three-dimensionally, the technique offers an effective debriding and decontamination of the root canal system. Furthermore, it is proven that PIPS™ is a safe technique owing to the positioning of the tip in the coronal orifice only and minimally ablative energy level need.[1] The efficacy of PIPS™ technique used with Er:YAG laser is presented in this case report.

Case Presentation 1

First Appointment

*A 34-year old male
*Periradicular lesion related to #44
*Slight spontaneous discomfort, no swelling, not tender to percussion
*Failed root canal treatment (Fig. 1)
*CBCT scan, (Fig. 2 and 3) confirmed missed root canal
*Previous root canal filling was removed (Fig. 4).
*ProTaper Universal rotary system (Dentsply Maillefer,Ballaigues Switzerland), 5% NaOCl (Wizard; Rehber Kimya,Istanbul,Turkey) and 17% EDTA (MD-cleanser,Meta Biomed,Chungju, Korea)
*Dressing with $Ca(OH)_2$,Temporary filling

Second Appointment

***Irrigation activation:** Er:YAG laser (LightWalker AT, Fotona, Ljubljana, Slovenia) in assistance with PIPS™ technique
*300 µm PIPS™ tip (Fig. 5)
Laser settings: 0.3 W, 20 mJ pulse rate, 15 Hz frequency (Fig. 6)
1. 3 ml 30s 17% EDTA
2. 3 ml 30s Distilled water
3. 3 ml 30s (3×) 5 % NaOCl
4. 3 ml 30s distilled water
*Solutions were delivered continuously with simultaneous laser activation
*ProTaper Universal Gutta-Percha Points (Dentsply Maillefer, Ballaigues, Switzerland)
*Coronal restoration (Tokuyama Dental, Tokyo, Japan) (Fig 7)

Follow-up

*Not sensitive to percussion or palpation testing
*Radiographic evidence of bony repair was clear at 6 month (Fig . 8), 12 month (Fig. 9) and 24 month (Fig. 10)

Case Presentation 2

First Appointment

*18-year old male
*Pain and swelling in mandibular incisor region.
*#41; Tender to percussion, non-vital (Fig 1).
*Preparation and disinfection procedures same as Case 1(Fig 2)

Second appointment

*Previous complaints were relieved.
*Irrigation, activation, obturation and coronal restoration procedures were completed same as Case 1 (Fig 3).

Follow-up

*Radiographic evidence of significant healing of the periapical lesion at 6-month (Fig. 4) and 12-month (Fig. 5)

Case Presentation 3

First Appointment

*29-year old male
*Slight pain in #31, no swelling, not tender to percussion
*#31; non-vital, periradicular lesion (Fig1).
*Root canal preparation, disinfection and canal dressing procedures were same as Case 1 and Case 2 (Fig 2).

Second appointment

*Final irrigation, activation, obturation and coronal restoration procedures were completed same as Case 1 and 2 (Fig. 3).

Follow-up

*Clear periapical healing at 6-month (Fig. 4) and 12-month (Fig. 5)

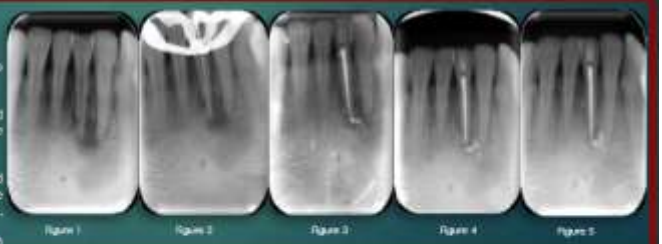

Discussion

Effective decontamination of root canals includes eliminating both planktonic bacteria and biofilm which operator may fail to achieve since isthmuses and ramifications are blocked by dentin chips, infected pulp tissues and residual endodontic filling material.[2] PIPS™ enhances disinfection by activating the irrigation solutions and causing a turbulence effect on solution rather than a direct laser irradiation.[3,4]

Conclusion & Clinical Relevance

Although healing of a periapical lesion depends on a range of variables, laser activated irrigation with PIPS™ technique may speed up the process by three dimensional irrigation flow throughout the root canal and affect the healing period positively.

References

1. Olivi, G. and E. DiVito. Photoacoustic endodontics using PIPS™: experimental background and clinical protocol. J. Laser Health Acad. 2013. 1: p. 20-25.
2. Ozbay, Y. and A. Tosiene. Effect of several laser systems on removal of smear layer with a variety of irrigation solutions. Microsc. Res. Tech. 2018. 81(10): p. 1214-1222.
3. Olivi, G., et al., Disinfection efficacy of photon-induced photoacoustic streaming on root canals infected with Enterococcus faecalis: an ex vivo study. J Am Dent Assoc. 2014. 145(8): p. 843-8.
4. Olivi, G., R. De Moor, and E. DiVito, Advanced Laser-Activated Irrigation: PIPS™ Technique and Clinical Protocols. in Lasers in Endodontics: Scientific Background and Clinical Applications. 2016. Springer p. 219-291.

yagiz.ozbay@kyrenia.edu.tr

MANAGEMENT OF PERSISTENT SWELLING: A JUGGERNAUT OF POST REMOVAL, MTA PLUGS AND ROOT REINFORCEMENT

E. AlSaleh[a], A. Dutta[b]

Aim

Discuss nonsurgical root canal retreatment of maxillary central incisors with coronal disassembly, orthograde MTA apical plugs, root reinforcement and PFM crown.

Introduction

Root canal treated teeth with long standing periapical infections can be difficult to manage clinically. The approach to preserve these teeth involves utilizing the benefit of NSRCT including irrigant activation, the biocompatible and bioactive properties of calcium silicate cements and reinforcing weak roots.

Case Presentation

56 y/o male with history of intraoral labial swelling related to crowned maxillary central incisors referred for specialist management in a hospital setting.

History & Clinical Findings

- RCT, cast post/core and crowns 11 & 21 in year 2001 after sports trauma
- 2016-2018 recurrent firm swelling (20 mm, smooth surface, no sinus tract) in labial sulcus across the midline, managed with antibiotics by GDP twice before hospital attendance.
- 11 & 21 TTP and labial soft tissue tenderness
- Fig. 3, 4 & 5: 11 & 21 crowns, short wide cast posts, suboptimal root fillings with voids, 21 distinct PARL, 11 diffuse PARL

Treatment

- 11 & 21 crowns and posts dismantled using burs to section the posts. No success with ultrasonics/Ruddle post removers.
- Under RD isolation, gutta percha removed with H files
- 1% NaOCl passive ultrasonic irrigation (PUI), $Ca(OH)_2$ and Odontopaste® intracanal medication over several visits and 17% EDTA PUI in penultimate and final visit (as penultimate rinse), until swelling disappeared and sinus tract developed.
- 6mm orthograde ProRoot® MTA apical plugs (fig 11)
- Fiber posts and dual-cure composite resin cement for root reinforcement, composite build up and provisional crowns (fig. 12-17)
- Remargination of provisional crowns in subsequent visits (fig. 18)

Discussion

Cleaning a wide canal (initial apical size 60) with persistent pus draining through the apex over several visits necessitated further apical enlargement to facilitate bacterial load reduction and this resulted in an open apex (1). The treatment included passive ultrasonic irrigation (2) and interappointment intracanal medication calcium hydroxide over several visits followed by Odontopaste® which contains zinc oxide, 5% clindamycin hydrochloride and 1% triamcinolone acetonide to help further reduce the microbial load (3), and in turn the swellings.

Teeth with an open apex and weak root require intraradicular reinforcement in the form of apical bioactive MTA plug and fiber post cemented with resin composite cement (4). Chronic apical abscesses are associated with complex bacterial biofilm and the infection might extend to the extraradicular environment (5). Considerations for future possible surgical treatment helped in current management by replacing the GP backfill with longer MTA plugs.

Conclusion & Clinical Relevance

This case report demonstrated the utilization of different treatment modalities to help achieve significant improvement in the patient's symptoms. Future monitoring of patient's symptoms, clinical & radiographic presentation will be undertaken. The extra length of the orthograde MTA plug will facilitate ease of any future surgical management, should the orthograde retreatment fail due to extradicular biofilm/true cyst related causes.

Pre-operative Photographs and Radiographs

Retreatment Photographs and Radiographs

Restorative Photographs and Radiographs

References

1. Sani HR, Tewari S, Sangwan P, Duhan J, & Gupta A (2012) Effect of different apical preparation sizes on outcomes of primary endodontic treatment: a randomized controlled trial. Journal of endodontics, 38(10), 1409-1416.
2. Nakamura VC, Pinheiro ET, Prado LC, et al. (2018) Effect of ultrasonic activation on the reduction of bacteria and endotoxins in root canals: a randomized clinical trial. International endodontic journal, 51, e12-e22.
3. Pourzar B, Zinn P, Retrouvey J, Cathro P (2018) Comparative efficacy of endodontic medicaments and sodium hypochlorite against Enterococcus faecalis biofilms. Australian dental journal, 63(1), 206-216.
4. Tait CM, Ricketts DN, Higgins AJ (2005) Weakened anterior roots—intraradicular rehabilitation. Br Dent J, 198, 609-617.
5. Ricucci D, Loghin S, Gonçalves LS, Siqueira JF (2018) Histobacteriologic Conditions of the Apical Root Canal System and Periapical Tissues in Teeth Associated with Sinus Tracts. J Endod 44, 405-413.

a: MClinDent (Endo) Postgraduate dentist, b: Clinical Lecturer in Endodontology & Hon. Consultant in Restorative Dentistry

C20

Diagnostic dilemma: Toothache or Non-odontogenic pain?

Yousif Alhowli[1], Arindam Dutta[2]

[1] Second year postgraduate dentist (MClinDent Endodontology) [2] Consultant in Restorative Dentistry

CARDIFF UNIVERSITY
PRIFYSGOL CAERDYDD

Aim:

- **Discuss the differential diagnosis of orofacial pain associated with multiple painful teeth with symptomatic apical periodontitis and crack concomitant with non-odontogenic pain presentation .**

Introduction:

- **The distinction between pain related to teeth and from non-dental sources can be challenging for the dental practitioner. The major sources of odontogenic pain are related to either pulpal or peri-radicular pathology, or indeed inflammatory changes along the periodontal ligament. The nature of such pain is extremely variable in intensity, duration, character, localization, radiation and progression. Non-odontogenic pain may have several reasons such as TMD, migraine, sinusitis, neuralgias, temporal arteritis and atypical facial pain. When a patient suffers from more than one type of pain, this can prove challenging and require a multidisciplinary approach toward diagnosis including an endodontist, oral medicine specialist, a maxillofacial surgeon, neurologist or also a radiologist. The pain clinic is a common pathway for managing such patients.**

Case Presentation:

- 29 year old female patient referred to Cardiff Dental Hospital from her general dental practitioner (GDP) for endodontic retreatment of the LL6. Patient complained of pain on the left side of her face and the sites included her lower jaw, upper jaw, pain behind her eye, her forehead and also on her left temple which radiated down in to the neck
- She had also complained of tingling sensation in her fingers.
- Medically, she had suffered from heaviness and pain constantly behind the left eye over the past year.
- Extra-oral examination was nil of note at the TMJ and muscles of mastication.
- Intra-orally, the LL6 and UL6 had large amalgam restorations and localized tenderness on percussion was noted on the LL6, which was diagnosed as being previously root treated with symptomatic apical periodontitis.
- Concurrently, the patient also attended with her general medical practitioner, and had received CT scan of the head, CT Venogram of the head and brain, MRI of the head and MRI of the cervical spine to help diagnose her pain condition (Fig 7a, b, c).

Pre-operative photos (Figure 1)

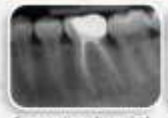

Pre-operative radiograph of LL6 (Figure 2a)

Post-operative radiograph of LL6 (Figure 2b)

Post-operative radiograph of UL6 (Figure 3)

Treatment done:

- Non-surgical root canal retreatment for LL6 was successfully completed over three visits using RECIPROC® Blue, 1% NaOCl for disinfection and 17% EDTA for smear layer removal. Interappointment dressing of calcium hydroxide was placed in the canals. Obturation was done in continuous wave technique. A composite core was placed (Fig 2a, 2b).
- Whilst awaiting indirect restoration for the LL6, the patient received de novo RCT for the UL6 with her GDP, as it had developed irreversible pulpitis. (Fig 3).
- The patient complained of dull ache on the left side of her face when she attended for onlay preparation for the LL6. She also complained that neither of the recently treated teeth (UL6 & LL6) had settled.
- Upon examination, a crack was noted on the distal margin ridge of the UL6 (Fig. 4) & confirmed with the Tooth Sleuth test. No separation of cusps was noted. No localised increase in probing depth was recorded either adjacent to the crack. An orthodontic band was placed around the tooth, which helped provide some relief when she was reviewed one week later. (Fig. 5).
- Her medical investigations had revealed abnormal filling of her cavernous sinus on the left side, which was demonstrated through the venogram. This would be the most likely reason for the pain behind her eye.
- Her MRI scan for the head and cervical spine did not reveal any abnormalities and vertebral discs and intervertebral spaces were normal.
- The crack line on the distal of the UL6 was explored and found to extend subgingivally (Fig. 6a). Piezoelectric ultrasonic tips were used to explore the crack with an indeterminate apical extension (Fig. 6b). This was sealed with composite (Fig. 6c).
- Onlay preparations for lithium disilicate were completed for both UL6 and LL6 in the hope that adhesive cuspal coverage restorations will help bond the tooth parts together (Fig.8).

Fractured UL6 (Figure 4)

Band placed (Figure 5)

(Figure 6a)

(Figure 6b)

(Figure 6c)

(Figure 7a)

(Figure 7b)

(Figure 7c)

Final onlay preparations with the impressions (Figure 8)

Discussion:

- At initial examination, even though the treatment for this patient from an endodontic perspective seemed to be easy, there were several factors related to pain diagnosis that were revealed as our treatment progressed.
- Periapical disease is a well known cause of odontogenic pain, but persistent post-endodontic pain has been reported (1) and its causes may include residual disease, cracks, complex regional pain syndrome type II, amongst others. Predictive factors for persistent post-endodontic pain have included patients attitudes towards pain, female sex, presence of preoperative pain, small pre-operative periradicular radiolucencies, presence of a crack and history of chronic pain (eg TMD, migraine, muscle pain in the neck and shoulder) (2, 3). Our patient had several such predisposing factors which might have contributed to her presentation even after good quality RCT.
- The presence of a crack predisposes the tooth receiving endodontic treatment to be at 11 times higher odds for being lost (4). Even so, RCT followed by an adhesive indirect restoration was carried out in the first instance as recent evidence has shown high survival rates for such teeth at one year (5). The crack was explored and found to extend subgingivally, though a pocket was not found. The age of the patient and the restorative cycle of a replacement tooth were both influencing factors for deciding in favor of tooth retention.
- Her complaints of neck pain were investigated medically with a MRI scan and with normal findings (Fig. 7b). This pain could be related to the large neck and shoulder muscles, such as the trapezius and deltoid, being in intermittent spasm which could explain the tingling sensation in her fingers.
- The findings with the cavernous sinus vis a vis eye pain are related to the anatomical position of this structure within the sella turcica of the pituitary fossa of the petrous part of the temporal bone. Several cranial nerves that are in intimate relationship to the sinus such as the oculomotor, abducens, trochlear and the ophthalmic division of the trigeminal nerve supply the eye and its associated muscles. Disturbances to blood flow (Fig 7c) may affect these neural structures resulting in pain.
- There was no evidence of cavernous sinus thrombosis (CST). This has also been related to the venous plexus which is often in close relation to teeth. Dental infections have been reported to cause CST, but could be excluded in this case owing to the radiological findings.
- The cavernous sinus pathology could be managed by a neurosurgeon and an angiogram has been suggested for reaching definitive diagnosis, as the vessels that supply the cavernous sinus have been found patent.
- Should the patient's dental/neck ache persist, medical management could include drugs such as tricyclic antidepressants (e.g. Amitriptyline /Nortriptyline) or Selective Non-Serotonin Reuptake inhibitors (e.g. Duloxetine). Extraction for the cracked tooth may be the last resort.

Conclusion:

- **The effective management of orofacial pain requires not only endodontic skills, but rather also a broad diagnostic ability coupled with teamwork including medical and other dental specialties.**

References

1. [illegible]
2. [illegible]
3. [illegible]
4. [illegible]
5. [illegible]

Biodentine in indirect and direct pulp capping – a case report

Joanna Kunert[1], Elżbieta Bołtacz-Rzepkowska[1]
Marta Kunert[2], Monika Łukomska-Szymańska[2]

Medical University Lodz, Conservative Dentistry Department[1]
Medical University Lodz, General Dentistry Department[2]

Aim

Presentation of treatment results of indirect and direct pulp capping with Biodentine.

Introduction

Biological therapy of the pulp is intended to preserve its vitality and avoid or delay root canal treatment. The application of calcium silicate base materials (CSMs) in indirect and direct pulp capping may stimulate the regeneration of vital pulp cells. CSMs, due to their high bioactivity, biocompatibility and sealing ability, enable us to achieve satisfactory therapeutic effects.

Case Presentation

A 24-year-old male patient came for the treatment of teeth 36 and 46. Diagnostic assessment as well as a radiograph showed signs of extensive carious lesions class II OD (Fig.1, Fig 4). In both cases, the proper pulp response to the stimulus and normal condition of periapical tissues was found. On the basis of a clinical examination, the young age of the patient and the lack of health-related contraindications, a decision was made to carry out biological treatment with Biodentine. After preparation, the cavity in tooth 46 was left with point demineralised dentin and then filled with Biodentine (Fig.2). In tooth 36, the pulp was exposed during the preparation of the cavity floor. The procedure of direct pulp capping was also performed with Biodentine. (Fig. 5).

At the follow-up visit, 6 months later, teeth 36 and 46 were tested positive for sensitivity to ethyl chloride and negative for percussion. Radiographs did not show any pathological findings apically. In tooth 36, the dentinal bridge was visible in the X-ray image (Fig. 6).

Discoloration and partial loss of the superficial layer of Biodentine were found. The Biodentine was partially removed leaving it in the bottom of the cavity were filled with Equia Forte Fill material (Fig. 3 and Fig. 6). The treated teeth were left until the following check up, 3 months.

Case 46			Case 36		

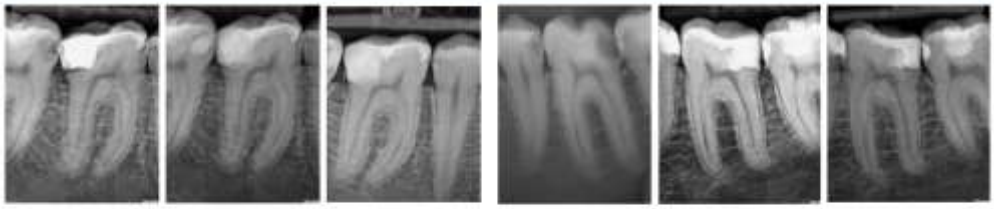

Fig. 1 Fig. 2 Fig. 3 Fig. 4 Fig. 5 Fig.6

Discussion

In the presented case, the decision to conduct biological treatment in deep carious cavities in indirect and direct pulp capping allows us to preserve the pulp's vitality.

Conclusion & Clinical Relevance

Trials of biological pulp therapy should be undertaken in deep carious cavity treatment. The pulp's reaction was within the normal limits, no pathological lesion in the periapical region on radiograms, the young age and good medical status were all favorable factors.

However, in long term observations Biodentine reveals poor mechanical properties, especially in restorations exposed to high occlusion forces.

References (max 5)

1. Giraud T et all. Tricalcium silicate capping materials modulate pulp healing and inflammatory activity in vitro. J Endod. 2018 Nov;44(11):1686-1691.
2. Brizuela C et all. Direct pulp capping with calcium hydroxide, minaeral trioxide aggregate, and biodentine in permanent young teeth with caries: A randomized clinical trial. J Endod. 2017 Nov;43(11):1776-1780
3. Lipski M et all. Factors affecting the outcomes of direct pulp capping using Biodentine. Clin Oral Investig. 2018 Jun;22(5):2021-2029.

C22

SAPIENZA
UNIVERSITÀ DI ROMA

INFLUENCE OF ROTARY GLIDE PATH ON TORQUE IN A SINGLE INSTRUMENT TECHNIQUE

Marco Seracchiani[1], Massimo Galli[2], Valerio Ferri[1], Dario Di Nardo[2], Gianluca Gambarini[3], Luca Testarelli[4].

1 - Student, Sapienza University of Rome, Dept. of Oral&Maxillofacial Science
2 - DDS, PhD, Sapienza University of Rome, Dept. of Oral&Maxillofacial Science
3 - Professor, MD, PhD, Sapienza University of Rome, Dept. of Oral&Maxillofacial Science
4 - Professor, DDS, PhD Sapienza University of Rome, Dept. of Oral&Maxillofacial Science

AIM

The aim of the present poster is to present and clinically evaluate the influence of glide path on torque developed by Nickel Titanium Rotary in a single instrument technique and instrumentation time

INTRODUCTION

The use of low torque instrumentation has been proposed in the past to increase safety of root canal treatment (RCT). However in most of cases low torque limit did not allow instrument to progress easily and reach working length.

In order to keep as low as possible the torque reached during instrumentation, different techniques has been proposed. One of this technique is the initial use of rotary glide path instruments, as shown by many studies. This advantage could be more relevant in single file rotary techniques where one instrument is subjected to all stresses .

This poster aims at presenting and clinically evaluating the influence of rotary glide path on torque developed during shaping with S-one rotary instruments (Fanta Dental, Shangai, China).

METHODOLOGY

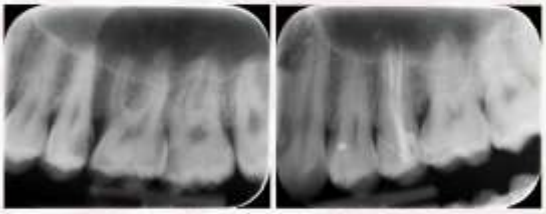

Instruments were used in 20 bi-canlar upper premolar cases with an endodontic motor (Eighteeth, Changzhou City, China) and following the indicated setting: 350 Rpm and 1.5 Ncm. The palatal and the vestibular canals of each teeth were randomly divided into two groups A and B, to avoid influence due to dentinal hardness and anatomical complexities. Each groups was instrumented with a different technique. The mean torque was registered and compared. The instrumentation time for both the operative technique was recorded with a digital chronometer with a digital chronometer (1/10s). Data were recorded and statistically analysed. The comparison of Mean Torque were made with T-test with significance level at 95%.

OPERATIVE TECHNIQUE FOR GROUP A

1) Scouting and patency check with a k-10/8 to establish working length
2) Rotary Glide Path with Af Blue S4 18.05
3) S-one 25.06 until working length was reached

OPERATIVE TECHNIQUE FOR GROUP B

1) Scouting and patency check with a k-10/8 to establish working length
2) S-one 25.06 until working length was reached

DISCUSSION

Both technique allowed instruments to reach working length with no deformation or fracture in all cases.

Table 1. Mean torque and mean instrumentation time for group A and B

	Mean Torque	Mean instrumentation time
With Glide Path	0.53 Ncm (0,09)	62,33 seconds
Without Glide Path	0.64 Ncm (0,05)	96,67 seconds

Both Mean Torque were below the torque limits, and a significant differences was found between the two technique (table 1), with the use of glide path significantly reducing instrumentation mean torque values and instrumentation time

The usage of glide path helped to reduce coronal and middle blade engagement and facilitated progression according to the step back principles, even if a low torque was used. Low torque values could reduce the risk of intracranal separations due to torsional stress; moreover the increase of instrument used did not results in an increase of time consumed for shaping procedure. Moreover, According to the manufacture the innovative alloy (Af H wire) significantly increased the resistant to flexural stress. The usage of Glide path files helped in reducing torsional stress by enlarging the canals dimension.

CLINICAL RELEVANCE

The use of glide path files and low torque seems a promising technique to improve safety and efficiency of single file rotary techniques

REFERENCES

Gambarini G, Seracchiani M, Piasecki L, Valenti Obino F, Galli M, Di Nardo D, Testarelli L. Measurement of torque generated during intracanal instrumentation in vivo. Int Endod J. 2018 Nov 16.

Bonk SW, Ha JH, Chang GS, Kim HC, Kim SK. Effect of the Glide Path Establishment on the Torque Generation to the Files during Instrumentation: An In Vitro Measurement. J Endod. 2018 Mar.

FRIDAY

C23

The nonsurgical retreatment of a mature tooth with regenarative endodontic prosedures and following up with radyograph and CBCT: A case report

Nagihan Güven, Büşra Koçak

Başkent University, Faculty of Dentistry, Department of Endodontics, Ankara, TURKEY

Aim: This case report aimed to demonstrate the nonsurgical retreatment of a mature maxillar first molar and also using regenerative endodontic prosedures.

Introduction: Endodontic treatments are performed to obturate disinfected root canals with inert materials such as guttapercha. The according to American Association of Endodontists (AAE) regenerative prosedures can be used. to revitalize disinfected immature permanent teeth pulp necrosis or apical periodontitis. Can the concept of regenerative endodontics be extended to revitalize unsuccessful treated mature permanent teeth in adults? This case explores the frequently asked question.

Case presentation

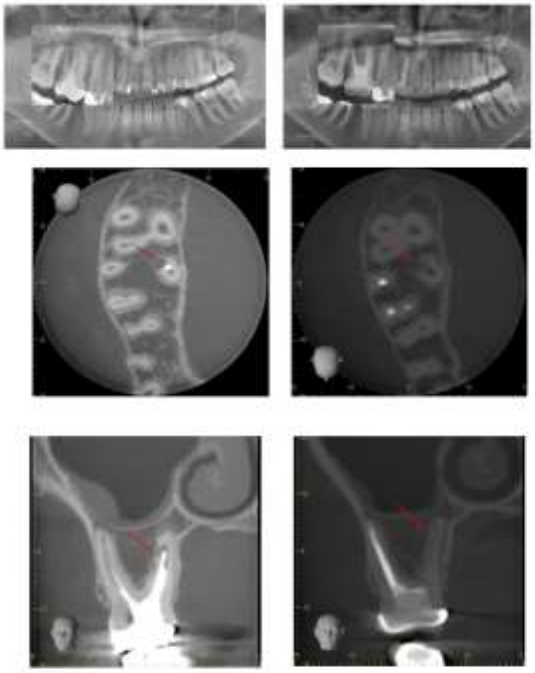

A 14-year old female patient referred with an endodontically treated maxillar first molar tooth with complaint of pain. The tooth demonstrated tenderness to percussion and palpation. Radiologic examination revealed a periradicular lesion involving likely perforation of the palatinal root. The root canal fillings were removed from the canals and $Ca(OH)_2$ paste was placed for 2 weeks. When the tooth was asymptomatic the buccal canals were obturated with guta percha and resin-based sealer. A prebended #20 K-file was used to induced to bleeding into the palatinal canal. A small pieces of spongostane was placed and sealed a 3 mm thickness of mineral trioxide aggregate. The access cavity was closed with CIS for 1 week. Then the tooth restorated with crown.Postoperative radiographs were taken at 3., 6. and 12. months (figure A,B;C). 12. months CBCT images evaluated and the tooth was considered healed. There were no clinical symptoms or radiographic signs.

Figure A

Figure B

Figure C

Discussion: Our clinical and experimental evidence may support the development of new regenerative endodontic strategies for adults with infected / necrotic or unsuccessful treated mature permanent teeth

Conclusions: Strategies for regenerative endodontics for mature permanent teeth in adults will likely be different from those for immature permanent teeth in children and adolescents. This treatment combination including non surgical retreatment and regenative prosedures may be chosen as a treatment option for mature unsuccesful treated teeth in adults.

References:

1-Galler KM et al. (2016).EuropeanSociety of Endodontology position statement: Revitalization procedures. IntEndod J. Aug;49(8):717-23.

2-Saoud TM et al. (2016).Treatment of Mature Permanent Teeth with Necrotic Pulps and Apical Periodontitis Using Regenerative Endodontic Procedures: A Case Series. J Endod. Jan;42(1):57-65.

3-He L et al. (2017).Regenerative Endodontics for Adult Patients. J Endod. Sep;43(95):S57-S64.

C24

NONSURGICAL ENDODONTIC MANAGEMENT OF LARGE PERIAPICAL LESION: A CASE REPORT

Cemre Güzel, Sevda Bilim, Esra İrem Yiğit, Burhan Can Çanakçi
Trakya University, Faculty of Dentistry, Department of Endodontics, Edirne, Turkey

Aim: To report the clinical and radiographic healing of teeth with large periapical lesion following root canal treatment without surgical approach.

Introduction: The decision of performing endodontic treatment or periapical surgery for large periapical lesions have been discussed in clinical practise for many years (1, 2). The advancement of materials and techniques of endodontic treatment resulted in more teeth preservation and minimize the need for surgical intervention. Although many large lesions are treated by surgery, it is possible to treat them by non-surgical root canal treatment.

Case presentation: A 21-year-old male was referred to our clinic with a complaint of swelling and pus drainage from maxillary palatal region. There was no history of trauma. Intraoral examination revealed a large volumetric increase in the left side of anterior hard palate. The swelling was localized, tender on palpation and fluctuant. Drainage extruded from the gingival sulcus of 21. The radiological examination revealed a large periapical lesion in the region of elements 21, 22 and 23 (Figure 1, 2). Cold and EPT confirmed the teeth 21, 22 and 23 to be nonvital. Non surgical root canal treatment was planned. Cleaning and shaping of the root canals were done with Ni-Ti instruments (Reciproc; VDW, Münih, Germany) and irrigation was perforemed with 5.25 % NaOCl, 17 % EDTA and CHX. Intracanal medicament (calcium hydroxide paste) was changed until drainage stopped. The patients were recalled for clinical evaluation at intervals of 2 weeks. After 3 months, the drainage stopped and teeth were asymptomatic, the root canals were obturated with gutta-percha and sealer (Adseal; Meta Biomed Co, Cheongju, Korea) (Figure 3).The teeth were restored with composite resin filling materials. Root canal filling was associated with oral cavity so retreatment was performed for teeth 11. Root canal treatment was indicated for teeth 24 caused by deep caries. After 12 month follow-up period the teeth were clinically asymptomatic and healing was observed in the periapical radiographies (Figure 4,5).

Discussion: The necrotic pulp may release various toxins into the periapical tissues, initiating an inflammatory reaction and leading to the formation of a periapical lesion. Even large periapical lesions can respond favourably to non-surgical treatment. CHX was used in this case due to its wide spread anti-microbial efficiency (3). It has been reported that treatment with calcium hydroxide resulted in a high frequency of periapical healing (4). Radiographic signs such as density change within the lesion, trabecular reformation and lamina dura formation confirmed healing, particularly when associated with the clinical finding that the tooth was asymptomatic and the soft tissue was healthy.

Conclusion & Clinical Relevange :The teeth with large periapical lesion showed favourable results at the end of the follow-up periods. Non-surgical root canal treatment has to be the first treatment option in teeth with large periapical lesion.

Fig. 1 Preoperative panoromic radiograph

Fig.2: Preoperative radiograph

Fig.3: Radiograph taken immediately after endodontic treatment

Fig.4: Post operative radiograph-after 12 months

Fig. 5. The panoramic radiograph of 12 months follow-up.

References

1. Leonardo MR, Silveria FF, Silva LA, Tanomaru Filho M, Utrilla LS. Calcium hydroxide root canal dressing. Histopathological evaluation of periapical repair at different time periods. Braz Dent J 2002; 13: 17–22.
2. Weiger R, Rosendahl R, Löst C. Influence of calcium hydroxide intracanal dressings on the prognosis of teeth wit h endodontically induced periapical lesions. Int Endod J 2000; 33: 219–26.
3.Kuruvilla JR, Kamath MP (1998) Antimicrobial activity of 2.5% sodium hypochlorite and 0.2%chlorhexidine gluconate separately and combined, as endodontic irrigants. Journal of Endodontics24, 472–6.
4. Caliskan MK, Türkün M. Periapical repair and apical closure of a pulpless tooth using calcium hydroxide. Oral Surg Oral Med Oral Pathol 1997; 84: 6836.

MANAGEMENT OF A MAXILLARY INCISOR WITH INVASIVE CERVICAL RESORPTION: A CASE REPORT

Sevda Bilim, Cemre Güzel, Esra İrem Yiğit, Burhan Can Çanakçı
Trakya University, Faculty of Dentistry, Department of Endodontics, Edirne, Turkey

Aim : To present orthograde treatment and external surgical repair of an upper central incisor with pulp necrosis and external cervical resorption.

Introduction: Invasive cervical resorption (ICR) is the loss of dental hard tissue as a result of odontoclastic action; it usually begins on the cervical region of the root surface of the teeth and initially involves only the periodontal ligament, cementum and dentine. However, in advanced stages the pulpal tissues may also become involved (1). The etiology of external cervical resorption is poorly understood, several potential predisposing factors have been identified such as intra-coronal bleaching, orthodontic treatment, trauma, bruxism (2).

Case Presentation:

A 40-year-old male patient was referred to our clinic due to swelling associated with right maxillary region. Clinical examination revealed crown discoloration and sinus tract associated with tooth 11 (Figure 1). Radiographically, external cervical root resorption on mesial side of teeth and apical lesion were observed (Figure 2). CBCT was requested, but the patient refused. The patient did not report any history of dental trauma. The cervical resorption was diagnosed as Heithersay's class III (3). Orthograd endodontic treatment and periodontal surgery were planned to examine the exact extent of the resorption lesion. The access cavity was preperad. The relation between root canal space and resorption area was evaluated lesion and the relationship was detected. Chemo-mechanical preperation was performed using NiTi files (Reciproc; WDW, Munich, Germany), %5 NaOCl and ultrasonic tips. Calcium hydroxide used as intracanal medicament and patient was recalled after 10 days but the patient didn't come to our clinic for 4 weeks. The mucoperiosteal flap was elevated under local anesthesia and the granulation tissue was curetted from the cavity (Figure 3). The defect was filled with glass ionomer cement (Kavitan Pro; SpofaDental, Jicin, Czech Republic) (Figure 4). The root canal was obturated with gutta-percha and sealer (Adseal; Meta Biomed Co, Cheongjiu, Korea) using cold lateral condensation (Figure 5). Then tooth was restorated with composite resin. After 16 months follow up the tooth was asemptomatic; there was no mobility, no sensitivity to percussion or palpation, no sinus tract, probing depth was within normal limits (Figure 7). Radiographic examination revealed no evidence for periapical lesion or cervical bone lost (Figure 6).


Figure 1


Figure 2


Figure 3


Figure 4


Figure 5


Figure 6


Figure 7

Discussion: The Heithersay's classification of ECR is based on two-dimensional imaging, resulting in underestimation and/or inadequate appreciation of the true extent of the resorptive process (3). The Patel's classification is three-dimensional, based on periapical radiographs and CBCT allowing a detailed appreciation of ECR and its geometrical relationships (4). Heithersay G.S. has proposed a clinical classification of invasive cervical resorption depending on the amount of destruction. Heithersay's class III a deeper invasion of dentin by resorbing tissue, not only involving the coronal dentin but also extending into the coronal third of the root. This case : Heithersay's class III beause position, size, relation with root canal space. Heithersay's class III : combine ICR. The treatment plan was combination of surgical approach and non-surgical root canal treatment. The success rates for cervical resorption varies between %50 – 77.8 in Heithersay's class III cases (3).

Conclusion & Clinical Relevance: Cervical root resorption can begin and progress asymptomatically without the presence of any of the known etiological factors. . The treatment of such cases is possible with a multidisciplinary approach.

References :

1. Mavridou, AM, Hauben, E, Wevers, M, Schepers, E, Bergmans, L, Lambrechts, P (2016a)Understanding external cervical resorption in vital teeth. *Journal of Endodontics* 42, 1737– 51.
2. GS. H. Invasive cervical resorption. Endod Topics. 2004;7:73-92.
3. Heithersay G.S.: Invasive cervical resorption. Endod Topics 2004; 7: pp. 73-92
4. Patel, S, Foschi, F, Mannocci, F, Patel, K (2018c) External cervical resorption: a three-dimensional classification. *International Endodontic Journal* 51, 206– 14.

ENDODONTIC MANAGEMENT OF BILATERAL DENS EVAGINATUS OF MANDIBULAR SECOND PREMOLARS WITH APICAL PERIODONTITIS: A CASE REPORT

Birgul Eren, Mete Ungor, Emel Olga Onay

Baskent University, Department of Endodontics, Ankara, TURKEY

Aim

To report the treatment of bilateral dens evaginatus (DE) in mandibular second premolars and its healing outcome after six months

Introduction

DE is an uncommon developmental anomaly characterizied by the presence of tuberde on the occlusal surface and is found most frequently in mandibular premolars. It is usually bilateral and symmetrical. If dens evaginatus is observed in a tooth, the contralateral tooth should also be investigated (1,2,3).

Case Presentation

A 16 years old male patient presented to our clinic with a discomfort in bilateral posterior mandibular premolar teeth. On intraoral clinical examination, the teeth #35 and #45 appeared to be caries free with a tuberde in the mid-occlusal surface, identified as DE. Both mandibular premolars were tender on percussion and the teeth didn't respond to an electric pulp tester (Parkell, Farmingdale, NY, USA) and to cold stimulus (i.e., ice sticks). Radiographic examination revealed that the teeth #35 and #45 had large apical radiolucency and two root canals (fig.1). Root canal treatment of #35 and #45 were planned.

Fig 1. *Preoperative periapical radiographs and intraoral occlusal view of DE*

During the management, the teeth were debrided, irrigated and calcium hydroxide paste was placed in to the root canals for one week. In the second session, the root canals were filled with X3 gutta-percha points and AH 26 (Dentsply De Trey, Konstanz, Germany) sealer (fig 2).

The patient was recalled after 6 months for clinical and radiographic evaluation. The teeth were asymptomatic and the radiographs exhibited a total healing for both of the teeth (fig 3).

Fig 2. Postoperative final radiographs

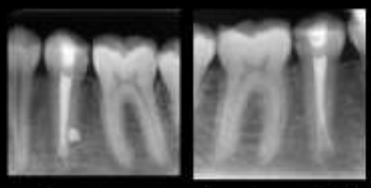

Fig 3. 6-months postoperative radiographs of the right and left premolars.

Discussion

DE has a higher incidence among people of Asian origin however, as noted in the present case, Caucasians may also suffer from this anomaly. It is found most frequently in premolars. It is usually bilateral and symmetrical as observed in this case. If DE is observed in a tooth, the contralateral tooth should also be investigated. Cone-beam computed tomography (CBCT) is a useful radiologic technique because it allows for the interpretation of different planes and provides the clinician with a 3-dimensional (3-D) image. We didn't use CBCT in this case because the patient had financial concerns (1,2,3).

Conclusion & Clinical Relevance

Early diagnosis of such anomalies is important. If a tooth has a dens evaginatus, the contralateral tooth should be also examined.

References

1 Ayer A, Vikram M, Suwal P. Dens Evaginatus:A problem-Based Approach. Case Rep Dent 2015;2015:393209.

2 Viswanathan Shanti, Nagaraj Vezhavendhan, Adimoulame Sanguida, Kumar Sathish, Khemaria Gaurav. Dens evaginatus in proximal surface of mandibular premolar: a rare presentation. Case Rep Dent 2012,2012(c):603583.

3.Cho SY. Dental abscess in a tooth with intact dens evaginatus. Int J paediatr Dent 2006;16(2):135-8.

CHARITÉ

ese
European Society of Endodontology

Conservative management of a large separated file

Sascha Herbst

Charité - Universitätsmedizin Berlin, Department for Operative and Preventive Dentistry

Aim: To describe a successful case with a large periapical lesion and a retained separated instrument (SF) left in the canal.

Introduction: The optimal management of (SF) is still under debate and depends on the clinical situation. In some cases, leaving the SF seems to be a viable option.

Case Presentation: A healthy 45-years-old female patient was referred to our clinic in 1/2018 for removing a separated file from tooth 46. The original diagnosis of the referral was a painful periodontitis apicalis.

The periapical radiograph (PR) and cone-beam computed tomography (CBCT) revealed a large periapical and furcal lesion as well as a SF in the mesiobuccal (mb) canal (Fig. 1a, b). Clinical examination of the SF indicated that removal or bypassing would have been associated with an extensive loss of dentine (Fig. 2a). Frontal CBCT slice revealed a Vertucci Type II, an indirect bypass through the mesiolingual (ml) canal was achievable (Fig. 1 c). An orifice of a middle mesial canal was detected, but the canal was completely calcified (Fig 2a, 3a).

Treatment was performed in two sessions with a calcium hydroxide (CaOH) intracanal dressing between the sessions (medicated for 4 weeks). In each session, irrigation was conducted with 10 ml sodium hypochlorite (2 x passive ultrasonically activated (PUI) for 30 S) and 1 ml ethylenediamintetraacetic acid (30 S PUI). Root canals were obturated in warm vertical compaction technique (guttapercha and sealer). A composite core build-up with cuspal coverage was placed (Fig. 2c) and the tooth received an adhesive cuspal coverage restoration 6 month later (Fig. 2 d).

Discussion: For the described limited observation period, the treatment protocol was successful. However, only a long-term follow-up could finally evaluate this protocol. Current literature indicates, that the size of a periapical lesion correlates with the severity of intracanal infection (1). CaOH dressing was used, because of the assumed antibacterial effect (2). Nevertheless, these biofilms are difficult to treat and it is likely, that biofilms were still present, also in the area of the SF.

Conclusion & Clinical Relevance: This case highlights that healing could be initiated in a severely infected tooth following an intensive irrigation protocol and a bacteria tight coronal and apical seal even with a retained SF.

Fig. 1 Preoperative condition **a.** Periapical radiograph **b.** Horizontal CBCT slice **c.** Frontal CBCT slice

Fig. 2 a. Clinical situation of the SF in the mb canal **b.** Control of the CaOH insertion **c.** Cone fit PR

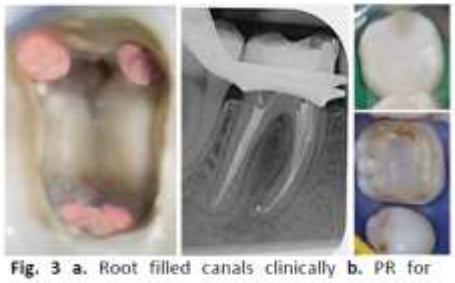

Fig. 3 a. Root filled canals clinically **b.** PR for obturation control **c.** Cuspal covering composite core build-up **d.** Tabletop preparation (ceramic)

Fig. 3 1-year follow-up **a.** PR showing reduction of periapical radiolucency **b.** Buccal clinical view **c.** Occlusal clinical view

References:

1. *Ricucci D, Siqueira JF, Jr. Biofilms and apical periodontitis: study of prevalence and association with clinical and histopathologic findings. J Endod. 2010;36(8):1277-1288.*
2. *Vera J et al. One- versus two-visit endodontic treatment of teeth with apical periodontitis: a histobacteriologic study. J Endod. 2012;38(8):1040-1052.*

Endodontic Management of Developmental Cyst of the Jaw of Non-Endodontic Origin: case report

Abdulwahed Alghamdi BDS, Khaled Balto BDS DMSc
Department of Endodontics, Faculty of Dentistry, King Abdulaziz University, Jeddah, Saudi Arabia

Aim:
To present the outcome of nonsurgical root canal treatment of lateral periodontal cyst after surgical enucleation.

Introduction:
Developmental cysts are an epithelial lined cyst that can be odontogenic or non-odontogenic in origin. The lateral periodontal cyst is an odontogenic cyst that has a rare prevalence of less than 1% and was first reported by Standish and Shafer (1, 2). The lesion may mimic periapical lesion. It arises from remnants of the odontogenic epithelial and can be easily mistaken with periapical lesion (3). However, lateral periodontal cyst is associated with vital teeth.

Case Presentation:
37 years old female patient presented with a draining sinus tract related to the mandibular left premolar area. Patient complain was bad taste and foul smell arising from the area. The patient did not report any pain and present asymptomatic and non-contributory medical history. Clinical examination showed sinus tract related to the mandibular left first premolar. The tooth was discolored with no response to the sensibility tests and the probing around the teeth did not exceed the physiological limits. Both teeth were virgin with no caries, restorations, or cracks. Radiographic examination and sinus tracing revealed a periradicular radiolucency between the roots of #3.3 and #3.4 with roots displacement. A diagnosis of necrotic pulp with chronic apical abscess was made. However, there was no apparent cause for the pulpal/periapical disease and the true etiology could not be identified. After interviewing the patient, she reported a history of oral surgery in the same area. After contacting her oral surgeon and reviewing her medical records, lateral periodontal cyst was enucleated surgically and diagnosed histologically two years prior to her visit to our clinic. The decision was made to do nonsurgical root canal treatment for #3.4. After local anesthesia and under rubber dam isolation, access cavity was made and canal instrumentation was carried out to the full working length along with NaOCl 5.25% irrigation. The canal was enlarged to size 40/04 and obturation was done two weeks later after calcium hydroxide medication. The lesion healed after 18 months.

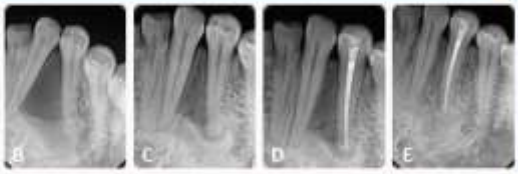

A: Panoramic x-ray showing large inter-radicular radiolucency related to 3.3 and 3.4 prior to surgical enucleation. **B:** Periapical radiograph prior to surgical enucleation. **C:** 24 months post surgery. **D:** PostOp radiograph after NSRCT. **E.** 18 months recall after NSRCT. **F. And G.** Histological evaluation of the lesion showing non-keratinized squamous epithelial lining (arrow EP) and focal plaque like thickening (arrow TH)

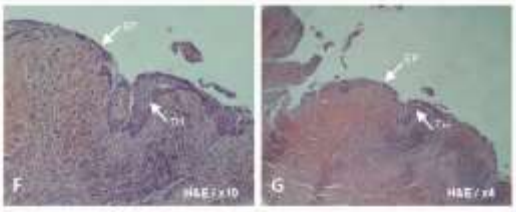

Discussion:
The histological appearance of lateral periodontal cyst is a cystic cavity lined with stratified non-keratinized squamous epithelium with focal plaque thickening of the epithelium into the underlying connective tissue. In the presented case, the dental records of the patient indicated that tooth #3.4 was vital at the time of the surgical enucleation. Most probably, the tooth was unintentionally devitalized during the surgery which resulted in pulp necrosis.

Conclusion & Clinical Relevance:
Several pathological entities might mimic the periapical disease. A lot of which are in close proximity to the apices of vital teeth. Surgical enucleation of these lesions might result in pulpal necrosis of the tooth and subsequent development of a periapical disease. Regular follow up for these patients will help identify pulpal changes after the surgery and avoid unnecessary treatments.

References:
1.Jones AV, Craig GT, Franklin CD. Range and demographics of odontogenic cysts diagnosed in a UK population over a 30-year period. J Oral Pathol Med. 2006;35(8):500-7.
2.Standish S, Shafer W. The lateral periodontal cyst. J Periodontol. 1958;29:27-31.
3.Altini M, Shear M. The lateral periodontal cyst: an update. J Oral Pathol Med. 1992;21(6):245-50.

NONSURGICAL ROOT CANAL TREATMENTS OF EXTENSIVE CYST-LIKE PERIAPICAL LESIONS

Dinç Volkan[1], Kiraz Gulsen[2], Ünal Kemal[2]

[1] Fethiye Oral and Dental Health Center, Muğla, Turkey
[2] Kütahya Health Sciences University, Faculty of Dentistry, Department of Endodontics, Kütahya, Turkey

Aim: To present long term clinical outcome of nonsurgical root canal treatment in teeth with large cyst-like periapical lesion.

Introduction: Bacterial infection of the dental pulp may lead to periapical lesions. They are generally diagnosed either during the routine dental radiographic examination or following acute pain in a tooth. Most periapical lesions (>90%) can be classified as dental granulomas. The prevalence of radicular cysts is only about 15% of all periapical osteolytic lesions. Approximately, 9% are the true cyst and 6% pocket cyst. Periapical cyst is an inflammatory cyst at the apex with distinct epithelium-lined pathological cavity. It is said to be a true cyst when the cavity is completely enclosed in an epithelial lining so that no communication to the root canal exists.

Case Presentation:

CASE 1

A 22-year-old patient was referred to our clinic with a history of swelling, trauma, and pain. According to clinical and radiographical evaluation, a large periapical lesion and swelling originating from the mandibular incisors were detected. Mandibular left central and right lateral teeth gave negative responses to thermal and electric pulp tests. Root canals were instrumented and irrigated. In the second appointment, the root canal was obturated and coronal restoration was performed for the left lateral tooth but root canal of the left central tooth cannot be dried cause of pus liquid. The patient was recalled three times a week and the root canal was irrigated with chlorhexidine. After ten visits root canal was finally dry, root canal obturation and coronal restoration were performed. The 3 year follow-up shows partial healing of the lesion around apex of left incisor.

CASE 2

A 42-year-old patient was referred to our clinic with a history of swelling and pain. According to clinical and radiographical evaluation a large periapical lesion was detected in the maxillar region. Maxillary left incisors, canine and premolars gave negative responses to electric pulp test. Root canals were instrumented and root canals medications were performed by using $Ca(OH)_2$. After three weeks, root canals were obturated and coronal restorations were performed. In the 4 year follow-up, periapical lesions healings were observed.

CASE 3

A 32-year-old patient was referred to our clinic with a history of swelling and pain. According to clinical and radiographical evaluation, a large periapical lesion was detected originating from the right maxillary central and lateral teeth. Root canals were instrumented and root canals medication were performed by using $Ca(OH)_2$, which was replaced at 3rd week. After the patient's symptoms had disappeared the root canals was obturated and coronal restoration was performed. In the 2 year follow-up, periapical lesion healing was observed.

CASE 4

A 49-year-old patient was referred to our clinic with a history of swelling and pain. According to clinical and radiographical evaluation a large periapical lesion, root resorption and sinus tract were observed originating from the mandibular left second molar tooth. Root canals were instrumented and root canal medications were performed by using $Ca(OH)_2$, which were replaced at 3rd week. After the patient's symptoms had disappeared, the root canals were obturated and coronal restorations were performed. In the 3 year follow-up, periapical lesion healing was observed.

Discussion: Periapical lesion is an inflammatory process affecting soft and hard tissues surrounding the tooth. The inflammation is associated with the loss of supporting bone. Necrosis of the pulp provides a suitable environment for microorganisms to release toxins into periapical tissue. This secretion leads to an inflammatory reaction, which is associated with periapical lesion formation.

Conclusion & Clinical Relevance: Nonsurgical management of periapical lesions has shown a high success rate. A nonsurgical approach should always be adopted before resorting to surgery.

References:

1. Sood N., Maheshwari N., Gotfe R., Sood N., Marwah N. Treatment of large periapical cyst like lesion; a noninvasive approach: a report of two cases. *International Journal of Clinical Pediatric Dentistry*. 2015;8:135–137. doi: 10.5005/jp-journals-10005-1299
2. Calskan MK. Prognosis of large cyst-like periapical lesions following nonsurgical root canal therapy: a clinical review. Int Endod J 2004;37:408–16.
3. Ozdan MD. Endodontic treatment of teeth associated with a large periapical lesion. Int Endod J 2002;35:73–8.
4. Nair PN. New perspectives on radicular cysts: do they heal? Int Endod J. 1998; 31: 155-160.
5. Lin LM, Rosenberg PA, Ricucci D, Ortiz AM, Moreno AJ. Chapter 2. Inflammatory odontogenic cysts. Cysts: Causes, Diagnosis and Treatment Options. New York: Nova Science Publishers, 2012.

C30

ORTHOGRADE TREATMENT OF A MAXILLARY INCISOR FUSED WITH A DENS INVAGINATUS: A CASE REPORT

Flores C, NE., Reyes L. WL., Del Torno A, JR

Department of Endodontics, Universidad Veracruzana, Minatitlán, Veracruz, México

Aim: To present the treatment of a maxillary incisor fused with a dens invaginatus, associated with an apical lesion.

Introduction

Dens invaginatus is the result of an invagination of the enamel organ during tooth development and results in complex internal anatomy. The prevalence is between 0.3% and 10%. Tooth fusion is the union of two separated tooth buds with the resultant formation of a joined tooth with confluence of dentin. The prevalence is between 0.3% and 5%. Diagnosis and treatment can be challenging. Magnification and cone-beam computed tomography are aids in diagnosis and treatment and can improve treatment prognosis.

Case Presentation

A 9-years-old male boy, with no systemic diseases, reported pain and edema associated with the upper right incisors. He was prescribed antibiotics and analgesic by a paediatric dentist, and referred to the Department of Endodontics, Universidad Veracruzana. A dental history and clinical examination was made. Diagnosis: previously initiated therapy acute apical abscess. Local anesthesia and rubber dam isolation was carried out. During the access cavity with magnification, we identified 3 orifices. Electronic and clinical working length determination and hand instrumentation with K file and irrigation with NaOCl 2.5%, EDTA 17% and chlorhexidine 2%, activated with ultrasound. The obturation of mesial and central canals was made with warm gutta percha, and Biodentine™ in distal canal. At follow up of 3 years, is asynthomatic only with coronal pigmentation.

Discussion

Over the years many authors have described the treatment of dens invaginatus and fused teeth, but there are few references of both anomalies together. It was challenging because of the complex anatomy and 5 appointments were needed for the conclusion of the treatment.

Fig. 1. Intraoral photograghy

Fig. 2. Cone-beam tomography and radiography

Fig. 3. Clinical apparence of the 3 canals.

Fig. 4. Final radiography

Fig. 5. Three years follow up

Conclusion & Clinical Relevance

This unique case, despite it rare and anormal anatomy, was successfully treated thanks to the use of magnification and biocompatibles materials.

References

1. Thakur S, Thakur NS, Bramta M, Gupta M. Dens invagination: A review of literature and report of two cases. J Nat Sci Biol Med. 2014 Jan;5(1):218-21. **2**. Nosrat A, Schneider SC. Endodontic Management of a Maxillary Lateral Incisor with 4 Root Canals and a Dens Invaginatus Tract. J Endodon. 2015;41(7):1167-71. **3**. Zoya A, Ali S, Alam S, Tewari RK, Mishra SK, Kumar A, Andrabi SM. Doble Dens Invaginatus with Multiple Canals in a Maxillary Central Incisor: Retreatment and Managing Complications. J Endod 2015 41:1927-32.

SURGICAL ENDODONTIC TREATMENT OF AN UPPER LATERAL INCISOR PRESENTING *DENS INVAGINATUS* OEHLERS CLASS III.

*Uribe-Campero Mario, Márquez-Rentería Alma, Plascencia Hugo

Endodontic Posgraduate Program, CUCS, Universidad de Guadalajara, Mexico.

Aim

To report the clinical managment of an upper lateral incisor presenting "Dens Invaginatus" DI (1) Oehlers Class III.

Introduction

DI is a developmental anomaly caused by the invagination of the dental papilla during its formation and can cause endodontic complications. The treatment varies in relation to its anatomical complexity (2)

Case Presentation

A 35-year-old female patient presented with a change in color and a sinus tract in the upper left lateral incisor. In the mesio-distal aspect a wider crown is observed when compared to opposite side(Fig. 2).

Radiographically, two canals were observed with a previous endodontic tx and an apparent DI in the root of the mesial side, which was very difficult to access coronally, as well as apical periodontitis (Fig. 1). In the sinus tract Rx the gutta-percha tip is directed towards the apical zone (Fig.3).

Diagnosis: DI Oehlers Class III, previous endodontic treatment and apical periodontitis.

After anesthesia and isolation, all the clinical procedures were performed with a clinical microscope. A CBCT was indicated to confirm the presence of DI (Fig. 4).

After 15 days the main canals were obturated (Fig. 5), the sinus tract did not disappear; therefore it was scheduled for apical surgery. 3rd Appointment: Under magnification the incision, elevation and retraction of a full thickness triangular flap was performed, after enucleating and curetting the lesion, the apex was cut and an apical cavity of the three canals was done (Fig. 6) It was sealed with MTA (Fig. 7). The flap was repositionated and sutured. Inmediate Rx was taken (Fig. 8). Post-operative care and NSAIDs were prescribe for three to four days.

Clinical and Radiographic follow up at 10 and 26 months with absence of signs and symptoms. Normal periodontal tissues is observed (Figs 9 and 10).

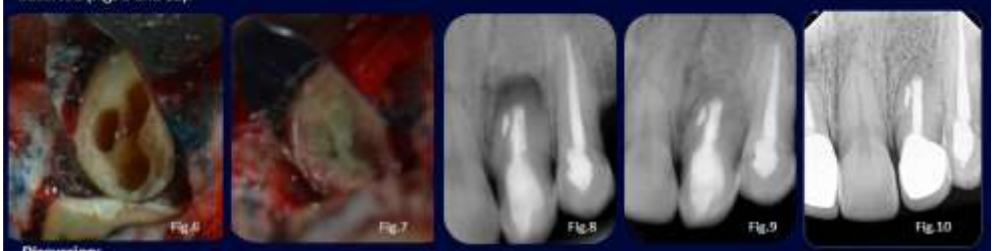

Discussion:

- Various techniques and approaches to treating DI have been reported in the literature, including preventive sealing of the invagination, root canal treatment with or without periapical surgery, intentional replantation and extraction (3).
- Apical surgery is indicated in cases in which endodontic therapy has failed, and in teeth that present anatomic variations that do not allow access to and cleaning of all the parts of the canal system, such as many cases of DI type III with periapical lesions.(4).

Conclusion & Clinical Relevance

- The treatment of DI is less aggressive the more opportune is its diagnosis .
- Clinical treatment of the root canal of teeth DI should be based on a thorough clinical and radiographic and CBCT evaluation, diagnosis and treatment.
- Sugical treatment offers a very predictable prognosis when treating DI.

References

1. Estrela C, Bueno M, Azevedo B, Azevedo J, Pécora J. A new periapical index based on cone beam computed tomography. J Endod. 2008;34(11):1325-1331

2. Kristoffersen ØB, Nag OH, Tristad I. Dens invaginatus and treatment options based on a classification system: report of a type II invagination. International Endodontic Journal, 41, 702–709, 2008.

3. Fregnani ER, Spinola LFB, Sa˜ nego JRO, Bueno CES & De Martin AS. Complex endodontic treatment of an immature type III dens invaginatus. A case report . Int Endod J 2008,41,913-919, 2010

4. da Silva Neto UX, Hirai VH, Papalexiou V, Gonçalves SB, Westphalen VP, Bramante CM, et al. Combined endodontic therapy and surgery in the treatment of dens invaginatus type 3: Case report. Can Dent Assoc. 2005;71:855–8.

BASKENT UNIVERSITY

OUTCOME ASSESSMENT OF PERIAPICAL LESIONS BY USING ULTRASOUND AND CBCT: REPORT OF TWO CASES

ESE VIENNA 11-14 SEPTEMBER

Koç C*, Sönmez G, Kamburoğlu K****

**Dept. of Endodontics, Faculty of Dentistry, Başkent University, Ankara*

***Dept. of Dentomaxillofacial Radiology, Faculty of Dentistry, Ankara University, Ankara*

Aim: To present the use of cone beam computed tomography (CBCT) and ultrasound imaging to evaluate bone healing after nonsurgical root canal retreatment.

Introduction: Nonsurgical root canal retreatment is usually considered to be the first treatment option for endodontic failure. According to the guideline, CBCT can be used as an imaging modality of choice when evaluating the non-healing of previous endodontic treatment to help determine the need for further treatment, such as nonsurgical, surgical or extraction (1). Additionally, ultrasound imaging (US) serves as a radiation-free tool for evaluating bone healing (2).

Case Presentation:

In the first case, A 20-year old female patient was referred to our clinic with the complaint of sinus tract on the buccal mucosa of the left first mandibular molar tooth. In the second case, 22-year old female patient to our clinic with asymptomatic periapical radiolucent area in right first mandibular molar tooth, which was revealed in a routine checkup. After clinical and radiographic examination, it was observed that both teeth previously treated (5-6 years ago). In the first case tooth was diagnosed as chronic apical abscess and in the second case tooth was diagnosed as asymptomatic apical periodontitis. CBCT imaging was required to determine the precise location and source of the radiolucent areas. CBCT (Planmeca, Helsinki, Finland) images were taken by using 0.075 mm voxel size, 96 kVp and 1 mA. In order to assess nature of the lesions, ultrasound examinations of lesions were performed by using ACUSON S 2000 (Siemens, Munich, Germany) 9MHz linear probe and 15MHz hockey probe on the transversal plane.Previous obturation materials were removed using hand files and rotary files. Root canal instrumentation was accomplished using hand files and nickel- titanium rotary files in a crown-down approach and chemical irrigation using 20 mL 2.5 % sodium hypochlorite (NaOCl). Treatment was completed in 2 to 3 visits. An intracanal calcium hydroxide dressing was placed between visits; and Cavit was used as the temporary filling material. On final appointment, calcium hydroxide was removed with copious irrigation of 2.5% NaOCl combined with hand and rotary files.The smear layer was removed with 5 mL 17% EDTA. Canals were obturated with gutta-percha and AH Plus sealer (Dentsply, Tulsa, OK) by cold lateral compaction. Teeth were restored with composite resin. At the 1-year follow up, postoperative CBCT and ultrasound images were compared with the preoperative images.

Case I

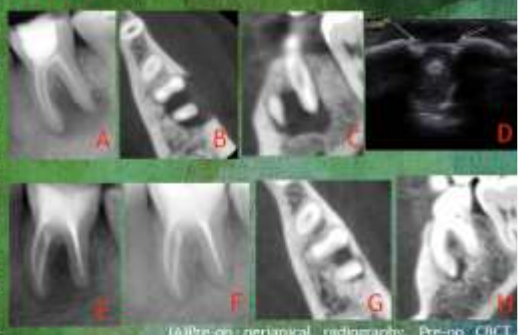

(A)Pre-op periapical radiography. Pre-op CBCT axial and (C) sagittal views. (D) Pre-op US image- arrows show hypoechoic region suggestive of bone destruction. (E) Immediate post-op periapical radiography. (F) 1 year follow-up periapical radiography. 1 year follow-up CBCT (G) axial and (H) sagittal views show a decrease in lesion size when compared with pre-op CBCT views. The lesion has reduced in size but has not completely resolved. (I) 1 year follow-up US image-arrows show hyperechoic region, with echogenicity comparable with that of the adjacent normal bone.

Case II

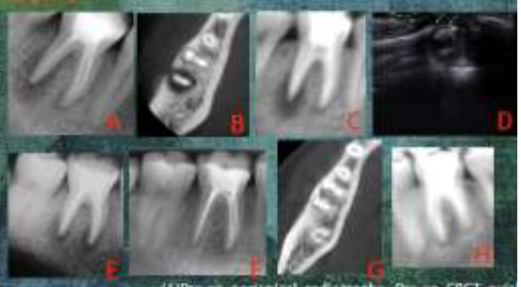

(A)Pre-op periapical radiography. Pre-op CBCT axial and (C) sagittal views. (D) Pre-op US image- arrows show hypoechoic region suggestive of bone destruction. (E) Immediate post-op periapical radiography. (F) 1 year follow-up periapical radiography. 1 year follow-up CBCT (G) axial and (H) sagittal views show a decrease in lesion size when compared with pre-op CBCT views. The lesion has reduced in size but has not completely resolved. (I) 1 year follow-up US image- arrows show hyperechoic region, with echogenicity comparable with that of the adjacent normal bone. This suggests that bone formation has occurred in that region

Discussion: These case reports demonstrated that combining CBCT with ultrasound imaging could provide valuable information in terms of treatment planning and outcome assessment.

Conclusion & Clinical Relevance: In case of failure of initial treatment, nonsurgical root canal retreatment is indicated. Besides benefits of CBCT, ultrasound imaging would be an important contribution as a radiation-free imaging tool.

1. *AAE and AAOMR Joint Position Statement. Use of cone beam computed tomography in endodontics 2015/2016 update.*
2. *Cotti E, Esposito SA, Musu D, Campisi G, Shemesh H. Ultrasound examination with color power Doppler to assess the early response of apical periodontitis to the endodontic treatment. Clin Oral Investig 22(1):131-140, 2018*

C33

Mental Nerve Injury Caused by Gutta-Percha Overextension: A Case Report

Akbal Dincer G[1], Erdogan D[1], Turkyilmaz A[1], Erdemir A[1]

[1]Department of Endodontics, Faculty of Dentistry, University of Kirikkale

19th Biennial European Society of Endodontology Congress
September, 12-14, 2019, Vienna, Austria

Introduction

The fundamental principles of root canal treatment are eradication of infected tissues and bacteria, sufficient root canal preparation and filling. Ideally, the filling material should be retained to the root canal without extending to periapical tissues or other adjacent structures. Although periradicular tissues generally well tolerate minor extrusion of endodontic filling materials, material beyond the apical foramen may cause clinical manifestations.[1]

When the filling materials are either close to or in contact with nerve structures, anesthesia, hypoaesthesia, paraesthesia or dysaesthesia may occur. Numerous case reports have described the occurrence of paraesthesia during and after root canal treatment.[2-4] This case report aimed to present diagnosis and treatment of mental nerve paresthesia caused by gutta-percha overextension.

Case Presentation

A 44-year-old woman was applied to our clinic regarding pain and numbness in her left lower lip and chin, which developed after two days following endodontic therapy for her mandibular right second premolar. When periapical film of the previous canal treatment was examined, it was seen that gutta-percha was at the radiological apex. Due to the severity of patient complaints, a cone beam computed tomography (CBCT) was taken as an alternative radiographic examination, which clearly showed radiopaque root canal filling material in the periapical area of the mandibular right second premolar and the material was extended from the apex.

Retreatment procedures were performed with Protaper Universal retreatment instruments (D1, D2, D3) (Dentsply Maillefer, Ballaigues, Switzerland). To prevent the extended gutta-percha to move further apically, we formed gaps circumferentially between the gutta-percha and the canal wall with #20 K-files. H files were used in the gaps for removing the gutta-percha. The working length was determined by CBCT measurements, confirmed by apex locator and periapical radiographs. After gentle irrigation with 2.5% sodium hypochlorite solution (NaOCl), the canal was dried with paper points and dressed with calcium hydroxide (Metapaste; Meta Biomed, Chungbuk, South Korea). The access cavity was closed with a sterile cotton pellet and temporary filling material.

Two weeks later, at the second appointment, the patient appraised that there was no numbness three days later after the first visit and the tooth was asymptomatic, no sensitivity to percussion. In this way, the tooth was filled with cold lateral condensation technique using tapered gutta-percha (Dentsplay Maillefer, Ballaigues, Switzerland) and sealer (2Seal VDW, München, Germany) and restored with light-cured composite resin (GC Gradia Direct, Tokyo, Japan).

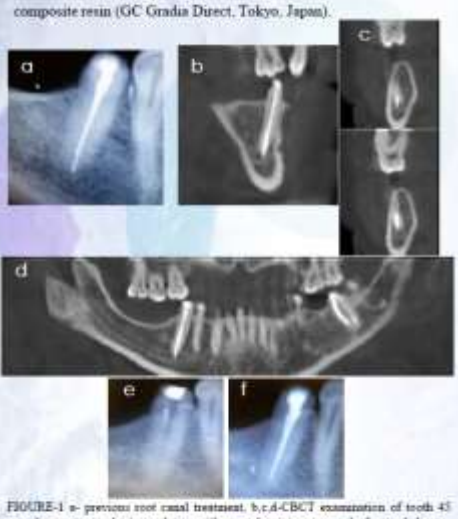

FIGURE-1 a- previous root canal treatment, b,c,d-CBCT examination of tooth 43 revealing gutta-percha in a relation with mental nerve, e-removal of extended gutta-percha, f-final root canal retreatment.

Discussion

Endodontic materials have been reported to induce pain and paraesthesia when in contact with alveolar nerves.[4] It is not always possible to make a precise diagnosis of extrusion into the nerve by showing the contact of the filling material with the alveolar nerves using traditional endodontic radiographs. In this case, the use of CBCT was justified as periapical radiography was normal but patient's complaints were not parallel with the radiography. Treatment of endodontic-related paraesthesia remains controversial. In this case, gutta-percha was attempted to be removed through the canal.

Conclusion and Clinical Revelance

CBCT can be contemplated as an influential radiographic diagnostic device when an endodontic-related inferior alveolar nerve or mental foramen paraesthesia are suspected. It seems logical that if the cause of injury is nerve compression then removing the cause as early as possible could be beneficial. This may achieved by cautious retreatment procedures, if failed, surgery could be only key.

References

1- Gambarini, G., Piasecki, L., Grande, N. M., Testarelli, L., Prescipe, M., Messineo, D., Festuni, L. & D'ambrosio, F. (2011). Differential diagnosis of endodontic-related inferior alveolar nerve paraesthesia with cone beam computed tomography: a case report. *International endodontic journal*, *44*(2), 176-181.

2- Giuliani M, Lajolo C, Deli G, Silvestri C (2001) Inferior alveolar nerve paresthesia caused by endodontic pathosis: a case report and review of the literature. Oral Surgery, Oral Medicine & Oral Pathology 92, 670–4.

3- Poveda, R., Bagan, J. V., Fernandez, J. M. D., & Sanchis, J. M. (2006). Mental nerve paresthesia associated with endodontic paste within the mandibular canal: report of a case. *Oral Surgery, Oral Medicine, Oral Pathology, Oral Radiology, and Endodontology*, *102*(5), e46-e49.

4- Escoda-Francolí J, Candela-Sahli C, Solar A, Figueredo R, Gay-Escoda C (2007) Inferior alveolar nerve damage because of overextended endodontic material: a problem of sealer cement biocompatibility? Journal of Endodontics 33, 1484–9

ROOT CANAL RETREATMENT OF MAXILLARY CENTRAL INCISOR WITH EXTERNAL APICAL ROOT RESORPTION

Bojan Dželetović, Ivana Milanović, Jelena Nešković
Department of Restorative Dentistry and Endodontics, School of Dental Medicine, University of Belgrade, Serbia

Aim

To report a clinical case of endodontic retreatment of a maxillary right central incisor with history of trauma in anterior maxillary region using Biodentine.

Introduction

External root resorption involves complex processes and is common complication after dental trauma and subsequent pulpal necrosis and bacterial contamination. Endodontic treatment of teeth with extensive external root resorption require special attention, considering correct working length determination, condensation of filling material within canal and susceptibility to fracture.

Case presentation

A 36-year-old male reported to our department with a chief complaint of discolored maxillary incisor. Medical history was noncontributory and patient had a history of trauma in maxillary front region 10 years before. Clinical examination revealed discolored upper right central incisor with composite filling on palatal and distal side of the crown. Patient was symptom free and without percussion and palpation sensitivity. Panoramic radiograph revealed poor endodontic treatment and extensive external root resorption (Fig. 1). Based on the patient's history, clinical and radiographic examinations endodontic retreatment was planned. Tooth was accessed and previous gutta-percha filling was removed from the root canal with aid of hand K-files. Working length was established with the use of an apex locator (Dpex III, Woodpecker, Guilin, China). Instrumentation was done to size 120 hand K-file. During the treatment canals were copiously irrigated with a 1% sodium hypochlorite solution and smear layer removed with 10% citric acid. The root canal was dried with paper points before application of calcium hydroxide paste (Fig. 2). In the second visit, two weeks later, intracanal dressing was removed and root canal filled with Biodentine (Septodont, Saint-Maur-des-Fossés, France) that was applied by hand plugger. The access cavity was temporarily restored with Citodur (Doriodent, Wien, Austria) and radiograph was taken to assess the quality of obturation (Fig. 3).

At the 5 months recall, patient was asymptomatic (Fig. 4).

Fig. 1 Pre-operative radiograph (portion of a panoramic radiograph)

Fig. 2 Calcium hydroxide paste in root canal

Fig. 3 Post-obturation radiograph

Fig. 4 Five-month control radiograph

Discussion

Calcium silicate-based materials have been proposed as a favorable repair material in endodontic indications due to its bioactivity and biocompatibility. Biodentine was chosen due to better consistency after mixing and easier handling which allows more precisely placement in areas of resorptive defect. It has dentin-like mechanical properties, good sealing ability and needs less time for setting.

Conclusion & Clinical Relevance

Due to good physical and chemical properties associated with the biological effects Biodentine may be used as only obturating material in severe root resorption cases.

References

Pinsonne et al. External inflammatory and replacement resorption of luxated, and avulsed replanted permanent incisors: a review and case presentation Dent Traumatol 19, 170-174, 2003
Iglesias-Linares et al. Cellular and Molecular Pathways Leading to External Root Resorption 96, 143–152, 2016
Nikhil et al. Non surgical management of trauma induced external root resorption at two different sites in a single tooth with Biodentine: a case report Endodontology 24, 150–5, 2012

C35

Clinical Case of Treatment of Chronic Apical Periodontitis

O. Khvorostenko, D. Galieva, Zh. Asyrbekova, M. Sukhikh, Yu. Ostrovskaya

Institutions

Aim

To increase the effectiveness of retreatment teeth with chronic apical periodontitis

Introduction

Secondary infection of root canals often causes periapical bone lesions. The extent of the process depends on the type of infection, time the infection is present in a canal, immune system condition. Tooth anatomy, its proximity to great vessels, nerves, sinuses play an important role.

Case Presentation

Patient Ch., 45 y.o., presented to the university clinic with complaints of persistent pain, oedematous right side of the mandible and numbness of the lower lip and chin on the right. Tooth 4.5 had been endodontically treated before. Findings on examination: filling on occlusal surface of tooth 4.5, tender on percussion, mucobuccal fold swollen, painful on palpation. Periapical X-rays showed periapical bone tissue lesion with ill-defined peripheral contours, with extension into the mandibular canal, 1.0x0.7 cm in diameter . Treatment . Tooth 4.5 was treated in two-visits. During the 1 st visit root-canal filling material was removed to the full working length with rotary NiTi instruments (ProtaperS1, S2) and the tooth was treated chemically (5% NaOCL, 17% EDTA), there was purulent discharge during root-canal filling removal. After it had stopped, calcium hydroxide paste dressing was applied as an interappointment filling. At the 2 nd appointment the patient didn't complain of pain and sensitivity had been restored. Root canals were again instrumented (ProtaperS2, F1,F2, F3), cleaned chemically (5% NaOCL, 17% EDTA, 2% CHX) and obturated using hybrid technique of vertical condensation of guttapercha (sealer H26). Followup after 1 year . Followup after 2 year .

Discussion

Healing after endodontic treatment.

Conclusion & Clinical Relevance

Adherence to the protocol of treatment of teeth with large periapical bone lesions with extension into the lower jaw will decrease bone tissue lesion and restore soft tissue sensitivity.

References (max 5)

Dahlen G., Haapasalo M. Microbiology of apical periodontitis. // Essential Endodontology.–1988.–P. 106–130. Estrela C, Sydney GB, Bammann LL, Felippe Júnior O. Mechanism of action of calcium and hydroxyl ions of calcium hydroxide on tissue and bacteria. Braz Dent (Fig.4) J. 1995; 6(2):85-90.

Application of endodontic microsurgery in the tooth autotransplantation: report of 2 cases

Hanguo WANG

Department of Operative Dentistry & Endodontics
The Third Affiliated Hospital, Air Force Medical University
Xi'an, P.R.China

Aim: To introduce the application of endodontic microsurgery in tooth autotransplantation.

Introduction: Tooth autotransplantation, usually performed by oral surgeon, is a viable option for the treatment of a missing tooth when there is a donor tooth available. However, in some instances, endodontic microsurgery by endodontist is necessary for the tooth autotransplantation.

Case Presentation:

Case 1. After extraction, the root tip of the donor tooth (left mandibular third molar) was severely curved. Under the microscope, 4 mm of the root tip was cut by a high-speed fissure bur to remove the root curvature, followed by the root-end preparation and filling with bioceramic putty repair cement iRoot BP Plus. At last, the tooth was transplanted to the recipient site (left mandibular second molar). The post-operative radiograph showed the tooth in right place, while the filling material of distal root was washed out during the transplantation procedure. 4 weeks later, root canal treatment was accomplished.

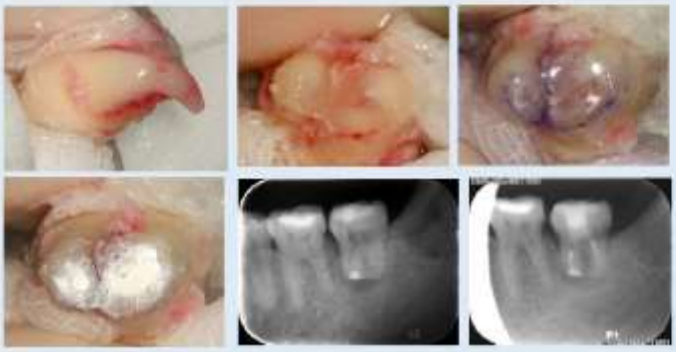

Figure 1. Apicoectomy is performed to resect the severely curved root tip of the donor tooth to adapt the recipient site

Case 2. The right mandibular first molar was extracted due to vertical root facture of the mesial root, and autotransplantation with the right mandibular third molar was suggested. During the extraction procedure, the root tips of the donor tooth were broken because of severe curvature. Under the microscope, 3 mm of apical root resection was performed, followed by the root end preparation and filling with iRoot BP Plus. At last, the tooth was transplanted to the recipient site, and the post-operative radiograph showed the tooth in right place. 4 weeks later, root canal treatment was accomplished. At the 2, 12-month follow-ups, clinical examination and the radiograph showed complete healing.

Figure 2. Because the root tips of the donor teeth are broken during extraction, the apicoectomy, root end preparation and filling is performed

Discussion: During the tooth autotransplantation, if the root tips of the donor teeth are broken during extraction, which results in much difficulty in the following root canal treatment, or the root tips are severely curved, which is difficult to adapt the recipient site, endodontic microsurgery is necessary.

Conclusion & Clinical Relevance: Endodontic microsurgery is necessary when the root tips of donor tooth are broken or severely curved during the tooth autotransplantation procedure.

References: Microsurgery in Endodontics. Kim S & Kratchman S. Wiley Blackwell, 2017

Endodontic surgery in the treatment of lateral cyst and severe internal resorption

Boris Paša, DMD, specialist in endodontics and restorative dentistry
Dental Clinic Zagreb, Petkovićeva 3, Zagreb

AIM

To discuss surgical treatment as treatment option in cases of severe internal/external resorption and lateral cyst formation.

INTRODUCTION

Root resorption is often incidental radiographic finding (Figures 1,2). Often in combination with lateral cyst formation as a result of dental trauma. However these conditions demand intervention because of possible root fracture. The main goal is to preserve tooth and eliminate osteoclastic activity with surgical cyst removal.


Figure 1.


Figure 2.


Picture 1.


Picture 2.

CASE PRESENTATION

A 49 year old woman was reffered to our clinic with radiograph showing severe root resorption on tooth 21 and lateral cyst in medial line as a result of possible trauma (Figure 2.) Patient had no symptoms. The therapy consisted of tooth immobilisation, endodontic preoperative therapy and surgical treatment with extraction of apical part of the root, cyst removal, application of bone substitute (BioOss, Botiss materials), MTA ProRoot (Dentsply) for retrograde filling. (Pictures 1, 2, 3, 4, 5, 6)

Postoperative radiograph showed good integration of bone substitute and MTA used for reconstruction of coronal part of the root. (Figures 4, 5)


Picture 3.


Picture 4.


Picture 5.


Picture 6.


Figure 4.


Figure 5.

DISCUSSION

Tooth preservation in combination with elimination of infection could be a treatment option before implant placement in aesthetic zone.

CONCLUSION/CLINICAL RELEVANCE

This therapy option showed it is possible to preserve the tooth as a long term temporary solution. Nevertheless implant therapy is always the option in case of extraction of 21.

References:
Marwan Abou Rass, DDS, MDS, PhD*, Interim Endodontic Therapy for Alveolar Socket Bone Regeneration of Infected Hopeless Teeth Prior to Implant Therapy, JOI 36, 37-59, 2010

Guided apicoectomy: Computed Tomography based approach with Platelet Rich Fibrin Graft- A report of 2 cases

Witold Popowicz [1] Aleksandra Palatyńska-Ulatowska [2*] Meetu Ralli Kohli [3]

[1] Specialist Private Dental Practice "Dental Vit" 18/4 Powstania Styczniowego St. 81-519, Gdynia, Poland
[2] Chair, Department of Conservative Dentistry and Endodontics, Medical University of Lodz, 251 Pomorska St. 92-217 Lodz, Poland
[3] Clinical Associate Professor, Department of Endodontics, University of Pennsylvania 240N 40th street, Philadelphia, PA 19104 USA

AIM

The aim of these case reports is to describe the root-end surgery with the use of the implant DDS Pro-planning software (Ortolab, Natrodent Polska, Poland), a 3D printed surgical guide precisely positioned according to preoperative CBCT scans performed according to ALARA principles (Carestream CS 8100, USA), and a modified soft tissue access.

INTRODUCTION

Endodontic microsurgery is a predictable alternative to nonsurgical therapy for treatment of therapy resistant apical periodontitis. The modern endodontic microsurgical procedure has been evolving in pace with technological advances. Introduction of modern innovations such as cone beam computed tomography (CBCT), three-dimensional (3D) printing technology, 3D surgical guide (3DSG) designed with a computer-aided software have allowed for a novel approach to the surgical site.

CASE PRESENTATION

Hollow trephine bur was used to do the osteotomy, resection of the root and enucleation of the lesion. The intact cortical plate was salvaged and used as a graft along with plasma rich fibrin (PRF) acquired preoperatively from the patient's blood. The positioning guide allowed to precisely achieve targeted tissues and shorten the procedure time. The modified soft tissue management helped to achieve a small surgical wound for uneventful healing. Less than 12-month CBCT follow up of both cases show complete three-dimensional healing of the surgical site.

Case 1

Figure 1

Case 2

Figure 2

Figure 3: Trephine bur (Komet, Germany)

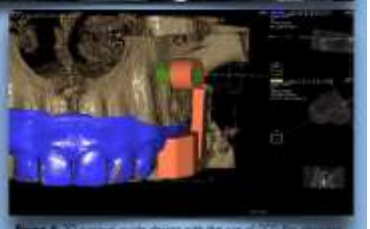

Figure 4: 3D surgical guide design with the use of DDS Pro planning software (Ortolab, Natrodent Polska, Poland)

DISCUSSION

In microsurgery, soft tissue management involves flap elevation after intrasulcular or submarginal horizontal incision and one or two vertical incisions encompassing at least one adjacent tooth on each side, to allow adequate visualization of the apical area of the tooth to be treated. In a recent case report while using 3DSG Giacomino et al. did not reflect a flap instead drilled through the soft tissue creating a punched out wound, which healed with secondary intention (1). In the cases presented here the soft tissue was reflected but only with one vertical release incision (Fig 1g, 3 g, f). The main reason was to be able to place the 3DSG directly on the bone as to avoid any distortion in measurements due to elasticity and depressability of the soft tissue. The routinely used rotary carbide surgical bur was replaced with a trephine bur, which is hollow surrounded by a round cutting metal ring of 0.3mm thickness (Fig. 3).The markings on the outside of the bur allowed to control the depth. The 8-10mm sleeve of the 3DSG allowed to direct the trephine in the correct direction, the controlled depth of drilling punched out the cortical plate the same diameter as the trephine bur along with the apical portion of the root in one step hence reducing the time taken to do these steps in routine microsurgery.

CONCLUSION & CLINICAL RELEVANCE

The presented case reports show potential for Targeted Endodontic Microsurgery not just in execution but positive outcome in a short follow up period. Preserving the cortical plate to be used as an autologous graft was an added advantage in this technique. Future clinical research will allow for better standardization, further accuracy and application in various clinical conditions.

REFERENCES

[1] Giacomino CM, Ray JJ, Wealleans JA. Targeted Endodontic Microsurgery: A Novel Approach to Anatomically Challenging Scenarios Using 3-dimensional-printed Guides and Trephine Burs-A Report of 3 Cases. J Endod. 2018;44(4):671-7. 2. Setzer FC, Kohli MR, Shah SB, Karabucak B, Kim S. Outcome of endodontic surgery: a meta-analysis of the literature--Part 2: Comparison of endodontic microsurgical techniques with and without the use of higher magnification. J Endod. 2012;38(11):1-16. 3. Hirsch U, Kohli MR, Kim S. Apicoectomy of maxillary anterior teeth through a palatomucosal flap: hidden osteotomy, two case reports introducing a new technique to preserve cortical bone. Restor Dent Endod. 2016;41(4):310-5. 4. Connert T, Zehnder MS, Amato M, Weiger R, Kühl S, Krastl G. Microguided endodontics: a method to achieve minimally invasive access cavity preparation and root canal location in mandibular incisors using a novel computer-guided technique. Int Endod J. 2018;51(10):1449-56. 5. Gargiulo JVD, Medeiros PJD, Figueiredo CMD, Vianna RG, Rôças IN. Puncture-risk zone in the surgical approach: a cadaveric cone-beam computed tomography analysis. Int J Oral Maxillofac Surg. 2018.

ESE VIENNA 13-14 SEPTEMBER

Oehler's Type III Dens Invaginatus
CASE REPORT

Raad Imad, Tello Gloria, Marin Abimael
Universidad de Guadalajara, CUCS, Endodontic Posgraduate Program

AIM

To present a clinical case of Oehlers type III *dens in dent*

INTRODUCTION

Dens *invaginatus* (DI)[1] is a dental development anomaly that results in a cavity or invagination enamel coated that forms and penetrates the dental papilla before the mineralization phase[2]. The invagination is frequently communicated with the oral cavity, which allows the entry of microorganisms and irritants directly into the pulp tissue[3]. This admission of irritants and subsequent inflammation generally leads to necrosis of the adjacent pulpal tissue and the formation of apical periodontitis[4]. Oehlers[5] established 3 categories according to the penetration depth of the invagination with the periodontal ligament or periapical tissues.

Img 1. Periapical radiograph (a) and preoperative clinical image (b)

CLINICAL REPORT

16 years old female patient without pathological data attended the endodontics clinic derived from the orthodontics service by radiographic finding in D.O. 22, which presents apical radiolucency (Img. 1a) and anatomical variation in the crown. At clinical inspection the D.O. 22 presents yellow-gray coloration and a very large cingulum (Img. 1b). Sensitivity tests (cold and electrical) responded negative, while all adjacent teeth were positive.

The diagnosis was pulp necrosis and asymptomatic apical periodontitis. Due to the anatomical complexity, a CBCT was requested. Coronary access was performed, locating two canals (Img. 3a and 3b). They both were shaped with #60 K file, irrigated with 2.5% NaOCl and PUI at the end. Smear layer removed with 17% EDTA for 5 minutes. Intracanal $Ca(OH)_2$ medication was left in aqueous paste, and exchanged twice at 15 and 30 days. The patient was asymptomatic. After one month, it was filled with bioceramic cement, brushing the dentinal and apical walls with EndoSequence BC Sealer and the middle third with EndoSequence BC RRM Putty[6] (Brasseler USA), packing it with Schilder pluggers with light pressure. Ten days later the patient began to feel pain in the area. As it remained after a week it was decided to complement the root canal treatment with surgery.

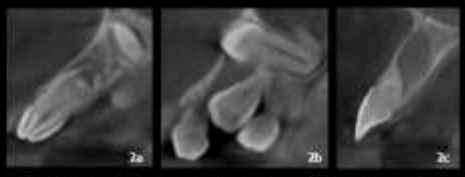

Img 2. (a) CBCT showing deep invagination, up to the apical third of the lateral incisor, showing communication to the oral cavity. (b) In the periapical region, a mineralized structure is observed, which corresponds to a retained canine. (c) The periapical lesion extends to the adjacent central incisor.

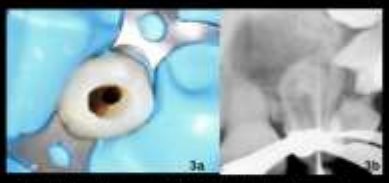

Img. 3 (a) Coronal access and (b) Working length, MP: 18 mm and DV: 18.5 mm.

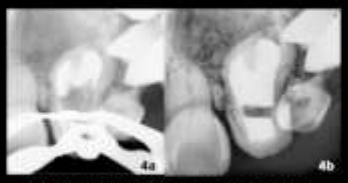

Img. 4 (a) Sealing with EndoSequence BC Sealer. (b) BC RRM Putty.

Img.5 Granulomatous tissue enucleation.

Img. 6 Retro-preparation.

Img. 7 Retro-preparation radiography.

Img. 8 Retro-sealing with bioceramic.

Img. 9 Collagen membrane 20mm x 30mm (Mitex)

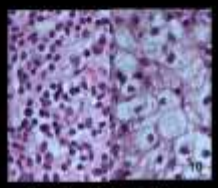

Img 10 Chronic inflammatory infiltrate 40X

SURGICAL PROCEDURE

One month after the root canal treatment it was performed an apical surgery. The patient was anesthetized and a full-thickness flap raised. Curettage of the lesion was performed (Img. 5). Apical portion was resected, locating two canals, one in "C" shape and the other elliptical (Img.6). They were retro-prepared and irrigated with saline (Img. 7). Canals were dried with sterile paper points and sealed with EndoSequence BC RRM Putty (Brasseler USA) (Img. 8). A 20mm x 30mm collagen membrane (Mitex) was placed, sutured with 5-0 Nylon (Img. 9). After four days, the sutures were removed. The histopathological study of the lesion showed evidence of apical granuloma (Fig. 10). The radiographic control at 10 months (Img. 11) showed evidence of bone neoformation.

Img. 11 Control X-ray 10 months

DISCUSSION

Despite the high success rate of root canal treatment, cases presenting complex anatomical variations represent a challenge in order to properly disinfect the root canal system. There are factors identified as causes of persistent apical periodontitis, either residual intraradicular infection or extraradicular infection are among these factors, specially in complex anatomy cases. The endodontic surgery modality represents an alternative in cases where conventional root canal treatment has failed. Because during surgical process the apical portion of the tooth is removed and there is a mechanical ultrasonic cleaning of the area as well as placement of a sealing material.

CONCLUSIONS

CBCT is a highly valuable tool for diagnosis and treatment planning.

In dens in dent type III cases with complex anatomy and extensive apical periodontitis, sometimes conventional therapy requires a surgical complement to perform an adequate apical seal.

REFERENCES

1. Ahmed HMA et al. *A new system for classifying tooth, root and canal anomalies* Int Endod J.2018; 51:389–404
2. Hülsmann M et al. *Dens invaginatus: aetiology, classification, prevalence, diagnosis, and treatment considerations.* Int Endod J.1997; 30:79-90
3. Sousa SMG et al. *Dens invaginatus: treatment choices.* Endod Dent Traumatol 1998; 14: 152-8
4. Agrawal PK et al. *A Rare Case of Type IV Dens Invaginatus in a Mandibular Second Premolar and Its Nonsurgical Endodontic Management by Using Cone-beam Computed Tomography: A Case Report.* J Endod 2016; 42:649-72
5. Oehlers FAC. *Dens invaginatus (dilated composite odontome) I. Variations of the Invagination Process and Associated Anterior Crown Forms* Oral Surg, Oral Med, Oral Pathol 1957; 10:1204-18

Management of persistent intra-canal exudate with combination of surgical/orthograde technique: A case report

Sharifa AlMukhiazeem[1], Arindam Dutta[2]
Cardiff Dental School & Hospital, United Kingdom

AIM

Management of persistent purulent discharge from the root canal of the maxillary left lateral incisor tooth using multi-visit non-surgical techniques in the first instance followed by a combination surgical-non surgical approach in one visit.

INTRODUCTION

Presence of persistent signs and symptoms of periapical disease including copious purulent discharge and clear serous transudate may be influenced by intra-radicular infection persisting in the complex apical anatomy of the root canal, extra-radicular biofilm or indeed infection and the accumulation of endogenous cholesterol crystals which may be related to a true cystic lesion.

CASE PRESENTATION

A 56 year old male patient presented with a history of intermittent dull pain in UL2 over two years which was also associated with episodes of swelling. The general dentist had prescribed antibiotics and referred the patient to the dental hospital owing to a very large lesion associated with the tooth.

CLINICAL & RADIOGRAPHIC EXAMINATION

Figure 1 – UL2 previously root treated with gingival recession, sinus tract absent, non TTP, TTP, +ve

Figure 2 – Low lip line

Figure 3 – Suboptimal root filling & very large PA lesion

TREATMENT

- UL2 was retreated in an orthograde fashion in the first instance and this involved removal of the existing gutta percha using Reciproc® Blue R40. Apical gauging was equivalent to a K-file size 70 initially.
- Patient was seen for 4 visits on a weekly basis, and treated conventionally using modified double flare technique, static irrigation with 1% NaOCl and calcium hydroxide (Hydrocal, Cerkamed) powder and water mixed as paste chairside for intracanal medication (ICM). Purulent exudate persisted (Fig 5).
- Visit 5: 1% NaOCl and passive ultrasonic irrigation (PUI) used copiously for irrigation & smear layer removed with 17% EDTA with PUI. Pre-mixed calcium hydroxide aqueous paste (Hypo-cal®, Ellman Int Inc) placed as ICM. Persistent clear discharge still seen welling-up through the root canal with inability to dry canal. Stab incision made in buccal sulcus to release fluid, but without any success.

Figure 4 – Working length radiograph

Figure 5 – Copious purulent discharge from the canal

Fig6- Calcium hydroxide powder as ICM

- Calcium hydroxide dry powder (Hydrocal, Cerkamed) packed into root canal to help reduce transudate at visit 6. Visit 7 revealed no improvement.
- Combined surgical- non surgical approach used. Papilla based flap (Fig 7a) revealed large defect (Fig 7b, c). 2-3 mm of root-end was resected (Fig 7e), granulation tissue curetted (Fig 7c, d) & ribbon gauze placed in crypt. Disinfected rubber dam placed while flap was raised, canal disinfected & orthograde ProRoot® MTA plug placed (4mm) (Fig. 7f). Remainder canal back-filled with injectable thermoplasticized gutta percha (ITGP), and access provisionalised (Fuji IX®, GC) (Fig 7g). Surgery completed with guided tissue regeneration using anorganic bovine bone xenograft (Bio-Oss®, Geistlich) and porcine collagen membrane (Bio-Gide®, Geistlich) (Fig 7h). Sutured papillae with 6-0 Prolene® (Ethicon) and vertical release incisions with 4-0 Vicryl® (Ethicon) (Fig 7i). Sutures were removed at 4 days (Fig 7j).

Figure 7a

Figure 7b

Figure 7c

Figure 7d

Figure 7e

Figure 7f

Figure 7g

Figure 7h

Figure 7i

Figure 7j

Figure 8a

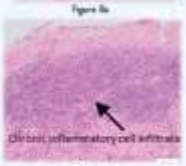

Figure 8b

Figure 8c

DISCUSSION

The presence of a very large apical lesion is known to reduce the success of non-surgical endodontic treatment (1). This patient had a very large lesion with a diameter of approximately 18mm that also extended coronally, but with intact interdental alveolar crests. The inability to dry root canals has been previously reported, and extraradicular biofilm is a frequent cause (2). Even though several strategies such as irrigant activation (3) and calcium hydroxide in different aqueous formulations were used, purulent discharge continued unabated. Chairside aqueous mix of Hydrocal® may have led to quick ionic dissociation and thus a more viscous commercial paste with sustained levels of high pH over two weeks was used as an alternative medicament (4). However, as clear fluid continued to well-up in the canal, a dry mix of calcium hydroxide powder was packed in to the root canal, which helped reduce, but not eliminate the periapical transudation and this has been previously reported (5). The surgical-non surgical joint approach helped achieve adequate dryness in the canal, but rather than follow a traditional approach in such cases where ITGP was used for the entire root canal filling and burnished apically through the crypt, we chose to place a calcium silicate cement as an orthograde apical plug. The orthograde approach was preferred for MTA placement, as root-end filling carries the usual challenges of difficult handling and placement with this product. The material, however, is biocompatible, bioactive, and will promote regeneration of the apical periodontal ligament and cementum.

CONCLUSION & CLINICAL RELEVANCE

Even though the mainstay of endodontic retreatment continues to remain in the non-surgical domain, the management of large periradicular lesions & consistently wet root canals can be successfully achieved by using a combination of surgical & non-surgical approaches in one visit.

References
1. Ng YL, Mann V, Gulabivala K. A prospective study of the factors affecting outcomes of nonsurgical root canal treatment: part 2: periapical health. Int Endod J. 2011;44(7):610-625. doi:10.1111/j.1365-2591.2011.01872.x
2. Ricucci D, Siqueira JF, Bate AL, Pitt Ford TR. Histologic investigation of root canal-treated teeth with apical periodontitis: a retrospective cohort study and review of the literature. J Endod. 2009;35(493):493-502. doi:10.1016/j.joen.2009.01.011
3. Siqueira JF, Rôças IN, Huang G, Rôças IN, Rôças IN, Rôças IN. Polymicrobial nature of root canal infections with apical periodontitis. J Endod. 2008;34(1):1-10. doi:10.1016/j.joen.2007.09.012
4. Vera J, Siqueira EL, Ordinola-Zapata R, Duncan HF, Cohenca N, Ramos-Sánchez M, Oliveira HG, Almeida RZ. Long-term evaluation of root canal treatment with apical extrusion of calcium hydroxide-based root canal medicament. J Endod. 2012;38(8):1092-1096. doi:10.1016/j.joen.2012.04.016
5. Trope M, Chivian N. Long-term use of calcium hydroxide dressings in the treatment of apical periodontitis. Quintessence Int. 1987;18(3):177-179.

[1]Second year postgraduate dentist (MClinDent Endodontology) [2] Consultant in Restorative Dentistry. Acknowledgements: Dr. Jones for pathology photographs & Dr. Alhowli for helping design the poster.

CLINICAL MANAGMENT OF A TRIPLE AVULSION OF A PERMANENT MAXILLARY INCISORS: A CASE REPORT

Dr. Sofia DROURI, Dr. Sara DHOUM, Pr. Jalila DAKKAKI, Pr. Mouna JABRI, Pr Said. DHAIMY
Department of endodontics, CCTD, Hassan II University, School of dental medicine, Casablanca-Morocco

Introduction & aim

Dental avulsion is the most severe type of traumatic tooth injuries because it causes damage to several structures and results in the complete displacement of the tooth from its socket in the alveolar bone. The ideal situation is to replant tooth immediately after avulsion because the extraoral time is a determinant factor for treatment success and for a good prognosis.

Avulsion of permanent teeth is a common and complex injury which affects multiple oral tissues. Prompt and correct emergency management is very important for the prognosis.

The aim of this report is to present a successful replantation of 3 avulsed permanent maxillary incisors.

Case report

25 years old female patient was referred urgently to endodontic department of faculty of dentistry, Casablanca Morocco, 60 minutes after an assault causing dental avulsions.

Fig1: Pre-operative view (May 2017)

Fig2-3: avulsed teeth conserved in milk for 1 hour

Fig4: Panoramic radiograph showing empty dental alveolus

Fig5: Immediate reimplanted and splinted teeth 11, 21, 22

Fig6-7: Initial treatment of root canals was done one week after their reimplantations -obturation canals after 4 weeks medication with calcium hydroxide treatment

Fig8: 21 months post trauma

Fig1: 1 week post-trauma

Fig1: 6 weeks post-trauma

Fig1: 21 months follow-up (February 2019)

Discussion

The success of replantation depends on a number of factors that may contribute to accelerate or minimize the occurrence of root resorption or ankylosis, among which is the type and characteristics of the medium used for temporary storage during the time elapsed between avulsion and replantation. Maintaining the tooth in an adequate wet medium that can preserve, as longer as possible, the vitality of the periodontal ligament cells that remain on root surface is the key to success of replantation.

Milk has several favorable characteristics as a storage medium for avulsed teeth, it contains epithelial growth factor (EGF), which stimulates the proliferation and regeneration of epithelial cell rests of Malassez and activates the alveolar bone resorption.

It is important to highlight that avulsion is a severe dental injury; if it is managed immediately and appropriately, the avulsed teeth can be preserved and be functional for some years. The two year follow-up indicated success of this treatment protocol.

Conclusions and clinical relevance

Although acceptable results were observed in the two-year follow-ups, further observation is required.

The prognosis of a replanted tooth and its maintenance on the dental arch for the longest possible time depends on the viability of the periodontal ligament (PDL) cells remaining on root surface, integrity of root cementum and minimal bacterial contamination, which are conditions directly related to the extra-alveolar time, type of storage after avulsion and root surface alterations.

References

-Ali R. Pai, C.K. Sumeda, Ch.Mamata, M.K.Mala, E.P.Pallavee, M.R.Mandanna, S.R.Prasanna
Storage Media For Avulsed Teeth: A Literature Review. Brazilian Dental Journal (2013) 24(5): 497-501
-Gowrawni M, Chaitra TR, Choudhary S, Mangla N, Sinha A.
Strategies for periodontal ligament cell viability: an overview. J Conserv Dent 2011;14:215-220.
-Malhotra N. Current developments in interim transport (storage) media in dentistry: an update. Br Dent J 2011;211:28-33.
-Çağlar E, Sandalli N, Kuzu OO, Durhan MA, Pestrailar B, Cildoğan EA, et al.
Viability of Hankin's in a novel prototype storage media. Dent Traumatol 2010;26:383-387.
-Carder LC, Dos WR, Pazzatto SE, Sonada CE, Rodrigues TS, Machado TM.
Knowledge of firefighters with special paramedic training of the emergency management of avulsed teeth. Dent Traumatol 2009;25:38-43.

ONE-VISIT RESTORATION OF THE FRACTURED TEETH INVOLVING PULP WITH BIODENTIN AND DIRECT COMPOSITE RESIN

Tatjana Savic Stankovic [1], Bojan Dzeletovic [1], Violeta Petrović [1]

[1]DentalNet Research Group, Department of Restorative Odontology and Endodontics, School of Dental Medicine, University of Belgrade

Aim

The aim of this case report is to illustrate the use of Biodentine as a pulp capping material after pulp exposure due to trauma.

Introduction

Calcium silicate based cements currently represent materials of choice for direct pulp capping due to their ability to maintain pulp vitality and stimulate hard tissue formation.

Case Presentation

A 19 years old male patient visited Department of Conservative Dentistry and Endodontics, School of Dental Medicine, University of Belgrade. The patient reported that a trauma involving his upper interior teeth had occurred 2 hours prior. Clinical examination revealed class IV fractures of both upper central incisors (11,21) with pulp exposure. Also, at the gingival third of the palatal surface of the tooth 21, enamel delamination without pulp exposure was observed. Involved teeth showed no sensitivity on vertical and lateral percussion and periapical palpation and responded to the electric pulp testing similar as neighboring teeth. Radiographic evaluation of teeth 11 and 21 revealed absence of root fractures and periapical pathoses. Since the clinical and radiographic signs indicated healthy, vital pulps of the involved teeth, direct pulp capping procedure was performed (Fig. 1).

Figure 1. Fractured upper incisors with pulp exposure

Methodology

After local anesthesia with 2% Lidocaine with 1:100 000 adrenaline Septanest (Septodont, France) and hemostasis, exposed pulps with surrounding dentine were capped with freshly prepared Biodentine (Septodont, France), mixed as recommended by the manufacturer. Enamel defect on the palatal surface of the tooth 21 was also covered with Biodentine. After Biodentine was set, (approximately 12 minutes) the fractured crowns were restoeed with direct composite restorations (Gradia Direct, GC, Japan) using a one-step self-etch adhesive and three shades of composite resin (AO1, A1, WT) in a layering technique (Fig. 2 and 3).

Figure 2. Direct pulp capping with Biodentine

Figure 3. Direct composite restoration of 21

The outcome of the performed treatment was evaluated by pulp sensitivity tests (thermal and electric) and radiographic examination at 1, 3, and 6 months intervals. After 6 months the teeth were asymptomatic with normal response to pulp sensitivity tests and negative for percussion and palpation tests. Radiographic evaluation showed no periapical radiolucency (Fig. 4). Satisfactory esthetic and functional outcomes were achieved (Fig. 5 a), b) and c)).

Discussion

Bioactive $Ca(OH)_2$ releasing silicate cements such as MTA or Biodentine, stimulate reparative dentinogenesis similar or even better than $Ca(OH)_2$-based mixtures. In this case, Biodentine was chosen for pulp capping because of its shorter setting time and lower potential for tooth staining compared to MTA. Biodentine may induce complete dentin bridge formation with well-arranged odontoblast and odontoblast-like cells and no inflammatory response. Using a one-step self-etch adhesive following the "self-etch" protocol allowed restoration without the acid-rinsing step and prevented potential displacement of the freshly applied Biodentine.

Figure 4. Post-operative recall radiograph after 6 months

Figure 5. a), b) and c) Satisfactory esthetic results

Conclusion

Obtained results suggest that the use of Biodentine for pulp capping in a single-step restoration procedure may result in a successful treatment outcome.

References

1.Hilton TJ, Ferracane JL, Mancl L. Comparison of CaOH with MTA for direct pulp capping: A PBRN randomized clinical trial. J Dent Res. 2013 ;92:165-229.
2.Tziafa C, Koliniotou-Koumpia E, Papadimitriou S, Tziafas D. Dentinogenic responses after direct pulp capping of miniature swine teeth with Biodentine. J Endod 2014;40:1967-1971
3.Nowicka A, Lipski M, Parafiniuk M, Sporniak-Tutak K, Lichota D, Kosierkiewicz A, et al. Response of human dental pulp capped with Biodentine and Mineral trioxide aggregate. J Endod 2013;39:743-7

Reattachment of Fractured Maxillary Incisor Using Fiber Reinforced Post: A Case Report

Ekin Su Ertürk, Rouzbeh Fazeli, Tugba Türk
Ege University Department of Endodontology, İzmir Turkey

AIM

The purpose of this case presentation is to report the treatment of maxillary central incisor with complicated crown-root fracture.

İNTRODUCTİON

A crown–root fracture is defined as a fracture involving enamel, dentin and cementum and may be classified as either complicated or uncomplicated according to the pulpal involvement . While crown fractures occur most frequently in the permanent dentition, crown–root fractures account for 5% of all traumatic injuries.

CASE PRESENTATION

A 13-year-old boy applied to the dental clinic because of luxation at the crown of tooth number 11 and spontaneous pain. The tooth was diagnosed as an oblique crown–root fracture, with detection of fracture lines by radiographic examinations. A local anaesthetic was administered and the coronal segment was removed with minimal force from its soft tissue attachment and recovered and stored in sterile distilled water to prevent dehydration. The working length was determined with an electronic apex locater. The root canal was enlarged to size 80 at working length. Sodium hypochlorite (2.5%) (Ace, İstanbul, Turkey) and EDTA (17%) (Merck, Darmstadt, Germany) were used for irrigation. The root canal was dried with paper points, obturated using cold lateral compaction technique. After root canal filling, post space was prepared by post drill. Acid-etch was applied to coronal fragment and post space. Fiber glass post (Ultradent, Utah, USA) and coronal fragment were bonded to the tooth using dentin-bonded resin (Sun Medical, Shiga, Japan). Clinical and radiological examinations were performed regularly.

DISCUSSION

After 2 years follow up, the tooth was in function with satisfactory clinical, radiographic and aesthetic results.

CONCLUSION

Reattachment of the coronal segment to a fractured tooth enhances the aesthetic by retaining natural translucency and surface texture of tooth.

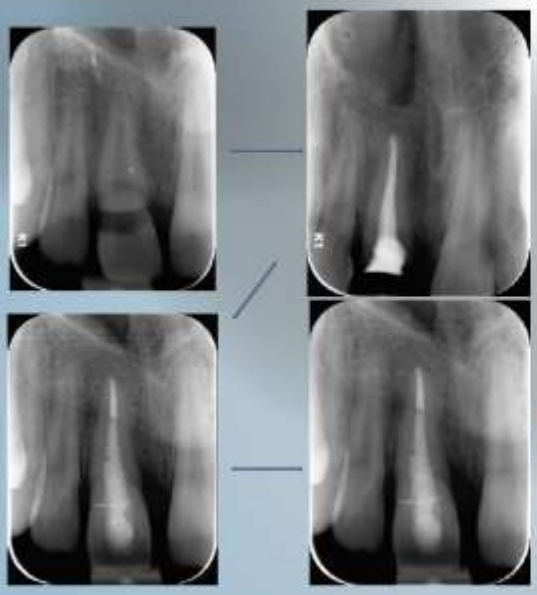

2 YEARS FOLLOW UP

References

1.Mirfis AS. Vertical root fractures. Oral Surg Oral Med Oral Pathol 1990;69:631–6.
2. Gher Jr M, Dunlap R, Anderson M, Kuhl L. Clinical survey of fractured teeth. J Am Dent Assoc. 1987;114(2):174.
3. Sugaya T, Kawanami M, Noguchi H, Kato H, Masaka N. Periodontal healing after bonding treatment of vertical root fracture. Dent Traumatol. 2001;17(4):174–6.
4.Taschieri S, Tarese A, Del Fabbro M, Rosano G, Tsesis I. A new surgical technique for preservation of endodontically treated teeth with coronally located vertical root fractures: a prospective case series. Oral Surg Oral Med Oral Pathol Oral Radiol Endod. 2010;110(5):e45–52.

SATURDAY

C44

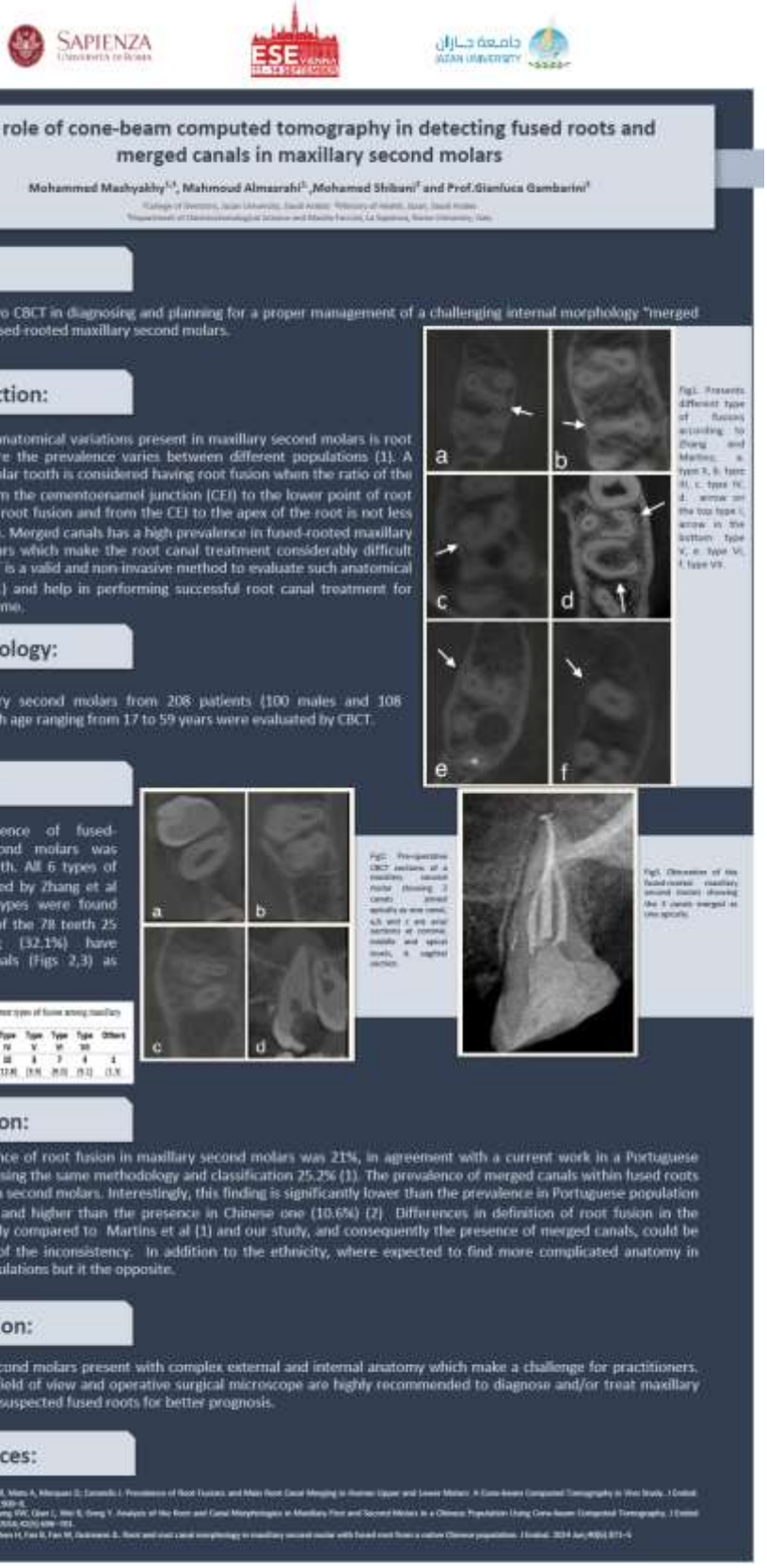

The role of cone-beam computed tomography in detecting fused roots and merged canals in maxillary second molars

Mohammed Mashyakhy[1,4], Mahmoud Almasrahi[1], Mohamed Shibani[2] and Prof.Gianluca Gambarini[3]

[1]College of Dentistry, Jazan University, Saudi Arabia [4]Ministry of Health, Jizan, Saudi Arabia
[3]Department of Gastroenterological Science and Medico Forensic, La Sapienza, Rome University, Italy

Aim:

To use in vivo CBCT in diagnosing and planning for a proper management of a challenging internal morphology "merged canals" in fused-rooted maxillary second molars.

Introduction:

One of the anatomical variations present in maxillary second molars is root fusion, where the prevalence varies between different populations (1). A maxillary molar tooth is considered having root fusion when the ratio of the distance from the cementoenamel junction (CEJ) to the lower point of root furcation or root fusion and from the CEJ to the apex of the root is not less than 70% (9). Merged canals has a high prevalence in fused-rooted maxillary second molars which make the root canal treatment considerably difficult (1,2,3). CBCT is a valid and non-invasive method to evaluate such anatomical variations (1) and help in performing successful root canal treatment for better outcome.

Fig1. Presents different type of fusions according to Zhang and Martins: a. type II, b. type III, c. type IV, d. arrow on the top type I, arrow in the bottom type V, e. type VI, f. type VII.

Methodology:

372 maxillary second molars from 208 patients (100 males and 108 females) with age ranging from 17 to 59 years were evaluated by CBCT.

Results:

The prevalence of fused-rooted second molars was 21%, 78 teeth. All 6 types of fusion defined by Zhang et al and extra types were found (Fig1). Out of the 78 teeth 25 representing (32.1%) have merged canals (Figs 2,3) as examples.

Frequency and percentage of different types of fusion among maxillary second molars

Fused teeth	Type I	Type II	Type III	Type IV	Type V	Type VI	Type VII	Others
78	9 (11.5)	28 (36.0)	8 (10.4)	10 (12.8)	8 (9.9)	7 (9.0)	4 (5.1)	1 (1.3)

Fig2. Pre-operative CBCT sections of a maxillary second molar showing 3 canals joined apically as one canal, a,b and c are axial sections at coronal, middle and apical levels, d sagittal section.

Fig3. Obturation of the fused-rooted maxillary second molars showing the 3 canals merged as one apically.

Discussion:

The prevalence of root fusion in maxillary second molars was 21%, in agreement with a current work in a Portuguese population using the same methodology and classification 25.2% (1). The prevalence of merged canals within fused roots was 32.1% in second molars. Interestingly, this finding is significantly lower than the prevalence in Portuguese population (62.3%) (1), and higher than the presence in Chinese one (10.6%) (2). Differences in definition of root fusion in the Chinese study compared to Martins et al (1) and our study, and consequently the presence of merged canals, could be the reason of the inconsistency. In addition to the ethnicity, where expected to find more complicated anatomy in Chinese populations but it the opposite.

Conclusion:

Maxillary second molars present with complex external and internal anatomy which make a challenge for practitioners. CBCT small field of view and operative surgical microscope are highly recommended to diagnose and/or treat maxillary molars with suspected fused roots for better prognosis.

References:

1. Martins JNR, Marques D, Mata A, Marques D, Lemos C. Prevalence of Root Fusions and Main Root Canal Merging in Human Upper and Lower Molars: A Cone-beam Computed Tomography in Vivo Study. J Endod. 2018; 42(8): 909–8.
2. Tian XM, Yang XW, Qian J, Wei B, Gong Y. Analysis of the Root and Canal Morphologies in Maxillary First and Second Molars in a Chinese Population Using Cone-beam Computed Tomography. J Endod [Internet]. 2016; 42(5): 698–701.
3. Zhang Q, Chen H, Fan B, Fan W, Gutmann JL. Root and root canal morphology in maxillary second molar with fused root from a native Chinese population. J Endod. 2014 Jan;40(1): 571–5.

Root Canal Retreatment of a Maxillary Second Premolar with Three Roots: A Case Report

Manal H. Alothmani
R3 Saudi Endodontic Board Resident

Introduction

Root canal anatomy may present clinicians with complex clinical challenge that requires utilization of variety of diagnostic approaches, access cavity modifications and employment of advanced endodontic armamentarium coupled with considerable clinical skills to successfully localize, negotiate, disinfect and seal the root canal system. New technologies, instruments & materials have provided better diagnoses and more detectable endodontic therapies. However, despite all these improvements, the overall outcomes, especially of non-surgical endodontics, has not increased significantly (1,2). This is probably due to the fact that there are two important factors directly related to prognosis: predictable eradication of microorganisms & access to the full anatomy of the canal system in which they might be harbored (3,4). According to the literature, three-rooted maxillary premolars usually have a mesiobuccal, a distobuccal and a palatal canal (5). However, the present case report describes the treatment challenges of a three-rooted maxillary second premolar with two buccal roots and one palatal root with three canals aligned side by side in bucco-lingual direction.

Case Report

A 52-year-old male with non-contributory medical history reported to the Department of Endodontics with the chief complaint of pain upon biting in his upper right posterior area for few months. On clinical examination there was an old composite restoration on the second premolar (#15) which seemed adequate clinically yet discolored & probing depth within normal limits. Radiographic assessment disclosed that #15 was previously root-filled with missed root since the obturation was not centered. There was a lateral radiolucency seen towards the palatal side of the root. Patient said he received the treatment 12 years ago.

A diagnosis of previously treated tooth with symptomatic apical periodontitis was made and non surgical-endodontic retreatment was initiated.

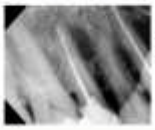

Image 1: Periapical radiographs for #15.

Treatment Procedure

After rubber dam isolation and gaining access, the previously treated canal was visible in the middle of the chamber. The chamber was covered with previous composite restoration and the missed canal was calcified coronally. With the aid of dental operating microscope (DOM) and ultrasonics canal was located. Previous root filling material was removed, working length was performed with apex locator. Canals were instrumented using ProFile® (Dentsply Sirona) accompanied with 5.25% NaOCl irrigation. Final Flush with 17% EDTA followed by 5.25% NaOCl solution was done. Canals were obturated by continuous wave compaction technique down-pack with thermoplasticized GP backfilling and AH Plus sealer. Access cavity was cleaned then restored with Cavit ™ & GI restoration.

Final PA revealed that the obturation was asymmetrical indicating likelihood for a missed canal (Image 2). Patient was rebooked.

Image 2: Periapical radiographs showing the missed palatal root.

On the **second visit**, all procedures were carried out under DOM and rubber dam isolation. Access was gained through restoration and the two canal orifices already obturated were covered with flowable composite.

Access was extended palatally and the canal was located. Working length determination was done & periapical radiograph taken with a more than 40-degree horizontal angulation to disclose all three canals (image 3). Instrumentation, irrigation and obturation was performed as mentioned earlier and tooth was sealed with Cavit ™ & GI restoration (image 4).

Image 3: Clinical Picture before and after obturation of the missed root.

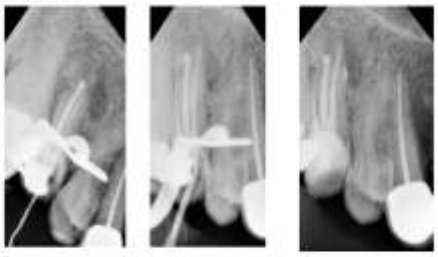

Image 4: MESIAL SHIFT MORE THAN 40 DEGREE angulation showing (a)working length radiograph. (b) Master cone radiograph. (c) Obturation with final restoration.

Image 5: Upon follow up after six months, patient reported with a temporary crown asymptomatic with reduction in the carefaction.

Discussion

Accurate evaluation of pre-operative radiographs is essential to detect extra roots/canals. If some anatomic variations are suspected during the radiographic examination then it is preferred to take additional radiographs form mesial and distal angulations to get extra information & also acquire CBCT with limited field of view. Fava and Dummer (6) suggested to acquire radiographs with different horizontal angles to achieve a clear realization of the morphology of the tooth.. Without the aid of the DOM and ultrasonics this wouldn't have been possible. In today's endodontic practice, aberrant anatomy has become more common than before.

Conclusion

Morphological variations in the pulpal anatomy must be always considered before start of treatment. Clinicians should be aware of anatomical variations in maxillary premolars and be able to apply the knowledge in radiographic and clinical interpretation.

References

1. Ng YL, Mann V, Rahbaran S, Lewsey J, Gulabivala K. Outcome of primary root canal treatment: systematic review of the literature – Part 1: Effects of study characteristics on probability of success. Int Endod J. 2007; 40 (12):921-39.
2. Ng YL, Mann V, Rahbaran S, Lewsey J, Gulabivala K. Outcome of primary root canal treatment: systematic review of the literature - Part 2: Influence of clinical factors. Int Endod J. 2008; 41 (1): 6-31.
3. Sjogren U, Figdor D, Persson S, Sundqvist G. Influence of infection at the time of root filling on the outcome of endodontic treatment of teeth with apical periodontitis. Int Endod J 1997; 31 (2):96.
4. Van ISV, Henry S, Cano V, Vera J. Microbial status of apical root canal system of human mandibular first molars with primary apical periodontitis after "one visit" endodontic treatment. Oral Surg Oral Med Oral Pathol Oral Radiol Endod 2005; 99(2):231-52.
5. Sarendo SM, Taylor GN, Kuhn RA. Identification and endodontic management of three-rooted maxillary premolars. J Endod. 1989; 15(1):29-32.
6. Fava L.R.G., Dummer P.M.H. Periapical radiographic techniques during endodontic diagnosis and treatment. International Endodontic Journal. 1997; 30 (4):250-261.

SAPIENZA
UNIVERSITÀ DI ROMA

ROOT CANAL MORPHOLOGY OF LOWER LATERAL INCISORS: A CBCT STUDY IN VIVO IN A EUROPEAN POPULATION

Federico Valenti Obino [1], Linda Quero [2], Gianfranco Gaimari [3], Massimo Galli [4], Gianluca Gambarini [5], Luca Testarelli [6]

1-DDS, PhD student, Sapienza University of Rome, Dept. of Oral&Maxillofacial Science
2-Student, Sapienza University of Rome, Dept. of Oral&Maxillofacial Science
3-DDS, PhD, Sapienza University of Rome, Dept. of Oral&Maxillofacial Science
4-Research Professor, DDS, PhD Sapienza University of Rome, Dept. of Oral&Maxillofacial Science
5-Ordinary Professor, DDS, PhD Sapienza University of Rome, Dept. of Oral&Maxillofacial Science
6-Associate Professor, MD, PhD, Sapienza University of Rome, Dept. of Oral&Maxillofacial Science

AIM

The aim of the present poster is to analyze the root canal configuration in lower lateral incisors using cone-beam computed tomography imaging.

INTRODUCTION

The use of CBCT to study root canal anatomy overcomes the limitations of conventional radiography because:

1) it is a noninvasive tool that can provide images displayed in coronal, sagittal and axial planes;

2) a large number of teeth that can be examined with the same exposure to the X-rays;

3) it can provide a precise location of the tooth, it gives the possibility of making right and left symmetrical evaluations;

4) it allows the study of the three-dimensionality of the tooth in its entirety.

METHODOLOGY

A total of 100 lower lateral incisors from 50 patients were examined using CBCT imaging, previously taken for diagnosis and treatment.

The data concerning the number of roots, root canal system configuration, presence of apical confluences, distance between confluences and radiographic root end, symmetry between left and right elements were collected and statistically analyzed.

Figure 1
Type I: single canal from the pulp chamber to the apex.

Figure 2
Type II: two different canals emerge from the pulp chamber but converge to the apex.

Figure 3
Type III: a canal emerges from the pulp chamber, divides into two within the root and emerges into one at the apex.

Figure 4
Type VII: one canal in the pulp chamber that divides and rejoins within the root, and redivides into two canals at the apex.

DISCUSSION

All the examined lower lateral incisors presented only one root.

Type I Vertucci configuration was present in 53% of cases, type II Vertucci configuration in 30% of cases, type III Vertucci configuration in 15 % of cases, type VII Vertucci configuration in 2% of cases. Other configurations were not found.

Apical confluences were present in all the incisors with a type II, type III and type VII Vertucci configuration. Overall there was 47% of confluences in lateral incisors.

The average distance between confluences and radiographic root end was 3,102mm in type II Vertucci configuration and 3,234mm in type III Vertucci configuration. The distance in type VII was 2,802 mm.

Symmetry was found in 86% of cases.

CLINICAL RELEVANCE

Diagnostic imaging is an essential element of preoperative diagnosis. In fact, it is important to have knowledge of internal anatomical complexities, such as the number of canals, their shape, along with the presence of curves, confluences and bifurcations before undertaking endodontic therapy: the main objective of root canal therapy is shaping and cleaning all pulp spaces. This study highlights that 3D preoperative analysis helps in understanding endodontic anatomy.

REFERENCES

1.Scarfe WC, Levin MD, Gane D, Farman AG. Use of cone beam computed tomography in endodontics. Int J Dent 2009;2009:634567.
2.Vertucci FJ. Root canal morphology and its relationship to endodontic procedures. Endod Top. 2005;10:3–29.
3.Benjamin KA, Dowson J. Incidence of two root canals in human mandibular incisor teeth. Oral Surg Oral Med Oral Pathol 1974;38:122-6.

C47 WITHDRAWN

CLINICAL MANAGEMENT OF SEVERE INFLAMMATORY ROOT RESORPTION: A CASE REPORT

J. Nešković[1], V. Opačić-Galić[1], B.Dželetović[1]

1.Department of Restorative Odontology and Endodontics, School of Dental Medicine, University of Belgrade, Serbia

Aim: To discuss the use of MTA as a material for root canal obturation in case of severe inflammatory root resorption.

Figure 1.

Introduction: Inflammatory root resorption (IRR) is an external apical resorption, commonly caused by apical periodontitis, traumatic injuries or excessive orthodontic forces, that leads to progressive loss of root structure. Root canal treatment should stop the further resorption and, even more challenging, to enable regeneration of periradicular structures.

Case Presentation: A 23-year-old patient was referred from dental clinic for evaluation and treatment of the mandibular left first molar. Tooth was painful and palpation and percussion tests also induced pain. OPT radiography showed severe inflamatory resorption of distal root, 5mm shorter than the mesial root which had periapical radiolucency (Fig 1). After debridement of granular tissue from the distal and infected contents from the mesial canals, instrumentation, pure calcium hydroxide mixed with distilled water was placed in the canals the first week. Symptoms disappeared after the first appointment. The calcium hydroxide was renewed every 2 week for 3 month. Both distal canals were obturated by MTA powder mixed with distilled water and packed into 10 mm of the apical end and the working length was up to the healthy dentine. Coronal third of distal canals and both of mesial canals were sealed with gutta-percha AH Plus (Fig 2). Tooth was restored with glass ionomer cement and composite resin. Nine months follow-up showed that the external root resorption had been arrested, and the periapical lesion had healed (Fig 3). After one year, no symptoms or signs were noted, and radiography showed regeneration of the cement and periodontal ligament, and remineralization of the periapical bone with the formation of the lamina dura (Fig 4).

Figure 2.

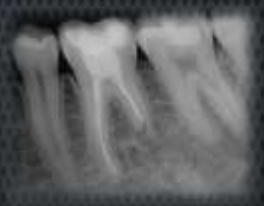

Figure 3.

Discussion: MTA is bioactive material based on calcium silicate which poses biocompatibility, antibacterial properties, marginal adaptation and sealing properties, and hydrophilic nature. It has been extensively studied and is currently used for perforation repairs, apexification and apexogenesis, pulpotomies, pulp capping, retrograde filling in apicoectomy but also internal and external resorptions. MTA stimulates reparation and regeneration of cement and periodontal ligament, induces remineralization of periapical tissue.

Figure 4.

Conclusion & Clinical Relevance: MTA may be considered as an alternative sealer for the treatment of inflammatory root resorption.

References:

1. Fuss Z, Tsesis I, Lin S. Root resorption - diagnosis, classification and treatment choices based on stimulating factors. Dent Traumatol 2003;19: 175-182.
2. Parirokh M, Torabinejad M. Mineral trioxide aggregate: a comprehensive literature review Part III – Clinical applications, drawbacks and mechanisms of action. J Endod. 2010 Mar;36(3):400-13.
3. Camilleri J. Mineral trioxide aggregate: present and future developments. Endod Topics. 2015 May;32(1):31-4.

Retreatment of a Mandibular Molar with Apical Resorption using MTA Plugs: a Case Report.

Daniela Ruiz C. D.D.S, Danilo Fernandez S. D.D.S, Eduardo Baeza M. D.D.S.
Private Practice, Chile

Aim

To demonstrate the nonsurgical retreatment of a mandibular molar with inflammatory apical external root resorption (ERR) using apical MTA plugs.

Introduction

Mineral Trioxide Aggregate (MTA) is a bioactive material widely used in endodontics. Among the properties that make this material suitable for ERR are biocompatibility, good sealing property, and promotion of peri-radicular tissues regeneration.

Case Presentation

A 25-year-old male patient syntomatic left lower first molar with endodontic treatment. Clinical history revealed repeated pain and swelling episodes. The periapical radiograph revealed a previously treated lower first molar with overextension of the root canal filling in the distal root, associated with an extensive periapical bone defect and external apical resorption of the distal root. The previous obturation material was removed.

The canals were chemomechanically debrided with stainless steel K-file and 2.5% sodium hyploclorite (NaOCl). Two sessions of intracanal medication of Calcium Hydroxide were carried out and final irrigation protocol with 2.5% NaOCl, 17% E.D.T.A. and saline solution. The apical portion of the distal root was filled with MTA Angelus ® Brazil, and in the next session the mesial root canals and other portion of the distal root canal were sealed with gutta-percha. An occlusal composite was performed as a final restoration . At the 1-year recall, there were no clinical symptoms, and the radiograph revealed satisfactory apical healing and a radiolucent area in the crown that suggest a leakage area.

Discussion

ERR is one of the most difficult dental conditions to treat. It must be sealed with materials that should be biocompatible and favor regeneration of supporting structure. MTA produces three dimensional sealing because of its setting expansion and ability to form an apatite like lager on its surface when it comes in contact with physiologic fluids. Research has demonstrated that MTA can conduct and induct hard tissue formation. In addition MTA has antimicrobial activity that seems to be associated with elevated pH.

Conclusion & Clinical Relevance

Correct debridement of the root canals associated with Calcium Hydroxide medication and MTA apical sealing show excellent clinical outcome. MTA is a material that can be use to avoid surgical treatment.

Kim S. Kratchman S. Microsurgery in Endodontics. first edition. Philadephia: Wiley Blackwell; 2018: 92.
Kutler S. Bogen G. Mineral Trioxide Aggregate Obturation: A Review and Case Series. J Endod 2009;35:777-90.
Cehreli ZC. Sara S. Uysal S. Turgut MD. MTA apical plugs in the treatment of traumatized immature teeth with large periapical lesions. Dent Traumatol. 2011;27:59-2

Quality Of Orthograde MTA Plugs Placed At UDH Cardiff: A Case Series

D.S. Jayawardena [a], A. Dutta [b], M.E. Vianna [c]
Cardiff University/Cardiff & Vale UHB (CVUHB)

AIM: Evaluate the clinical protocol and quality of Mineral Trioxide Aggregate (MTA) apical plugs in the management of open apices during orthograde endodontic treatment & establish local standards for the placement of MTA plugs.

INTRODUCTION: The presence of an open apex can create challenges when placing an orthograde root filling owing to the lack of a stop or an apical constriction. Calcium silicate cements are the current gold standard material for treatment of open apex endodontic cases – be it from resorption, failure of apical development or iatrogenic damage.

Fig. 1-3. Placement of an orthograde MTA plug. Fig. 1 UR1 accessed and shaped with rubber dam in place. Fig. 2. Packing of MTA into UR1 with MAP system (Dentsply) & endodontic pluggers. Fig. 3 UR1 with MTA packed into the apical/middle third of the root canal system.

Fig. 4

METHODOLOGY: A retrospective audit, approved by CVUHB, was conducted on the placement of MTA plugs at Cardiff Dental Hospital. Each clinical case was assessed for placement protocol and radiographic outcome. This included the height of the MTA plug, the presence/absence of voids & radiographic distance from the apex, figure 4 details the protocols evaluated.

RESULTS: A total of 55 cases were identified for data analysis, of which 25.5% (14) cases were for primary endodontic treatment & 75.5% (41) for re-treatment. The MTA plugs were placed by a range of operator grades DCT/SHO (2 – 3.6%), Staff Grade (13 – 23.6%), MClinDent (30 – 54.5%), Consultant (10 – 18.2%). All cases using MTA as the full obturation material were placed in a single visit (9 – 16.4%); all cases in which a secondary root canal seal was placed (e.g. GP or post system) were done in multiple visits (46 – 83.6%). Figure 5 contains a pie chart detailing the justification/reasoning for the use of an MTA plug. Figure 6 shows the final irrigation solution used prior to the placement of the first MTA increment. Follow up data at 1 year is present for 11 cases: 2 have healed, 8 are uncertain awaiting 4 years of monitoring prior to reclassification, and 1 has failed. Further follow up is in progress for the 44 remaining cases.

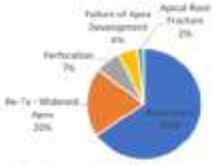

Fig.5. Reason for MTA placement.

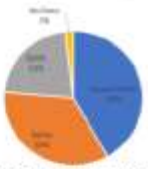

Fig. 6. Final irrigation solution.



Fig. 7. Analysis of radiographic data showing targets met (blue) vs targets missed (yellow).

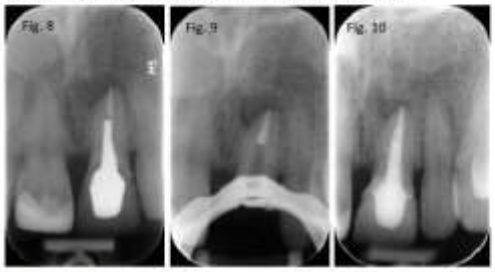

Fig. 8-10. Radiographic examples of MTA within the canal system of an UL1. Fig. 8. Pre operative radiograph of a retreatment case. Fig. 9. Mid treatment radiograph with an MTA plug placed at the root apex. Fig. 10. Post operative radiograph following the placement of MTA & a fibre post with a temporary crown placed over the UL1.

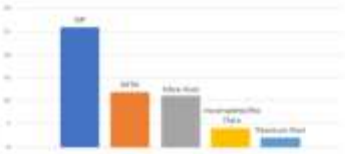

Fig. 11. Obturation or sealing material used to fill the remaining root canal system.

DISCUSSION: MTA is unusual in dentistry in that it sets hard in the presence of moisture, with setting times reported to range from 40 minutes to 175 for ProRoot® MTA (Dentsply Sirona), which is the most commonly used product at Cardiff Dental Hospital. A final rinse of EDTA reduces the hardness and flexural strength of MTA & such practice needs modification at UDH (1). Conversely NaOCl as a final irrigant improves push out bond strengths and is acceptable (2). The key factor for the success of treatment is to create a seal free of microleakage; MTA has been shown to have excellent sealing ability even with minimal thickness of material, provided good adaptation to the canal walls is achieved. However, the greater the height of the MTA plug the greater the resistance to displacement; 3-4mm has been suggested as a sufficient barrier height to predictably withstand the forces placed during obturation (3). MTA has been shown to be biocompatible and bioactive; the extrusion of MTA has limited effect on the success rates for treatment due to low levels of cytotoxicity (4). Even so, MTA is often placed in direct contact with vital tissues oozing blood which impacts its physical properties (5). Clinicians fail to record the extent of blood contamination within the canal at UDH. A future protocol should incorporate this information to help assess factors influencing outcomes of treatment.

CONCLUSION: The audit results indicate that appropriate clinical protocols are used during the placement of an orthograde MTA plug. A high percentage of cases – 72.7% are currently meeting all of the criteria set within figure 7 when assessed cumulatively.

References:
1. Lee Y.-L., Lin F.-H., Wang W.-H., Ritchie H. H., Lan W.-H., Lin C.-P. Effects of EDTA on the hydration mechanism of mineral trioxide aggregate. J Dent Res 2007;86(6):544–9. Doi: 10.1177/154405910708600609.
2. Hong Seong-Taek, Bae Kwang-Shik, Baek Seung-Ho, Kum Kee-Yeon, Shon Won-Jun, Lee Woochan. Effects of root canal irrigants on the push-out strength and hydration behavior of accelerated mineral trioxide aggregate in its early setting phase. J Endod 2010;36(12):1995–9. Doi: 10.1016/j.joen.2010.09.039.
3. Hachmeister Darlene R., Schindler William G., Walker William A., Thomas D. Dennis. The sealing ability and retention characteristics of mineral trioxide aggregate in a model of apexification. J Endod 2002;28(5):386–90.
4. Kok E. T., McDonald F., Pitt Ford T. R., Torabinejad M. Cellular response to Mineral Trioxide Aggregate. J Endod 1999;24(8):543–7. Doi: 10.1016/S0099-2399(06)80074-5.
5. Nakastar M. H., Stone D. F., Duncmer P. M. H. The effect of blood contamination on the compressive strength and surface microstructure of mineral trioxide aggregate. Int Endod J 2010;43(9):782–91. Doi: 10.1111/j.1365-2591.2010.01746.x.

Authors: a – ST1 Restorative Dentistry, b – Consultant in Restorative Dentistry, c – Professor of Endodontology

Acknowledgements: Fig. 1, Fig. 2, Fig. 3 – Photographs courtesy of Dr J Carter & Mr M Locke. Fig. 8, Fig. 9, Fig. 10 – Radiographs courtesy of Dr S Dixi

Mineral Trioxide Aggregate in a Dens In Dente Coronal Third Root Perforation

Danilo Fernandez S. D.D.S, and Daniela Ruiz C. D.D.S,
Private Practice, Chile

Aim

Demonstrate resolution of root perforation with MTA sealing.

Introduction

Mineral Trioxide Aggregate (MTA) is a bioactive material widely used in endodontics. This case report shows the performance of MTA as a sealing material in a coronal third root perforation case.

Case Presentation

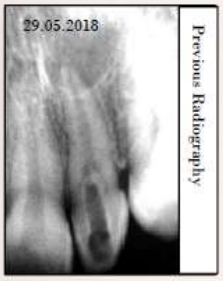

A 14-year-old female patient referred by general dentist for evaluation of left lateral incisor (Dens In Dente) with associated percussion pain and vestibular sinus tract. CBCT revealed an image of coronal third root perforation associated to an extensive periapical bone defect and internal apical root resorption . No canal access was performed.

Methodology

Perforation was chemomechanically debrided with stainless steel K-file #80 and 2.5% sodium hyploclorite (NaOCl). One session of Calcium Hydroxide medication was carried out and final irrigation protocol with 2.5% NaOCl, 17% E.D.T.A. and saline solution. Internal matrix technique was used. Perforation was sealed with MTA and the next appointment; once MTA was set, the intracanal portion of the root was restored with composite resin. Conventional endodontic treatment was performed once root canal access was achieved under loupe magnification. 3 and 8 months clinical and radiographic follow ups show signs and symptoms of healing.

Discussion

Perforations that are accessible through crown should be sealed with a biocompatible material, preferably MTA or bioceramics. In case of large perforations the use of an internal matrix is recommended to avoid material extrusion that could cause postoperative inflammation.

Conclusion & Clinical Relevance

MTA shows satisfactory clinical outcome when used as a sealing material in a coronal third root perforation case.

Kim S, Kraschman S. Microsurgery in Endodontics, first edition. Philadephia: Wiley Blackwell: 2018: 92.
Kutler S, Bogen G. Mineral Trioxide Aggregate Obturation: A Review and Case Series. J Endod 2009;35:777-90.

Management of a radicular perforation concomitant to an external root resorption by an impacted canine: a case report.

Ferraro Nicolás(*), Poli Francesca. (Universidad del Desarrollo)

Aim:

Evaluate through CBCT and radiographs, the evolution and repair of the periodontium after root perforation sealed with Biodentine, in a tooth with external root resorption.

Introduction (1,2):

External root resorption is a pathological process that has differents etiologies. The treatment consists in removing the stimulation factors of the resorption. The endodontic treatment is evaluated according to the compromised pulp.

Case Presentation:

13-year-old female patient ASA I, referred by her orthodontist for an endodontic retreatment on tooth No 22. Diagnosis: Previously treated tooth with symptomatic apical periodontitis + perforation in the affected area by an external resorption, consequence of an impacted canine. The canine was orthodontically distalized, and then, the root canal was endodontically treated without success (Image 4). It´s important to establish that the preforation was a result of an impacted canine (image 3).
Our therapeutic decision was endodontic retreatment and sealing the perforation using Biodentine.
Guttapercha was removed using ultrasonic tips and the root canal was shaped using WaveOne Gold system.
Biodentine was then applied on the perforation zone, and the apical portion of the root canal was obturated with bioceramic sealer using single cone technique (image 5,6). The rest of the root canal was sealed with injection (image 7). The tooth was restored with resin and the patient was controlled clinically and radiographically at 7 and 12 (image 7, 8).

Discussion:

External root resorption is a pathological process that has different etiologies(2). In this case, the impacted canine produced a root resorption with perforation, visible in CBCT (image 3). The first attempt of endodontic treatment without magnification resulted in a perforation so the patient was referred to a specialist that works under microscope. The factors in the decision to retreat were the access to the perforation zone and the age of the patient.
Biodentine, was the material selected to seal. This is a new material based on tricalcium silicates (3). As it is bioactive, it was used because it promotes cellular induction in root perforations and also for its excellent biocompatibility (4). In addition, it does not produce changes in color like other materials (e.g. MTA) and its manipulation is easy. (4)

Conclusions:

- Correct diagnosis and clinical management using the microscope, is very important in cases of external root resorptions induced by included teeth.
- When a perforation is produced in the root surface, the endodontic treatment is indicated.
- Biodentine proves to be a suitable material for sealing perforations and has the capacity to stimulate cells to induce the formation of periodontal ligament and alveolar bone around promoting a healthy bone and improving the prognosis of the damaged tooth.

Image 1. Impacted canine

Image 2. Canine distalization

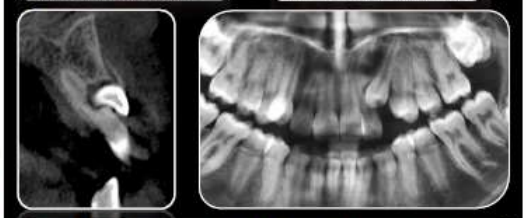

Image .3 CBCT and panoramic x- ray, impacted canine pushing lateral incisor

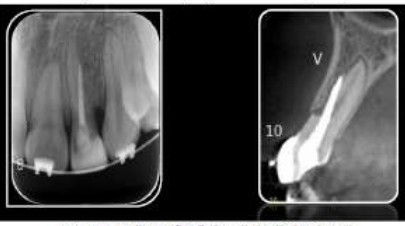

Image 4. Tooth 22 after first endodontic treatment

Image 5. Tooth 22. Preop. Perforation

Image 6. Canal obturation and biodentine

Image 7. X-ray Control after retreatment

Image 8. CBCT 1 year control

References

1. Heithersay, Geoffrey S. (2004) Invasive cervical resorption. Endodontic Topics. 7, 73-92.
2. Fuss Z,Tsesis I, Lin S. (2003) Root Resorption diagnosis, classification and treatment choices based on stimulation factors. Dental Traumatology. 19. 175-182
3. Leila Eftekhar, Hengameh Ashraf, Sanaa Jabbari. (2017). Management of Invasive Cervical Root Resorption in a Mandibular Canine Using Biodentine as a Restorative Material: A Case Report. Iranian Endodontic Journal. 12 (3): 386-389.
4. Özlem Malkondu, Meriç Karapinar Kazandal., and Ender Kazazoglu. (2014). Hindawi Publishing Corporation BioMed Research International

SAPIENZA
UNIVERSITÀ DI ROMA

ESE 2018 VIENNA 12-14 SEPTEMBER

RECOMMENDATIONS FOR USING REGENERATIVE ENDODONTIC THERAPY (RET) IN MATURE VS IMMATURE TEETH.

Mohamed Sami Shibani , Mohamed Mashyakhy ,Maurizio bossu, Antonella Polimeni, Gianluca Gambarini.
University of Rome (sapienza)

Aim : 1.To suggest the use of regenerative Endodontic therapy on Mature permanent teeth.
2. To illustrate the need for a new and modified Guidelines.

Background: Regenerative Endodontic Therapy (RET) is a recognized (AAE Validated) treatment for immature Permanent teeth with necrotic pulps and /or apical periodontitis .

Recently, Saoud et Proposed that RET Could be used to treat Mature Permanent Teeth with closed Apex but no Guidelines Are available .

American Association of Endodontics guidelines:
First visit: Proper access cavity - Debridement and placement of Antibacterial medication: Triple Antibiotic paste (Ciprofloxacin: Metronidazole: minocycline) or Ca(oh)2.
Second visit: Induce bleeding (blood clot or platelet-rich plasma) MTA + Permanent seal .

AAE Immature permanent teeth
Considerations :

1. Young patient (6-18).
2. Necrotic pulp and immature apex.
3. Minimal or no instrumentation of The dentinal walls.
4. Placement of an intracanal Medicament .
5. Creation of a blood clot or scaffold in canal.
6. Effective coronal seal .

Mature permanent teeth
Considerations :

1. No age limit.
2. It could be on mature.
3. Normal instrumentation.
4. Placement of an intracanal medicament.
5. Different procedures to gain blood Clot in closed apex.
6. Effective coronal seal.

AAE Fellow up

1. No pain, soft tissue swelling or sinus tract (often observed between first and second appointments).
2. Resolution of apical radiolucency.
3. Increased width of root walls.
4. Increased root length.
5. Positive Pulp vitality test response.

The proposed fellow up

1. No pain, soft tissue swelling or sinus tract (oftenobserved between first and second appointments).
2. Positive Pulp vitality test response.

AAE Sucecess

1. The elimination of symptoms and the evidence of bony healing.
2. Increased root wall thickness and/or Increased root length. (desirable, but perhaps not essential).
3. Positive response to vitality testing (which if Achieved, could indicate a more organized vital Pulp tissue) .

The Proposed success:

1. The elimination of symptoms and the evidence of bony healing.
2. Increased root wall thickness and/or increased root length . In mature teeth the root is already developed.
3. Positive response to vitality testing (which if achieved, could Indicate a more organized vital pulp tissue)

Conclusion

RET is a biologically based therapy that Have the potential to be used as an Alternative treatment for mature Permanent teeth. Therefore a specific Guidelines are needed.

References:

1. AAE american association of endodontics 2013.
2. Treatment of Mature Permanent Teeth with Necrotic Pulps and Apical Periodontitis Using Regenerative Endodontic Procedures: A Case Series M. Chen, and Louis M. Lin, (J. Endod 2015).
3. Treatment of a Large Cystlike Inflammatory Periapical Lesion Associated with Mature Necrotic Teeth Using Regenerative Endodontic Therapy. Saoud, , and Domenico Ricucci, (J Endod 2014;40:2086).

MANAGEMENT OF PARTIAL FAILURE REVASCULARIZATION TREATMENT

S.DHOUM[1], S. DROURI[1], S. NADIFI[2], I.BENKIRAN[1], S.DHAIMY[1].

[1]Department of conservative dentistry and endodontics, Hassan II University, faculty of dentistry of Casablanca, Morocco.
[2]Genetics Laboratory, Faculty of Medicine and Pharmacy, Hassan II University of Casablanca, Casablanca, Morocco

AIM To present a case of management of an open apex on a lower molar by using tissue engineering, with two endodontic procedures in the same tooth.

INTRODUCTION We had to resort to pulp regeneration on the distal root and apexification with MTA on the mesial roots after the failure of regenerative therapy on those ones. The management consisted in scheduling regular follow-ups combined with x-rays. After 24 months, the radiological control has shown pulpo-periodontal regeneration associated with walls thickening and distal root elongation and periapical ad integrum healing.

CASE PRESENTATION

An eighteen-year-old patient showed up in consultation with a tumefaction at the lower right cheek.
Clinical examination showed a buccal filling at the right mandibular molar area and a temporary restoration on #47; vitality tests were all negative Diagnosis of chronic apical periodontitis was made. (Fig 1)
It has been decided, with the patient's consent, to use regenerative procedure of the pulp.
The followed protocol was the one established by the American Association of Endodontics

TREATMENT :

First appointment

A slight mechanical preparation was performed to clean the root canal using H files assisted by irrigation with 1% sodium hypochlorite, using an endodontic needle introduced at WL-1 mm, followed by ultrasonic activation to improve the debridement of the root canal. Preparation of the antibiotic paste: 1.5 MIU spiramycin pill and 250 mg metronidazole were ground and mixed with distilled water (Fig 2).the antibacterial medication is placed in the canals to the apex using a mouth spatula and lentulo.

Second appointment

(after 3 weeks) initiation of the bleeding by a controlled instrumental overtaking at the apical zone.
capping of the blood clot with MTA (Fig 3).
protection of the MTA with glass ionomer cement as an intermediate base for subsequent final restoration with composite.(Vii)an antibiotic prescription: 3 MIU spiramycin + 500 mg metronidazole for 7 days and a paracetamol-based painkiller 1500 MG/day for 3 days.

FOLLOW UP

Control radiographs were performed after 3 months and 10 months at the mesial roots. After 10 months' recall (Fig 4), the radiograph has shown a failure of the revascularization therapy, a larger radiolucent image than the initial one, and a sign of recurrent periapical infection.
After conducting a mini access cavity, we have reached the MTA layer; with the assistance of ultrasonic inserts, the MTA in the cervical mesial zone was selectively removed to access the mesial canals. Both of the mesial canals were prepared by the coronoapical technique using protaper® endodontic system and stainless steel hand k-files. The apical third was sealed using MTA and then the coronal two-thirds with warm gutta-percha. (Fig 5)
After the second procedure, the two-month recall showed a reorganization of the periodontal space of the mesial apex and important thickening of the distal root with a visible root edification and a thickening of the dentinal walls

the 24-month recall (Fig 6) showed ad integrum periodontal regeneration at the apical area of the mesial roots, following the apexification procedure with MTA, and at the distal apical area with restructuring of the apical dome and thickening of the apical constriction, following

Figure 1: Initial radiography tooth 47 with radiolucent images at the mesial and distal roots.

Figure 2: Endodontic filling with the antibacterial medication.

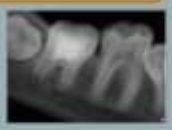

Figure 3: Control radiograph after capping with MTA.



Figure 4: Radiograph after 10 months' recall: enlargement of the radiolucent image at the mesial roots.

Figure 5: Filling of the mesial roots with MTA.

Figure 6: Radiograph at 24 months' recall: complete disappearance of the radiolucent images.

DISCUSSION

A range of clinical protocols have been described, with various irrigants, intracanal medication, clinical procedures, and follow-up times [1]. Criteria for predictable revascularization are still lacking. We have chosen in this clinical case to follow the protocol described by the AAE [2].
It is difficult to select the appropriate nonvital teeth with residual vital apical cells, which are believed to be necessary for a successful regenerative procedure.
Nowadays, two types of tissue engineering are developed from the pulp. The existence of pluripotent stem cells makes the tooth an interesting element with easy access to collect stem cells and it is considered in autologous therapies [3–4].
(2) Other applications include root canal revascularization, pulp implants, injections of hydrocolloids biogels in the root canal seeded with cells, or gene therapy in order to develop new endodontic therapies supplanting the conventional pulpectomy and canal obturation. [5].
The pulp capping and the regenerative procedure are used clinically, the other procedures must be verified and their interest confirmed regarding the existing techniques before including them in our therapeutic arsenal [3-5].

REFERENCES

1. E. G. Kontakiotis, C. G. Filippatos, G. N. Tzanetakis, and A. Agrafioti, "Regenerative endodontic therapy: a data analysis of clinical protocols," Journal of Endodontics, vol. 41, no. 2, pp. 146–154, 2015.
2. AAE Clinical Considerations for a Regenerative Procedure. Revised 6-8-16
3. R. Zizka, T. Buchta, I. Voborna, L. Harvan, and J. Sedy, "Root maturation in teeth treated by unsuccessful revitalization: 2 case reports," Journal of Endodontics, vol. 42, no. 5, pp. 724–729, 2016.
4. S. Lymperi, V. Taraslia, I. N. Tsikopoulos et al., "Dental stem cell migration on pulp capping cavities filled with MTA, dentin chips, or bio-oss," BioMed Research International, vol. 2013, Article ID: 189872, 2013.
5. J. Latham, H. Fong, A. Jewett, J. D. Johnson, and A. Paranjpe, "Disinfection efficacy of current regenerative endodontic protocols in simulated necrotic immature permanent teeth," Journal of Endodontics, vol. 42, no. 8, pp. 1218–1225, 2016.

PULPOTOMY AS A SAVING THERAPY FOR CARIOUS EXPOSED MOLARS IN A LOW-INCOME POPULATION: CASE SERIES

Albuquerque, MTP *[1]; Nagata, JY[2]

[1]Federal University of Bahia – School of Dentistry – Salvador, Brazil
[2]Federal University of Sergipe – Lagarto, Brazil

AIM

To report four cases of pulpotomy performed with mineral trioxide aggregate (MTA) in molars diagnosed with symptomatic irreversible pulpitis, associated or not to apical periodontitis.

INTRODUCTION

Conventional root canal therapy (RCT) has been associated to dental structure loss (13.7%), favoring future root fractures[1]. In this context, recent regenerative and vital pulp therapies have demonstrated high success rates for pulpotomy in permanent teeth diagnosed with irreversible pulpitis, allowing to conserve tooth structure[2-4]. Additionally, few professionals consider themselves capable to perform endodontic treatment in permanent molars of children in Brazil, and also most of the population have limited access to oral services.

CASE PRESENTATION

Four lower permanent molars with extensive carious lesion exhibiting signs and symptoms of irreversible pulpitis were treated with MTA (Angelus, Brazil) pulpotomy. All teeth were anesthetized, isolated with rubber dam, carious lesions were removed, and teeth were disinfected with 2.5% sodium hypochlorite (NaOCl). The access to the pulp chamber was performed and favorable macroscopic pulp tissue conditions were analyzed to proceed the pulpotomy. Coronal pulp tissue was removed with sterile hand excavators and hemostasis was achieved with 2.5% NaOCl, enabling the MTA placement over the remaining root pulp tissue. All teeth were temporary restored with glass-ionomer cement and after a month they were restored with composite resin. The patients have been followed-up for 6 months demonstrating no clinical symptoms or radiograph radiolucency.

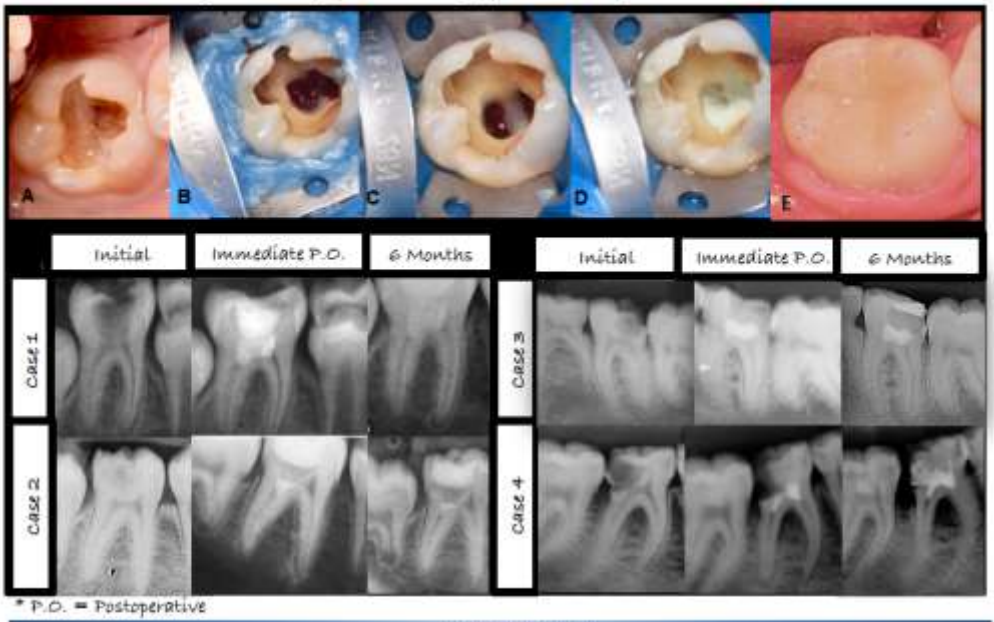

* P.O. = Postoperative

DISCUSSION

The irreversible pulpitis diagnosis is usually established from the clinical pain reported by the patient, however, the clinical diagnosis not always correspond to the pulp tissues histological condition[5]. Therefore, two parameters are considered essential to achieve a better prognosis for vital pulp therapies (e.g. pulpotomy): a favorable clinical macroscopic conditions and the time of pulp hemostasis[2-4]. Accordingly, pulpotomy in permanent molars diagnosed with irreversible pulpitis have been treated with different bioceramic materials presenting high success rates (74-100%)[2-4]. Similar findings were observed in the present cases using MTA in short-term follow-ups.

CONCLUSION & CLINICAL RELEVANCE

Symptomatic permanent molars of young patients may be treated with MTA pulpotomy as an alternative management to RCT and extraction, mainly in infant patients, with difficult behavior. In addition, it is a low-cost, technically simple procedure that may be performed in a low-income population, saving teeth and even preventing tooth weakening.

REFERENCES

1. Ikram OH, Patel S, Sauro S, Mannocci F. Micro-computed tomography of tooth tissue volume changes following endodontic procedures and post space preparation. Int Endod J. 2009 Dec; 42(12):1071-6.
2. Linsuwanont P, Wimonsutthikul K, Pothisiroke U, Santiwong B. Treatment Outcomes of Mineral Trioxide Aggregate Pulpotomy in Vital Permanent Teeth with Carious Pulp Exposure: The Retrospective Study. J Endod. 2017; 43(2):225-230.
3. Taha MA, Abdulkhader SZ. Full Pulpotomy with Biodentine in Symptomatic Young Permanent Teeth with Carious Exposure. J Endod 2018 Jun;44(6):992-997.
4. Taha NA, Ahmad MB, Ghanim A. Assessment of mineral trioxide aggregate pulpotomy in mature permanent teeth with carious exposures. Int Endod J. 2017; 50:117-125.
5. Ricucci D, Loghin S, Siqueira JF. Correlation between Clinical and Histologic Pulp Diagnoses. J Endod. 2014; 40(12):1932-9.

Endodontic Regeneration of traumatized Upper Central Incisor: Case Report

Junedakthar S. Shaikh, Pedro Cruz, Antonio Ginjeira

Dept. of Endodontics, Faculty of Dental Medicine, University of Lisbon

Aim:

The aim of this case report is to present Endodontic Regeneration procedure for treatment of Traumatic Immature Necrotised Permanent teeth.

Introduction:

- Regenerative endodontics is defined as 'biologically based procedures designed to replace damaged tooth structures, including dentine and root structures, as well as cells of the pulp–dentine complex'.
- Regenerative Endodontic Therapy (RET) is aimed to regenerate the pulp–dentine complex damaged by infection, trauma or developmental anomaly of immature permanent teeth with necrotic pulp.

Case Presentation

Case 1:

- A 8yrs old Girl had traumatic avulsion with teeth 11 and was re-implanted within 3hrs (stored in milk medium) after cleaning with saline. Flexible splint given and recalled. At later visit, Pulp was diagnosed as Necrotic and Planned for Regenerative Endodontic Treatment.

Preop 2013 | I.Postop 2013 | Postop 2014

Postop 2016 | Postop 2018 | Postop 2018

Case 2:

- A 9yrs old Girl had trauma without displacement of teeth 21. Complains of pain. Pulp tests were negative at first visit. Pulp diagnosed Necrotic and Planned for Regenerative Endodontic Treatment.

Preop 2010 | Postop 2010 | Postop 2011 | Postop 2019

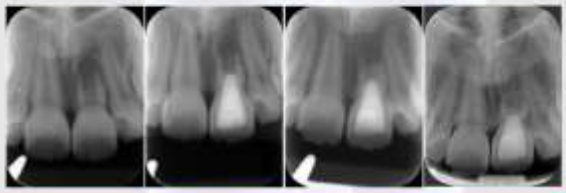

Clinical Procedures:

Both cases presented with complain of pain. After proper diagnosis, treatment planning and getting proper consent from Parents. Treatment initiated under proper Anaesthesia and Rubber Dam isolation. Canal debridement with hand files. Canals flushed with 5.25% NaOCL and 17% EDTA and closed with Calcium Hydroxide as intracanal medicament in both cases. Further visit after 1month, teeth's asymptomatic, Anaesthesia performed with Mepivacaine, and after irrigation with 17% EDTA, bleeding was evoked with hand k files. Blood was allowed to clot and MTA placed over it. Restored and recalled for follow-up. Cases were followed with clinical and radiographic evaluation of signs and symptoms and radiographic outcomes.

Discussion:

Immature teeth with Necrotic Pulp in Younger patients have higher regenerative potential. NaOCl irrigation and $Ca(OH)_2$ intracanal medication has been able to achieve disinfection of canals. EDTA helps in release of growth factors and promoting dental pulp stem cells. The procedure seems to provide an environment for tooth root to develop with the surrounding tissues and maintain the tooth in function.

Conclusion and Clinical Relevance :

RET is able to achieve its Primary goal of Eliminating patients clinical symptoms and resolving the Apical Periodontitis and Secondary goal of root development. RET shows the potential of root thickening and may assist in future retaining of the tooth and keeping it functional.

References:

1. Francisco Banchs, Revascularization of Immature Permanent Teeth With Apical Periodontitis: New Treatment Protocol (J Endod Vol. 30, No. 4, April 2004)
2. Kenneth M. Hargreaves, Regeneration Potential of the Young Permanent Tooth: What Does the Future Hold?, (J Endod 2008;34: S51-S56)
3. AAE Guidelines, The Treatment of Traumatic Dental Injuries; (2013)
4. B. G. Kim; Regenerative endodontics: a comprehensive review; (IEJ, 51, 1367–1388, 2018).

Clinical management of *dens invaginatus* with immature apex and periapical lesion, by means of a regenerative endodontic procedure.

Martinez-Olivas Denisse, Padilla-Sánchez Karen A., Uribe-Campero Mario, Cruz-González Alvaro.

Endodontic Postgraduate Program. Universidad de Guadalajara, CUCS, México.

AIM:

To describe the clinical management of dens invaginatus Oehler's class II with immature apex and root development group III (Cveck 1992) with periapical lesion corresponding to score 5 in the periapical index (PAI), score D in CBCTPAI [4] using an endodontic regeneration procedure and the evaluation of intra-canal mineralized tissue formation by means of CBCT.

INTRODUCTION:

Regenerative endodontic treatment in teeth with incomplete root formation and necrotic pulp, allows the formation of connective tissue within the root canal that can increase the size in the root length, as well as the thickness and strength of the dentinal walls. [1,2,4]

CASE PRESENTATION:

A 13-year-old female patient attended for evaluation and treatment of a swelling response that manifested and subsided in the left maxilla with no history of trauma.

At the clinical examination, the left maxillary lateral incisor (LMLI) presented a cingulum with caries in the fissure. The dental pulp test responded negative; on palpation, percussion and periodontal probing was within normal limits and without mobility. In 2D imaging the LMLI was observed with immature apex, and invaginated tooth Oehler's class II with thin dentinal walls and radiolucency exceeding the radiographic limits.

In the cone beam computed tomography (CBCT) we observed that the LMLI had stopped its development, with a radiolucent area of diameters greater than 12.8 mm by 11.9 mm (IMG 1c-f).

It also showed that the contralateral tooth presented mature apex with no presence of dens invaginatus, as well as no signs or symptoms of pulp disease.

CLINICAL DIAGNOSIS: Necrotic pulp and asymptomatic apical periodontitis. Regenerative endodontic treatment was elected and it was performed in two visits with calcium hydroxide as interim medication.

IMG 1

FIRST APPOINTMENT:

Patient was anesthetized and conventional access was performed under absolute isolation (IMG 2a-c).

Working length was taken with #80 K-type file (IMG 2d-e), debriding without widening the canal and irrigated with 2.5% NaOCl (20ml/5min) and PUI for 1 minute (IMG 2f), then with saline solution (20ml/5min). It was dried with paper points (Coarse Pearson).

With #40 lentulo $Ca(OH)_2$ was placed in aquerous paste, as an intra-canal dressing and the cavity was sealed with glass ionomer (Ketac Cem).

IMG 2

SECOND APPOINTMENT:

The patient didn't attend to her appointment. Six months later she returned without either inflammation or symptomatology during the elapsed time. Anesthetic was infiltrated without vasoconstrictor, removed intra-canal dressing and irrigated with EDTA 17%/20ml. It was dried with paper points and bleeding was caused by over-instrumentation with a #80 K-file (IMG 3a). The bleeding was controlled up to 2mm below the cement-enamel junction. (IMG 3b). We waited for 15 minutes to obtain the formation of a clot, on which a Colla-Cote membrane containment was placed (IMG 3c) and sealed with Biodentine (IMG 3d).

IMG 3

FOLLOW UP:

- One month after the revitalization the patient was asymptomatic. Tooth was coronally restored with resin (IMG 3f-h).
- After six months of the revitalization, 2D imaging showed apical barrier formation with an increase in the thickness of dentinal walls, periodontal ligament and trabecular bone were neoformed.
- At the 9th month in the CBCT (IMG 4b-e), the formation of mineralized tissue within the root canal can be observed, as well as the formation of the apical barrier and the reduction of the lesion.

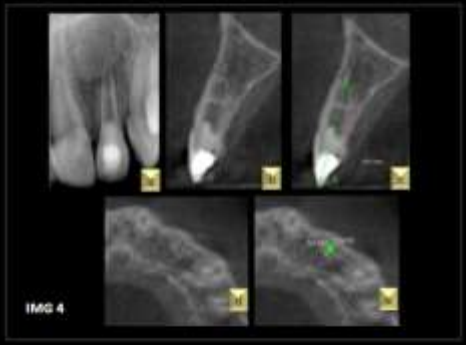

IMG 4

DISCUSSION:

The clinical management of teeth with an immature apex through conventional endodontic treatment decreases the bacterial load, which allows the beginning of periapical healing[3].

Regenerative endodontic procedures are highly successful, they have shown increase in root length and in root width, which is very significant comparing to apexification procedures. One of the most relevant facts is that it is a non-surgical treatment and it gives teeth the chance to regain their vitality, sensibility and improve their function. These advantages are unparalleled with any other endodontic treatment.

CONCLUSION:

The regenerative endodontic procedure allows the formation of invaginated tissue from periapical tissues which, even in the case of persistent apical periodontitis, has stem cells[5].

This procedure is a viable alternative treatment when adequate case selection and management is suitable.

REFERENCES:

1. Banchs F, Trope M. Revascularization of immature permanent teeth with apical periodontitis: new treatment protocol? J Endod. 2004; 30(4):196-200.
2. Thibodeau B, Teixeira F, Yamauchi M, Caplan DJ, Trope M. Pulp revascularization of immature dog teeth with apical periodontitis. J Endod. 2007;33(6):680-9.
3. Lenzi R, Trope M. Revitalization procedures in two traumatized incisors with different biological outcomes. J Endod. 2012; 38(3):411-4.
4. Estrela C, Bueno M, Azevedo B, Azevedo J, Pécora J. A new periapical index based on cone beam computed tomography. J Endod. 2008;34(11):1325-1331
5. Estrela C, Freitas Silva BS, Silva JA, Yamamoto-Silva FP, Pinto-Junior DD, Gomes BS. Stem cell marker expression in persistent periodontitis. J Endod 2017; 43(1): 63-6

CLINICAL MANAGEMENT OF DENS EVAGINATUS BY MEANS OF REVITALIZATION

Amezcua Octavio, Ramírez Héctor, Castellanos Fernanda, Gascon Gerardo
University of Guadalajara, CUCS, Endodontics Specialty Program.

Aim: To describe the clinical management of a lower bicuspid presenting dens evaginatus by means of revitalization.

Introduction

Dens evaginatus is a tooth development anomaly that results in the formation of an accesory cusp, whose morphology has been described as an abnormal tubercle, elevation or protuberance[1]. It contains a pulp tissue prolongation covered by a thin layer of dentin and enamel, as a fine pulp horn[2].

The procedures of endodontic regeneration in necrotic teeth with immature apex have as objective the regeneration of a tissue similar to the pulp inside the root canal, after inducing the entry of stem cells from the apical papilla[3,4].

Case Presentation

A 12 year old female patient attended the endodontics clinic presenting edema and sinuous tract on the lower right bicuspid area (Img. 1). The second bicuspid presented a dens evaginatus and immature apex in both second lower bicuspids (Img. 2,3). Vitality pulp tests were negative and no caries, restorations, probing or movility were detected. The **diagnosis** was pulp necrosis and cronic alveolar abscess.

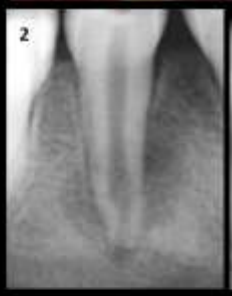

Methodology

After anesthesia, isolation and access, the canal was debrided with gentle filing with a #80 K file (Img. 4). Copious irrigation with 2.5% NaOCl, followed by smear layer removal with REDTA were used. An aqueous calcium hydroxide paste was applied.

The patient returned asymptomatic. After isolation and anesthesia the $Ca(OH)_2$ was removed with NaOCl irrigation and gentle filing. Smear layer was removed with 20ml. 17% EDTA, and a final 5mL. sterile saline rinse. Bleeding was caused by over-filing with a pre-bent 30 K file. Hemostasis was achieved placing a Gelatamp foam 2mm bellow the amelocementary level. White MTA was placed at cervical third level. A Vitremer base and a composite were used as coronal sealing (Img. 5).

At 6 moths recall, the patient was asymptomatic and a dentinal walls increasing in thickness and length (Img. 6).

12 months follow up, the vitality pulp test was positive as well as complete radicular formation (Img. 7).

At 18 months recall the patient remained asymptomatic, and the root walls continued to increase its thickness (Img. 8).

Discussion

Revitalization procedures have shown to be successful, comparing to apexification procedures, because there is an increase in root length width, which is very significant. one of the most relevant facts is that it is a non-surgical procedure and it gives teeth the chance to regain their vitality, sensibility and improve their function. These advantages are unparalleled with any other endodontic treatment.

Conclusions

- ✓ Early diagnosis of dens evaginatus is important because they can treated conservatively.
- ✓ In cases presenting pulp necrosis and immature apex, the revitalization is a good treatment modality since it provides the conditions to continue the increasing in length and thickness of the dentinal walls.

References

1. Ahmed H, Dummer P (2018) A new system for classifying tooth, root and canal anomalies. *International Endodontic Journal* **51**, 389-404.
2. Levitan M, Himel V. (2006) Dens evaginatus: literature review, pathophysiology and comprehensive treatment regimen. *Journal of Endodontics* **32**, 1-9.
3. Galler K, Krastl G, Simon S, Van Gorp G, Meschi N, Vahedi B, Lambrechts P (2016) European Society of Endodontology position statement: Revitalization procedures. *International Endodontic Journal* 49, 717-23.
4. Bezgin T, Sönmez H (2015) Review of current concepts of revascularization/revitalization. *Dental Traumatology* **31**, 267-73.
5. Orstavik D, Kerekes K, Eriksen H (1986) The periapical index: A scoring system for radiographic assessment of apical periodontitis. *Dental Traumatology* **2**, 20-34.

Simplified Approach for obturation of non-divergent Open Apex with Gutta Percha & Bioceramic Sealer

Avi Hadad, Hadas Azizi, Joe Ben Itzhak, Michael Solomonov
Department of Endodontics, Israel Defense Forces (IDF) Medical Corps, Tel Hashomer, Israel

Aim

To offer a reliable and simple approach for obturation of pulpless teeth with non-divergent open apex (#80 or more).

Introduction

The treatment options for pulpless teeth with open apex include: classic apexification, one visit MTA plug, and revascularization. Those treatment options need special expensive equipment such as dental operating microscope and MTA carrier, as well as high level of operation endodontic skills. Yet, general practitioners worldwide seek to provide a quality treatment in these cases. We tried to develop a new simplified approach, based on the bioceramic sealer. The major advantage of this sealer, compared to traditional sealers, is it's biocompatibility, which might play an important role in open apex cases.

The method

After a proper chemo-mechanical preparation, the canal is dried, and a gutta percha (GP) master cone is selected. The operator must opt the largest cone or customized cone that stops 1 mm short of the WL (*If a stop isn't achieved, another treatment option needs to be selected*).

The cone is coated with bioceramic sealer and inserted to the canal, 1 mm short of the WL. Accessory GP cones, coated with bioceramic sealer may be added in passive manner without spreader. Heat is then applied with a warm plugger to cut the excess GP, and the GP is compact lightly with a Plugger.

Case 1

Pre-Treatment Rx | Master GP Cone Rx | Post-Treatment Rx | 6 month follow-up Rx

Case 2

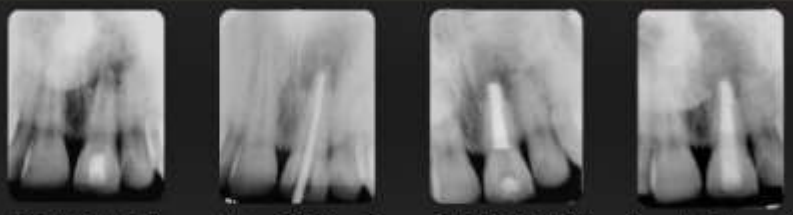

Pre-Treatment Rx | Master GP Cone Rx | Post-Treatment Rx | 6 month follow-up Rx

Guided endodontic treatment of multiple teeth with dentin dysplasia: a case report

Universitätsklinikum Würzburg

Krug R[1], Volland J[1], Reich S[1], Soliman S[1], Connert T[2], Krastl G[1]

[1] Department of Operative Dentistry and Periodontology, University Hospital Würzburg, University of Würzburg, Germany

[2] Department of Periodontology, Endodontology and Cariology, University Centre for Dental Medicine, University of Basel, Switzerland

Aim: To report a minimally invasive approach for root canal localization and treatment in a dentin dysplasia patient with pulp canal obliteration and apical periodontitis using a 3D printed template designed by merging cone-beam computed tomography (CBCT) and surface scan data

Case Report: A 14-year old female with radicular dentin dysplasia type I (DD-1), a rare autosomal dominant disorder of dentin formation caused by a dentin sialoprotein coding malfunction, presented for endodontic treatment of seven teeth with apical periodontitis. DD-1 is characterized by teeth with normal enamel but aberrant dentin formation and abnormal pulp morphology. Radiographically, the pulp spaces may be reduced or completely obliterated. Clinically, the patient exhibited acute pain on percussion of tooth 36 and was diagnosed with symptomatic apical periodontitis.

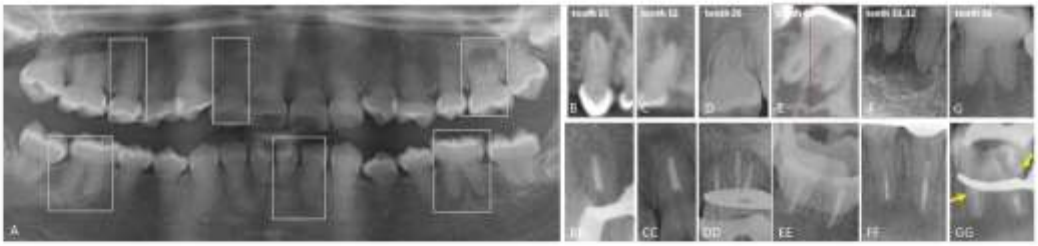

Radiography revealed pulp canal obliteration (PCO) in all teeth showed and apical radiolucency in seven teeth: # 15, 12, 26, 36, 32, 31 and 46 (Fig. A-G). Because of the acute symptoms, #36 was treated first by conventional access preparation and root canal detection. Despite meticulous technique, perforations of the distal and mesiolingual canals occurred and were immediately repaired with mineral trioxide aggregate (ProRoot® MTA, Dentsply Sirona) (Fig. GG, yellow arrows). Consequently, we switched to guided endodontic treatment for the remaining six teeth. CBCT and intraoral surface scans were acquired and matched using virtual endodontic access planning software (coDiagnostiX®, Dental Wings GmbH; see the clinical video: „Guided endodontics: Virtual endodontic access planning using two different workflows"). After the drill position for root canal location was determined (Fig. H, I), a virtual template was designed (Fig. J). The corresponding STL data file was exported to a 3D printer for template fabrication. The template was positioned on the teeth requiring endodontic treatment (Fig. K). A specific drill was used to penetrate the obliterated part of the root canal and obtain minimally invasive access to the apical region (Fig. L, N). All root canals were rapidly and successfully localized. Endodontic therapy consisted of mechanical preparation using nickel-titanium rotary files (Mtwo®, VDW GmbH), sonic-powered irrigant activation with sodium hypochlorite (3%), and vertical warm vertical gutta-percha obturation with AH Plus® (Dentsply Sirona). Down-pack obturation was performed as shown in Figures BB-GG. Access cavities were then restored with composite fillings (Fig. O, P).

Discussion: Unlike conventional endodontics, which resulted in dual perforation of tooth #36, guided endodontics (GE) achieved safe root canal localization in all teeth (#15, 12, 26, 32, 31, and 46) without complications. *Ex-vivo* study results are promising, showing that GE is a highly precise and time-saving technique of root canal localization.[1-3] After merging pre- and postoperative CBCT scans, the investigators found that angle deviation between the virtual planning axis and the actual axis of root canal access was a mean of 1.8 degrees, and that the mean deviation from the virtual target endpoint (irrespective of operator) was 0.2 - 0.5 mm in different axes. The mean treatment time for GE (sum of all steps including planning and preparation) was ≤ 10 minutes per tooth.[4] Connert and colleagues compared tooth substance loss in 3D printed teeth with PCO treated by microguided versus conventional endodontics (dental microscope) and found that microguided endodontics located significantly more root canals with less substance loss.[5] Other investigators report that this approach is clinically useful for facilitating the root canal treatment of anterior and posterior teeth with PCO and apical periodontitis.[4,6]

Conclusion & Clinical Relevance: Guided endodontics is shown to be a safe and clinically feasible method to locate root canals and prevent root perforation in teeth with PCO and apical periodontitis. Generally, this technique is mainly used in teeth with post-traumatic PCO, but it may also have substantial clinical benefits for patients with tooth obliteration due to rare disorders of dentin development (e.g., dentin dysplasia) who are in need of endodontic treatment.

1. Buchgreitz J, Buchgreitz M, Mortensen D, Bjørndal L. Guided access cavity preparation using cone-beam computed tomography and optical surface scans - an ex vivo study. Int Endod J 2016;49:790-795
2. Zehnder MS, Connert T, Weiger R, Krastl G, Kühl S. Guided endodontics: Accuracy of a novel method for guided access cavity preparation and root canal location. Int Endod J 2016;49:966-972
3. Connert T, Zehnder MS, Weiger R, Kühl S, Krastl G. Microguided endodontics: Accuracy of a miniaturized technique for apically extended access cavity preparation in anterior teeth. J Endod 2017;43:787-790
4. Krastl G, Zehnder MS, Connert T, Weiger R, Kühl S. Guided endodontics: A novel treatment approach for teeth with pulp canal calcification and apical pathology. Dent Traumatol 2016;32:240-246
5. Connert T, Krug R, Eggmann F, Emsermann I, Elayouti A, Weiger R, Kühl S, Krastl G. Guided Endodontics vs. conventional access cavity preparation: a comparative study on substance loss using 3-D-printed teeth. J Endod 2019;45:327-331
6. Lara-Mendes STO, Barbosa CFM, Santa-Rosa CC, Machado VC. Guided endodontic access in maxillary molars using cone-beam computed tomography and computer-aided design/computer-aided manufacturing system: A case report. J Endod 2018;44:875-879

zahnerhaltung.uk-wuerzburg.de

SAPIENZA
UNIVERSITÀ DI ROMA

IMPROVED NAVIGATION SYSTEM FOR ENDODONTIC SURGERY

Antonio Morese[1], Marco Seracchiani[1], Luigi Vito Stefanelli[2], Francesca De Angelis[3], Stefano Di Carlo[3], Gianluca Gambarini[4].

1-Student, Sapienza University of Rome, Dept. of Oral&Maxillofacial Science
2-DDS, Sapienza University of Rome, Dept. of Oral&Maxillofacial Science
3-Associate Professor, DDS, PhD, Sapienza University of Rome, Dept. of Oral&Maxillofacial Science
4-Ordinary Professor, MD, PhD, Sapienza University of Rome, Dept. of Oral&Maxillofacial Science

AIM

to illustrate the use of an improved version of Navident (Claronav, Canada) navigation system for endodontic surgery.

INTRODUCTION

Static and dynamic navigation systems were introduced for facilitating insertion of dental implants. Dynamic systems utilize a CBCT scan, an optical device and a dedicated computer in order to precisely insert the implant with greater precision with an accurate, real-time three-dimensional control of burs insertion and progression. Such a system could be used for other surgical procedures, including access cavity and apicoectomy in endodontics, as shown in the present case report. For the endodontic use the software was specifically modified to utilize high-speed burs, Ni-Ti files, ultrasonic and piezo tips. Software has also been modified recently and to facilitate calibration (Trace and place), i and use with any CBCT. In surgical endodontics the aim is to prepare a minimally invasive access cavity which, however, should allow enough space to perform correct apicoectomy, retrograde filling and mechanical removal of the lesion. This microsurgical approach need .The present case report shows the use of the Navident system in cavity preparation and apicoectomy, aiming at providing an easier, more rapid, predictable and accurate technique for treating a lesion in an upper lateral incisor.

CASE REPORT

Male patient with symptomatic 1.2 due to the vertical percussion 3 Years after orthograde treatment. CBCT exam showed a periapical lesion. Patient refused orthograde retreat. Dynamic navigation was performed to minimize bone cavity design and a precise root resection (bevel); the rest of the procedure was performed with common micro-surgical techniques. The outcome was very successful, with negligible post-op discomfort, due to the minimally invasive approach and healing was progressing nicely at 6-m control.

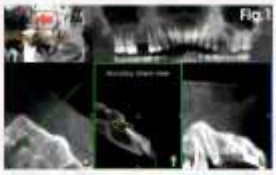

METHODOLOGY

I CBCT exam and planning (fig.1;)
II-III New Calibration system ; 3aP (trace&place) (fig2;fig.3)
IV Access through Navident (fig.4)
V Checking access on PC screen (fig.5)
VI removal of the lesion after apicoectomy (fig.6)
VII retrograde filling (fig.7)

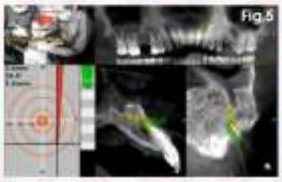

PERIAPICAL RX:

- CBCT view pre-op. (A);
- Periapical pre-op x-ray (B);
- Immediate post op x-ray (C);
- 6 month follow-up x-ray (D).

DISCUSSION

The Dynamic navigation system allowed precise localization of the root end and apicoectomy with a minimally invasive bone cavity, aiming at reducing trauma and post-op pain. Navident allowed to precisely direct the burs in 3 dimensions (easily checking I on the PC screen with the target or in different planes), reducing the risk of iatrogenic errors; this is important especially when lesions are very close to noble structures or for less-experienced operators, who can control in real time every step of the surgical procedure, and eventually correct mistakes . The treatment was performed by an undergraduate student in approx 30 minutes, thanks to the innovative navigation system and gave excellent results as shown in the radiographs. Post-op symptomps were negligible.

CONCLUSIONS

The dynamic navigation system allowed a non expert operator to precisely perform bone cavity access and root end resection during endodontic surgery. It offered many advantages, also in comparisons with static guides.

CLINICAL RELEVANCE

Dynamic navigation is a promising technology, which can be very helpful also in surgical endodontics.

REFERENCES

Mangano Stefanelli DeGroot Dynamic Navigation for Surgical Implant Placement: Overview of Technology, Key Concepts, and a Case Report/Dynamic Navigation for Surgical Implant Placement: Overview of Technology, Key Concepts, and a Case Report. Compend Contin Educ Dent. 2018 Oct;39(9):614-621; quiz 622.

SAPIENZA
UNIVERSITÀ DI ROMA

A LOW TORQUE, HIGH SPEED ROTARY INSTRUMENTATION TECHNIQUE WITH THERMALLY TREATED NI-TI FILES.

Lucila Piasecki[1], Marco Seracchiani[2], Antonio Morese[2], , Giovanni Schianchi[3], Luca Testarelli[4], Gianluca Gambarini[5].

1-Professor Division of Endodontics, University at Buffalo, Buffalo, NY, USA
2-Student, Sapienza University of Rome, Dept. of Oral&Maxillofacial Science
3-DDS, Sapienza University of Rome, Dept. of Oral&Maxillofacial Science
4-Professor, DDS, PhD Sapienza University of Rome, Dept. of Oral&Maxillofacial Science
5-Professor, MD, PhD, Sapienza University of Rome, Dept. of Oral&Maxillofacial Science

AIM

The aim of the present poster is to present and clinically evaluate a new operative technique for Nickel Titanium Rotary instruments.

INTRODUCTION

Low torque instrumentation has been proposed in the past to increase safety of root canal treatment (RCT). However in most of cases low torque limit did not allow instrument to progress easily and reach working length. The recent improvement in design, cutting efficiency and manufacturing (Heat treatment with softer alloys) could partially eliminate those previous limitations and allow instrumentation with torque values lower than 1 Ncm. Such a low operative torque, however, requires an increase of the operative speed up to 800 to ensure adequate progression of the files.

This poster aims at presenting and clinically evaluating using new endodontic rotary instruments EdgeFile X7 25.06 which proved to need lower operative torque compared to other Ni-Ti instruments in a recent study by the author. Instruments were used in 10 molar cases with an endodontic motor (Eightteeth, Changzhou City, China) and the following setting: 800 Rpm and 1 Ncm.

METHODOLOGY

1) Scouting and patency check with a k-10/8
2) EdgeFile X7 25.06 until the torque allowed inward motion of the instrument inside the root canal
3) EdgeFile X7 25.06 with outward motion
4) Repeating steps 4 and 5 until the working length was successfully reached

DISCUSSION

The proposed technique allowed instruments to reach working length with no deformation or fracture in all cases. According to the manufacture the innovative alloy (EdgeWire) significantly increased the resistant to flexural stress. The propose speed and torque setting helped reducing torsional stress.

Such a combination of instrument design and manufacturing and operative technique allowed a safer and efficient instrumentation of complex root canals.

Low torque values could reduce the risk of intracranal separations due to torsional stress; the increase of speed may slightly increase the risk of separation due to fatigue but the new alloy are much more resistant than traditional Ni-Ti and could easily compensate this risk.

The combination of inward and outward motion with the same instrument when progression is not easy helps to reduce coronal blade engagement and facilitated progression according to the crown down principles.

CLINICAL RELEVANCE

The proposed technique seems very promising, for the tested instruments, and it could be the same for other similar instruments, even if more test are needed to prove its efficacy and safety.

REFERENCES

Gambarini G, Seracchiani M, Piasecki L, Valenti Obino F, Galli M, Di Nardo D, Testarelli L. Measurement of torque generated during intracanal instrumentation in vivo. Int Endod J. 2018 Nov 16.

Kwak SW, Ha JH, Cheung GS, Kim HC, Kim SK. Effect of the Glide Path Establishment on the Torque Generation to the Files during Instrumentation: An in Vitro Measurement. J Endod. 2018 Mar.

/ PLATINUM SPONSOR

/ GOLD SPONSORS

/ SILVER SPONSORS

/ BRONZE SPONSORS

EXHIBITORS

/ Acadental, Inc.
/ Alltion (Wuzhou) Co., Ltd
/ American Dental Systems GmbH
/ Aquarius Health & Wellness
/ B&L Biotech, Inc.
/ Bio Composants Médicaux
/ CJ-Optik GmbH & Co. KG
/ COXO Medical Instrument Co., Ltd
/ DEMED Dental Medizin Technik
/ DHM-dental BV
/ DRSK Group AB
/ ENDOSTAR
/ Forumtec
/ FragRemover GbR
/ Global Surgical
/ Innovative material and devices, Inc
/ J. MORITA EUROPE GMBH
/ JADENT GmbH
/ Karl Kaps GmbH & Co. KG
/ Kohdent Roland Kohler Medizintechnik GmbH & Co. KG
/ Komet Dental Gebr. Brasseler GmbH & Co. KG
/ Laschal
/ MANI, INC.
/ Maruchi
/ Medcem GmbH
/ Medident Italia
/ Meta Biomed Europe GmbH
/ NEOLIX SAS
/ ORODEKA SRL
/ P.P.H. CERKAMED WOJCIECH PAWŁOWSKI
/ Produits Dentaires SA
/ Quality Endodontic Distributors Limited (Q.E.D Ltd)
/ Quintessence Publishing Co. Ltd
/ S.C. Doctor Tools SRL
/ Sanctuary Health Sdn Bhd
/ Sendoline AB
/ SHENZHEN SUPERLINE TECHNOLOGY CO., LTD.
/ SHENZHEN PERFECT MEDICAL INSTRUMENTS CO., LTD
/ SICAT GmbH & Co. KG
/ SS White Dental
/ Stoma / Storz am Mark
/ Swiss Endo Academy
/ Tri Hawk S.A.
/ United Dental Changzhou
/ VELA-Medical
/ ZEISS
/ Zumax Medical Co,.Ltd.